

# ONE HUNDRED STAPEDECTOMIES IN RETROSPECT

J. M. MARQUARD, M.B., B.CH. (RAND), D.L.O., R.C.P. & S., *East London*

Modern methods of treating otosclerosis embrace several techniques, and include the partial or complete removal of the footplate, the crura, and the head and neck of the stapes. The oval window is covered with a tissue graft, and a prosthesis of polythene, teflon or wire is fitted between the long process of the incus and the graft. Some operators make use of one of the crura still attached by its head and neck through the incudo-stapedial joint to the incus. This natural tissue is made to impinge on the graft.

John Shea, who pioneered the stapedectomy procedure in 1958 with his polythene strut and vein graft, is now venturing into a field as confounding to the pundits as his original concept was. He is fitting a teflon piston attached to the long process of the incus into an opening made in the footplate. This vibrates within the vestibule, unprotected by a graft.

The present paper is concerned mainly with total stapedectomy in which reconstruction is by means of the vein graft and polythene strut. Several procedures included the adipose-tissue graft and steel-wire prosthesis developed by Schuknecht (1960): The teflon piston was employed in 4 recent cases, not included in this series.

## TECHNIQUE EMPLOYED

In my opinion no advantage is gained by operating under local anaesthesia, since

1. The need for testing the hearing during operation, so essential in stapes mobilization, has disappeared.

2. Haemorrhage proved no obstacle where expert hypotensive general anaesthesia was necessary.

3. Operating on the occasional, restless vertiginous patient under local anaesthesia is hazardous.

The microscope is carefully checked and adjusted for use. The patient is positioned and the external auditory meatus thoroughly cleaned with cetrimide 1% in aqueous solution, while meatal hairs are cut and removed when profuse. The canal is dried and filled with 0.5% chlorhexidine in 70% ethyl alcohol. The surgeon scrubs while the patient is draped after preparation of the auricle and surrounding area. An injection of 0.4 ml. of lignocaine 2% in noradrenalin 1/80,000 is given subcutaneously and slowly into the postero-superior bony meatus. A  $\frac{1}{2}$ -inch length of vein is obtained from the dorsum of the hand, cleaned of adventitial fat, and a fine Shea dissecting scissors (closed) is threaded through the lumen. The scissors are opened to stretch the vein, which is then incised longitudi-

nally while on the stretch. The opened vein is spread on to the gloved finger, intimal surface upward, and cut transversely into halves. These are spread on to gauze intimal surface upward, and kept moist in Ringer's solution.

The draped microscope is adjusted over the ear, and the largest Shea speculum which can be accommodated, is attached to the Shea speculum holder and fitted into the meatus. A sharp endaural knife is a *sine qua non* for making the meatal incision, and a Rosen knife is sharpened on an Arkansas stone under microscopic vision immediately before the incision is made. This is made from '12 o'clock', close to the notch of Rivinus, posteriorly outward in a straight line for 8-9 mm. From this point it passes in a straight line medially and inferiorly to '6 o'clock' on the inferior meatal wall, where it ends on the edge of the annulus and sulcus tympanicus. This allows for an ample triangular shaped tympano-meatal flap to cover any gap that may be left when the posterior bony rim of the meatus is removed. The skin and periosteal meatal flap is elevated to the annulus tympanicus which in turn is elevated from its sulcus. The delicate, tympanic mucoperiosteum is entered and the posterior half of the tympanic membrane, together with its meatal flap, is folded forward over the handle of the malleus.

Inspection of the middle ear reveals a surprising variation in the visibility of the incudo-stapedial region. Sometimes the articulation is practically concealed from view by the posterior bony rim of the meatus, and at other times the entire footplate is visible. The chorda tympani nerve must be pushed forward from below the postero-superior meatal rim and maintained intact, where possible, without stretching. Before proceeding further the mobility of the stapes must be tested. The Shea spoon is used on the overhanging, posterior bony rim until the facial canal and the pyramidal process become visible. The Shea drill can be used with purpose to complete this part of the operation. If the chorda tympani nerve impedes this work, it is sacrificed by cleanly cutting it through with the extra-fine Cawthorne scissors. The sensation of taste returns to the anterior two-thirds of the tongue within 2-3 months. The stapedius tendon is cut and the incudo-stapedial joint widely opened. A McGee anterior-pointing hook is used for this procedure, and the head and neck of the stapes rocked up and down until the head disarticulates from the lenticular process. The crura usually fracture at this stage and are removed with the head and neck. Should the footplate mobilize before the crura fracture, the complete stapes can occasionally be eased out and removed.

The critical work on the footplate is undertaken under 16 × magnification. Mucoperiosteum is cleared from the footplate and surrounding area. I do not attempt to clear inaccessible areas obscured by the long process of the incus. The oval window niche between the promontory and facial canal is

studied, and any overlap of the promontory over the footplate is carefully burred away. Drilling is never done near the facial canal. The 4-mm. strut is placed into the niche and allowed to rest on the footplate. One is able to assess which of the 3 struts ranging from  $3\frac{1}{2}$  - 4 -  $4\frac{1}{2}$  mm. will be the most suitable for length. The thin footplate is pierced centrally with the Schuknecht straight pick in 2 or 3 places transversely across until it fractures. A 1 mm. right-angled, forward-pointing Schuknecht hook is passed through the fracture site and rotated through  $90^\circ$  until the tip lies immediately below the edge of the anterior half of the footplate, which is loosened and eased out of the oval window. A backward-pointing Schuknecht hook of similar dimensions removes the posterior half of the footplate.

A Zöllner angled suction tube with 5 sizes of fine detachable ends and finger-tip valve control is used. Blood lying over the vestibule is sucked away with the finest suction end and open valve. The vein graft with adventitial surface downward is fitted over the oval window. The placing of the graft is a simple matter when using this type of sucker, since the edges can be everted, while folds or irregularities can be 'ironed out' by the sucker, which grips and releases the graft when the valve is closed or opened by finger-tip control.

The 2 ends of a 12-inch length of 6-0 black silk are approximated and clamped together between the jaws of a fine mosquito artery forceps, while the loop at the opposite end is caught between the 2 fine prongs of a Cawthorne strut-applicator. This loop is directed under the long process of the incus immediately proximal to the lenticular process. The silk is pulled taut by gently sliding the mosquito forceps away from the operation site. The long process of the incus is raised  $\pm 1$  mm. to the limit of its 'spring' and left in this position by the drag of the artery forceps. Every operator sooner or later inadvertently subluxates the incus and finds the long process unusually loose and without any spring. This would appear to be a serious mishap which I feel must detract from the final result. I am far more likely to subluxate the incus if I attempt to raise the long process with 1 hand, and simultaneously direct the strut under the lenticular process with the other hand. With the long process already raised, however, I can devote my full attention, with my right hand steadied by my left hand, to the critical task of pressing down the strut into the vein graft and easing its proximal end under the raised lenticular process. Once achieved, the traction on the long process is released, and the lenticular process drops by its spring action perfectly into the cup of the strut. One strand of the loop is cut above the long process, and the silk is pulled out. Slight pressure on the long process, or handle of the malleus, shows free and easy mobility of the new conductive system, and the round window reflex. After cleaning the middle ear cavity of blood and bone dust, the tympanic membrane with meatal flap is replaced in its normal position.

#### DIFFICULTIES AND COMPLICATIONS ENCOUNTERED

*The thick footplate* varies considerably. The centre is often thin enough to pierce with the straight pick, or the hand-operated perforating burr. Once a sufficiently large hole is obtained for a  $90^\circ$  hook or pick to be inserted, further fragmentation can usually be achieved until the footplate is removed. Care must, however, be exercised not to apply overmuch traction on these delicate hooks which can fracture and fall into the vestibule.

Since seeing Shea demonstrate his newest teflon piston operation in London recently, I have carried out 4 such procedures on thick footplates through which holes have been made sufficiently large to accommodate the piston, which has then been fitted with very gratifying results. A small 'collar' of gelfoam is cut and placed around the piston where it enters the vestibule. This seals off the vestibule adequately until the endothelial lining produces a natural seal. I hesitate to carry out this operation as a routine procedure, but feel that it fills a most important gap in our technique, when the thick footplate is encountered or when the niche of the oval window is narrowed.

Where the entire footplate is grossly thickened by diffuse otosclerotic foci involving the crura and massing up over the footplate, the only possible course open, other than the fenestration operation, is to use the motor-driven perforating drill and very carefully to cut a shaft in the centre of the footplate,

until the vestibule is only just entered. This may entail tedious drilling in short bursts, followed by repeated suction and visualization, as the otosclerotic focus may extend below the footplate. The proximal three-quarters of the shaft can be quickly widened by burring out the sides sufficiently to admit the piston. The distal part of the shaft is carefully widened, while the opening into the vestibule is enlarged, if possible, with fine hooks or with the burr as a last resort. Prolonged, uninterrupted drilling or burring should never be entertained as the heat generated will damage the membranous utricle.

*The 'floating' footplate* which suddenly mobilizes into the vestibule is disconcerting. It is, however, supported by strands of mucoperiosteum and endothelium and can be removed without fear of displacing it deeper into the vestibule. A small hole is drilled into the promontory immediately adjacent to the footplate, large enough to admit a fine hook which can be passed under the footplate. Great care is required as sudden elevation of the footplate, or parts of it, may cause negative pressure in the vestibule resulting in commotion of the perilymph and injury to the membranous labyrinth.

*The long process of the incus* varies in size, shape and length. One learns to judge whether the lenticular process is going to fit into the 0.034-inch diameter strut or the slightly larger 0.038-inch diameter strut. When the long process extends well beyond the oval window, the strut fitting into the lenticular process may have to pass into the vestibule at an angle and may consequently impinge on the walls of the oval window. In the past the Schuknecht wire and fat have been used to overcome this difficulty, but the Shea piston can now be employed equally well. When disarticulating the head of the stapes, the lenticular process occasionally comes away attached to the stapes. This again calls for either the Schuknecht or the piston procedure.

On the last occasion, some 70 operations back, that I used the McLay gouge and mallet on the bony meatal rim, the gouge slipped and fractured the long process of the incus through its posterior third! A notched 0.50-inch diameter strut  $5\frac{1}{2}$  mm. in length was fitted between the handle of the malleus and the vein covering the oval window, with a satisfactory result.

*Facial palsy* was not encountered, although dehiscence of the facial nerve is not unusual in the window region.

*Postoperative vertigo* has not proved a problem. Most patients are practically free of symptoms in 5-7 days. Two patients experienced a marked vertigo for over 2 weeks.

#### RESULTS

Of 100 operations performed, the initial 50 patients were followed up for 12 months and longer, while the final 50 were followed up for 3-12 months.

*Analysis of the results* was made by comparing the post-operative air-conduction threshold with the pre-operative bone-conduction threshold, taking the average for 500, 1000 and 2000 c.p.s. frequencies. The greatest improvement obtained was 70 decibels in a patient with a pre-operative air-bone gap of 70 decibels and bone conduction average of 10 decibels. Of particular interest was the postoperative rise of bone conduction in certain patients. Ewart and Shea (1960) have stressed that the postoperative air conduction is often better than the pre-operative bone conduction average. The increase is frequently more than can be explained by the Carhart phenomenon, although it is undoubtedly related to it. It accounts for an operative result that may be better than the pre-operative audiogram would have led one to believe. One finds many cases where post-operative air conduction is better than bone conduction on carrying out tests with the 128, 256 and 512 c.p.s. tuning forks.

Speech-discrimination tests should be a routine pre- and postoperative procedure. It is staggering to discover how poor speech discrimination is soon after an operation; but

it is reassuring to note its improvement after 4-5 weeks, when the higher-pitched frequencies reappear in the hearing spectrum.

I regard closure of the air-bone gap to within 10 decibels as a good result, whether the hearing has improved above the 30-decibel level or not. An average cochlear reserve lower than the 30-decibel loss is not a contraindication for operation, as long as there is evidence that speech discrimination is satisfactory. These are the so-called fragile ears with a poorer prognosis; yet some of these cases have been among my most grateful patients. One old lady still wears a hearing aid, but is delighted with her hearing improvement.

#### First 50 Cases

Thirty-nine cases (78%) have shown excellent hearing improvement with closure or better of the air-bone gap. (A gap of 10 decibels or less is regarded as closure of the air-bone gap.) Six cases (12%) have shown improved hearing but incomplete closure of the air-bone gap. 2 cases (4%) have their hearing unchanged; 1 case (2%) has had the hearing made worse by the operation; and 2 cases (4%) have complete loss of hearing.

#### Case A

In the first patient whose hearing was unchanged, it proved to be the result of a 'floating' footplate which was not removed, since perilymph welled up from the vestibule. A strut was fitted between the footplate and the incus and the tympanomeatal flap was allowed to fall back into position. Perilymph continued to well up past the eardrum. A wick of ribbon gauze was gently packed into the meatus, and gauze with cottonwool dressings packed around the auricle. These were changed regularly when they became soaked, as oozing of perilymph continued for 72 hours before it gradually subsided. Pyrexia did not occur and a broad-spectrum antibiotic (demethylchlortetracycline—'ledermycin') was administered for 7 days usually together with vitamin B compound. The hearing improved for 8 weeks and then dropped to the pre-operative level (Fig. 1). It may very well be the correct procedure to re-open the middle ear and perform a stapedectomy, as the cochlear reserve remains good. The escape of perilymph through an enlarged cochlear aqueduct has been described before and appears to be a complication of no great significance.

#### Case B

In the second patient whose hearing remained unchanged the cause was the all too common grossly-thickened footplate which was encountered before the Shea drill had been obtained. An inadequate opening into the vestibule was made, which later closed up, since hearing, which improved postoperatively, declined to the pre-operative level within 3 months (Fig. 1). This patient, a man of 35 years with excellent cochlear reserve, was revised. After 5 months the strut and vein graft was removed and a larger opening made into the vestibule, which was found to be closed with bony overgrowth, but with the same poor result. This would have been a case *par excellence* for the teflon piston. I have lost trace of this patient and would certainly attempt this procedure if the cochlear reserve remains satisfactory.

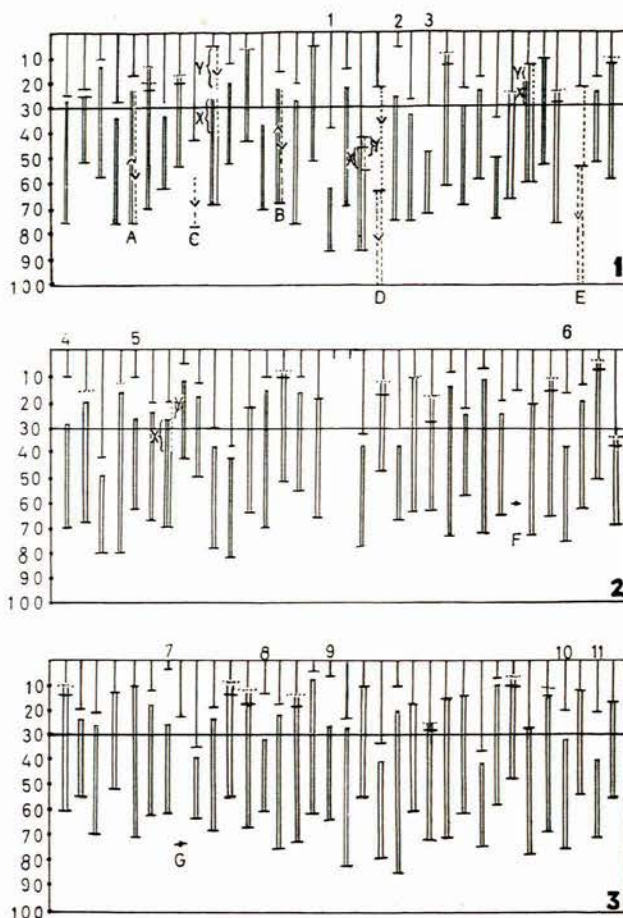
#### Case C

The patient with the depressed hearing after operation was elderly with a poor cochlear reserve and poor speech discrimination. There was no initial response after operation and hearing acuity deteriorated after 6 weeks (Fig. 1). He had an average pre-operative bone-conduction level of 45 decibels over 500, 1000 and 2000 c.p.s. frequencies, with no response in the higher frequencies.

#### Case D

Complete loss of cochlear function occurred as a result of operation in 1 patient with advanced otosclerosis present and a grossly thickened footplate (Fig. 1). This was burred extensively and saucerized into the vestibule, a method described by

Shea, who has since condemned the procedure. Severe vertigo resulted after the operation, and it is likely that damage to the utricle occurred.



Figs. 1-3 give tabulated results of 100 operations. The double vertical lines represent hearing improvement by air conduction, and the short horizontal bars the pre-operative air and bone conduction thresholds. The dotted short horizontal bars represent the postoperative air and bone-conduction thresholds demonstrating the Carhart phenomenon. The dotted arrowed lines represent hearing loss. The letters A-G= cases referred to in the text. X=hearing loss occurring by air conduction after 12 months in cases showing evidence of sensori-neural loss, while Y denotes their bone conduction loss. Numbers 10-100=hearing loss in decibels. Numbers 1-11=hearing improvement without closure of the air-bone gap to within 10 decibels. The hearing levels, both air and bone conduction, have been obtained by averaging the hearing loss at the three speech frequencies 500, 1000 and 2000 c.p.s. Audiometry was based on the American standard of calibration.

#### Case E

The second case of 'dead ear' resulted after a suppurative labyrinthitis. The patient had suffered from a chronic seborrhoeic otitis externa with secondary infection, which had to all intents and purposes been controlled over a 6-weeks period before the operation. *B. pyocyaneus* responsive only to polymixin B. ('aerosporin') was found on culture, but complete and permanent loss of cochlear and vestibular function supervened after the infection was controlled (Fig. 1). Fortunately hearing in the unoperated ear was satisfactory.

#### Second 50 Cases

With the experience gained in selecting cases, and with improved operative technique and equipment, these results are superior to the first series. Forty-three patients (86%) have closure or better of the air-bone gap; 5 patients (10%) have improved hearing, but incomplete closure of the air-bone gap; 2 patients (4%) have unchanged hearing.

*Case F*

A patient with good cochlear function and with no untoward difficulty at operation has made no improvement whatever (Fig. 2). No explanation can be given. The footplate was removed with ease, the strut fitted well and the reconstructed chain functioned normally. A revision of this case is to be undertaken at a future date.

*Case G*

An intriguing case of conduction deafness in 1 ear was seen by an otologist in London, who advised operation for what he considered to be either otosclerosis or interruption of the ossicular chain. I saw this patient, an elderly man with an air-bone gap of 50 decibels in the 1 ear over the 500, 1000 and 2000 c.p.s. frequencies (Fig. 3). He had patent Eustachian tubes and normal-looking drums. At operation I found a mobile footplate and a perfectly functioning ossicular chain and an uninterrupted round window. The tympano-meatal flap was replaced and the ear healed. The hearing naturally remained unchanged. What explanation can be given?

## DISCUSSION

In this series 5 of the ears with improved but inadequate hearing have been revised. In no case was the junction between the strut and the lenticular process found to be anything less than firm and usually covered in a sheath of fibrous tissue. Necrosis of the lenticular process was not seen. Fairly extensive fibrosis of the vein grafts was noted in 3 cases. In 1 case the strut was removed as it was felt that the point may have been impinging on the bony wall of the oval window. A second strut was fitted with the point aimed at what was thought to be the centre of the oval window. This produced no hearing improvement. No attempt was made to remove the vein graft in any of these revisions, and no further loss of hearing occurred. In no patient, however, was the hearing improved.

The second ear, which is usually the better hearing ear with the superior cochlear reserve, is operated on 1 year after the initial procedure, if the patient so desires. Whereas most of the operated ears have maintained or even increased their hearing acuity since the last hearing tests were carried out 3 months after the operation, a few have shown a sensori-neural loss of some significance when examined 12 months after operation. Speech discrimination in these few cases has also dropped. At the first British Congress of Otolaryngology held in London in June 1963, a plea was made to investigate this tendency thoroughly and to be chary of operating on the second ear where sensori-neural loss is present in the first. It must of course be realized that otosclerotic foci in the retro-fenestral or labyrinthine region may still be active and still give rise to increasing sensori-neural loss.

Sudden deafness with vertigo resulting from the strut entering the vestibule, as described by a few writers, has

not occurred in this series. Care must be exercised in choosing the correct length of strut. I find that the strut of 4 mm. can be used in most cases, and I use the strut of 3½ mm. more frequently than the one of 4½ mm. In view of the success of the piston procedure devised by Shea, I feel that perforation of the vein graft by the strut is not the only cause of the deafness, which may be ascribed to pressure on and possible perforation of the membranous utricle, resulting from an over-long strut impinging on it after perforating the vein. Dr. Plester of Düsseldorf cuts off the pointed tip of the strut in order to obviate this complication.

Eight patients who had previously had an operation for stapes mobilization underwent the stapedectomy procedure. Adhesions between the tympanic membrane and the incus had occurred in 3 instances, while the crura had been fractured in 4 instances. Six patients obtained closure of the air-bone gap, while 2 had improved hearing.

Two patients, not included in this series, had mobile footplates which were left strictly alone. These cases, unlike case G described, had an air-bone gap of 15-20 decibels in the 500, 1,000 and 2,000 c.p.s. frequencies with hearing loss but no air-bone gap in the higher frequencies. Fibrotic adhesions in the tympanic cavities with sticky secretions were encountered and attended to. Their hearing was in no way affected by the tympanotomy procedures.

## SUMMARY

One hundred stapedectomies are reviewed. The operative technique, mainly by the Shea method, was described with certain modifications introduced by the author. Eighty-two patients obtained a closure of the air-bone gap to within 10 decibels or better, and 11 cases had improved hearing, giving an overall total of 93% with a successful result. Four patients had unchanged hearing and 3 patients had their hearing made worse by operation, 2 of whom sustained 'dead ears'. The failures have been described.

In no instance has slipping of the strut occurred at its junction with the lenticular process, and no sudden deafness has been reported resulting from the entrance of the strut into the vestibule after perforating the vein graft or the membranous utricle.

## BIBLIOGRAPHY

- Beales, H. P. (1962): *J. Laryng.*, **76**, 192.  
 Cawthorne, T. (1962): *Ibid.*, **76**, 87.  
 Colman, B. H. (1962): *Ibid.*, **76**, 100.  
 Ewart, G. and Shea, J. J. jnr. (1960): *Acta oto-laryng. (Stockh.)*, **52**, 349.  
 House, H. P. (1960): *Arch. Otolaryng.*, **71**, 150.  
 House, H. P., Wullstein, H., Shea, J. J. jnr., Derlacki, E. L., Schuknecht, H., Fowler, E. P. jnr. and Juers, A. L. (1960): *Ibid.*, **71**, 338.  
 Plester, D. (1962): Lectures to the Oto-laryngological Society of Australia.  
 Schuknecht, H. F. and Oleksiuk, S. (1960): *Arch. Otolaryng.*, **71**, 287.  
 Shea, J. J. jnr. (1960): *Ibid.*, **71**, 257.