

## THE PRINCIPLES OF KIELLAND'S FORCEPS RELATIVE TO THE PHYSIOLOGY AND ANATOMY OF MALROTATION OF THE OCCIPUT

MARTIN G. SHELTON, M.B., CH.B., B.Sc., M.R.C.O.G., *Department of Obstetrics and Gynaecology, University of Cape Town*

### THE BASIC FEATURES OF KIELLAND'S FORCEPS

The forceps were designed in 1910 by a Norwegian, Christian Kielland, who, it is interesting to note, was born in Zululand in 1871. They were so constructed as to allow for a true cephalic application together with traction in the axis of the pelvis, regardless of the station, position or attitude of the head. These objectives are achieved by interruption of the pelvic curve at the commencement of the shanks, which are bent backwards at a slight angle with the fenestrated blades. Not only are the blades depressed below the horizontal, but their axis is still parallel to that of the shanks, giving the forceps the 'bayonet shape' described by Kielland. This ensures that during traction most of the force on the foetal head is safely applied to the unyielding maxillae, while excessive pressure is also taken off the perineum. This is shown in Fig. 1, which also demonstrates the importance of traction in a posterior direction when using Kielland's forceps, the handles being elevated only when the head is almost crowned. (An episiotomy should therefore be performed before traction or rotation is applied.)

The two halves of the shank are superimposed, thus permitting the introduction of a sliding lock, as well as minimizing perineal distension. This lock enables the forceps to be applied cephalically to the asynclitic head, which is so frequently encountered in a 'deep' transverse arrest.

It also gives to Kielland's forceps the unusual feature of having two fulcra (F1 and F2 in Fig. 2). For this reason traction and rotation forces should not be applied except to the distal shoulders, so as to ensure that the foetal head is not crushed between the blades of the forceps. (In those unfortunate cases where intra-uterine death of the foetus has occurred, the handles can be compressed deliberately in order to decrease the biparietal diameter of the occiput.)

The reduced length of the distal shoulders makes them mechanically inefficient. This, together with the absence of a pelvic curve, ensures that excessive, and therefore traumatic, rotation force cannot be applied.

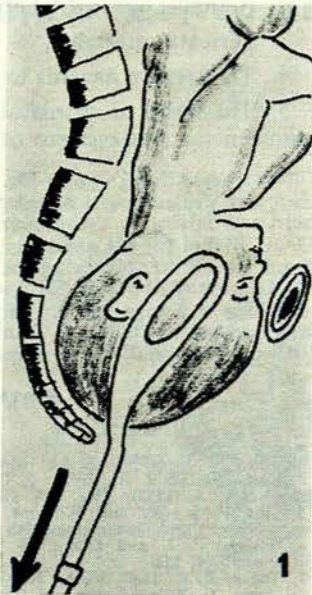


Fig. 1. Traction with Kielland's forceps. The arrow shows the axis of traction.

### ANATOMICAL AND PHYSIOLOGICAL FEATURES OF LABOUR AS APPLIED TO THE USE OF KIELLAND'S FORCEPS

The influence of variations in pelvic architecture on the mechanism of malpositions is well known, and the accoucheur, before using Kielland's forceps, should have a good idea of the pelvic configuration in each individual case.

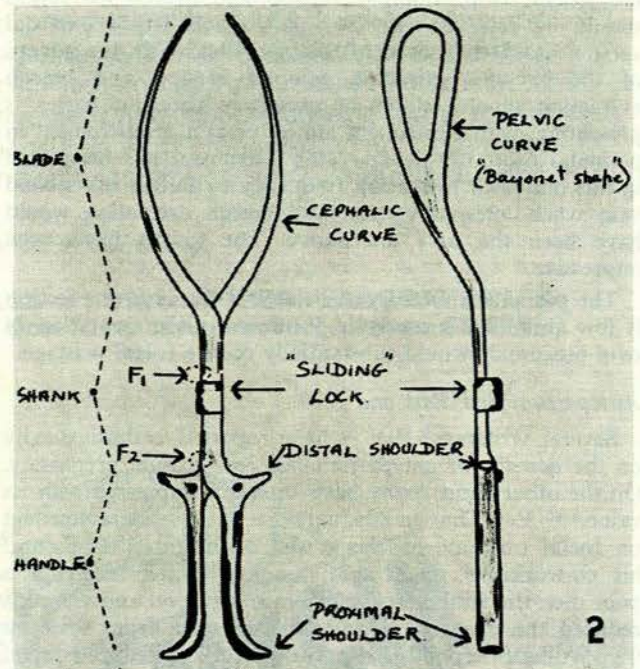


Fig. 2. Kielland's forceps.

The effects of physiological factors on the other hand seem to have been neglected. They are of equal if not greater importance, and must also be considered for a fuller understanding of the many advantages of Kielland's forceps.

### Engagement

Steele and Javert<sup>1</sup> and D'Esopo<sup>2</sup> demonstrated by radiological means that about 60-70% of all vertex presentations engage in the transverse diameter. Of the remainder, half engage as anterior and half as posterior positions.

It had earlier been shown by Caldwell *et al.*<sup>3</sup> that over 80% of these so-called primary posterior positions were in fact an adaptation of the vertex to a narrow fore-pelvis in the presence of an adequate conjugate diameter. These posterior positions should therefore be regarded, not as a malposition, but rather as the optimum position of the vertex for that particular pelvis.

Brim shape is thus the dominant factor in engagement, and deliberate disengagement of an already well-moulded



head should not be used as a method of facilitating rotation. Apart from the dangers of prolapse of the cord, absolute disproportion, even, may be introduced by this procedure.

#### Descent

The first stage of labour is occupied primarily by dilatation of the cervix, for radiological studies have also shown that during this stage there is variable, but usually minimal, descent of the presenting part. Maximal descent followed by internal rotation commonly occurs only after full dilatation of the cervix.<sup>1</sup>

Consequently rotation and extraction with Kielland's forceps should only be performed after full cervical dilatation. Some authorities maintain that manual or forceps rotation in the first stage often improves the nature of uterine contractions in cases with a posterior position, where the incoordinate labour has failed to respond to a pitocin drip. This is a non-physiological procedure, often traumatic or unsuccessful, which could preferably be replaced by the use of a vacuum extractor. Thus uterine contractions often dramatically improve once traction is applied to the foetal head. Furthermore, the administration of a general anaesthetic is avoided, and anterior rotation of the occiput can usually be effected on the perineum, where it is often self-directed.

#### Flexion and Extension

Delay in occipito-posterior positions, possibly resulting in a deep transverse or posterior arrest, is usually associated with partial extension of the head. This in turn may be due to a combination of factors, viz.:

1. Inefficient, incoordinate uterine action.
2. Forward projection of the maternal spine and sacral promontory, which leads to extension when the back of the foetus is posterior.
3. Arrest of the biparietal diameter between the sacral promontory and the iliopectineal eminence (sacro-cotyloid diameter), which allows the forehead to descend.
4. Malalignment of the foetal axis with the axis of the

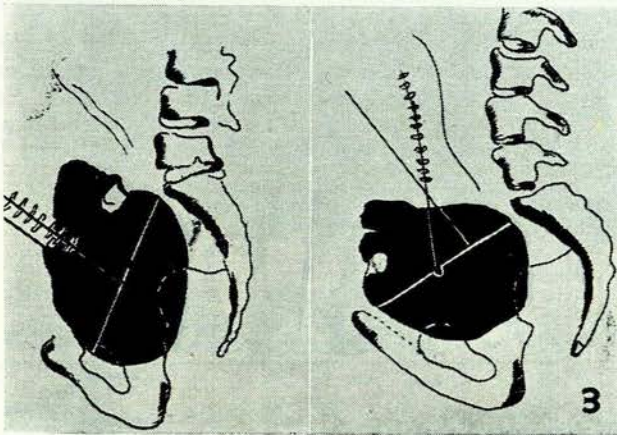


Fig. 3. Showing extension of the vertex (see text).

pelvic inlet. This causes the occipital lever to be longer than the frontal, which aggravates extension of the vertex as shown in Fig. 3.

Usually, however, further extension is prevented by counter-pressure exerted by the fore-pelvis, which also promotes moulding of the frontal bones under the parietals (Fig. 4). The brow is fixed against the upper fore-pelvis, while the occiput is forced downwards and away from the




Fig. 4. Illustrating counter-pressure by the fore-pelvis, preventing further extension.

sacrum. With this initial flexion the foetal trunk moves forward, the relative lengths of the lever arms are altered, and a further flexion force is introduced.

Therefore in posterior positions flexion normally occurs late, and is dependent on descent and forward excursion of the foetal axis. This can only occur in the presence of good expulsive powers, and so usually takes place in the second stage of labour.

Marked deflexion results in the presentation of larger sectional planes, which are oval and not circular in shape. Hunter<sup>4</sup> showed that in the unmodelled mature head, the surface area of the occipito-frontal coronal plane is 47% greater, and the mento-vertical 80% greater, than the suboccipito-bregmatic plane. These increased diameters make rotation and extraction with Kielland's forceps more difficult, especially as the blades of the forceps now grip the bitemporal diameter of the deflexed vertex and are thereby more likely to slip off. Before applying the forceps it is therefore advisable to assess the degree of flexion by vaginal examination and, if necessary, to try to correct it to some extent by digital pressure over the sinciput during contractions.

#### Malrotation

Failure of occipito-anterior conversion is the basic fault in deep transverse and posterior arrests. A complete understanding of the factors involved in spontaneous rotation is therefore essential, for one is called upon to simulate this mechanism during delivery with Kielland's forceps.

Malrotation occurs in about 10% of occipito-posterior positions, in which the occiput may (a) rotate into the hollow of the sacrum (occipito-sacral), (b) not rotate at all, remaining obliquely posterior (occipito-posterior), or (c) rotate anterior to the transverse ('deep', transverse arrest).

Malrotation may also occur in primary occipito-lateral positions, which may (a) not rotate at all (primary, 'deep', transverse arrest) or (b) rotate posteriorly into the persistent occipito-posterior or the occipito-sacral positions.

It is generally accepted that rotation occurs late when the head descends onto the inclined planes of the levator ani muscles ('pelvic gutter'), and that the presenting area of the vertex rotates anteriorly (West, 1856). However, the radiographic studies of Caldwell *et al.*<sup>3</sup> showed that the



inclined planes of the pelvic floor, while responsible for rotation, do not always determine in what direction it will occur.

It is well known that the pelvic architecture has a marked influence on the mechanism of internal rotation. D'Esopo,<sup>2</sup> in his radiological investigations, showed that large babies, a small pelvic inlet, android or anthropoid pelvis, forward sacrum, converging side walls, and a narrow subpubic arch, were all factors that predisposed to difficult labours and deep transverse or posterior arrests. Yet a further factor and possibly the most important of all should be included, viz. poor expulsive powers.

In the presence of a reduced brim due to a narrow fore-pelvis, long rotation usually occurs on perineum. For this to happen, however, a good expulsive force is necessary to promote descent and flexion, so reducing the presenting diameters of the foetal head. It is therefore preferable to rotate these cases of deep transverse or posterior arrest and deliver them with Kielland's forceps under pudendal nerve block. In this way the forceful expulsive powers of uterine contractions and 'bearing-down' efforts are retained.

When deep posterior arrest is due to prominent spines or converging side walls, the head can usually be brought down as an oblique posterior, provided, of course, that there is no absolute disproportion. In this way the wider posterior strait is utilized, and long rotation is often self-directed on perineum.

Deep transverse arrest, when due to a flat posterior segment, should ideally be brought down as such with Kielland's forceps. The head is thus guided anteriorly into the retropubic space, where rotation can be effected.

When the head is arrested in the occipito-sacral position, flexion is encouraged by traction on the head downwards and anteriorly, and rotation again carried out on perineum. Only when the head is deep and well moulded (Fig. 5), in

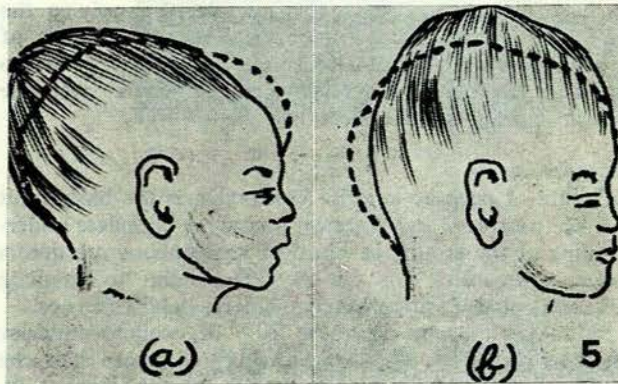


Fig. 5. Moulding found in (a) occipito-anterior and (b) occipito-posterior positions. The latter is more subject to possible tentorial damage because of the extreme elevation of the falx cerebri.

the presence of a reduced subpubic angle, should a deliberate 'face to pubis' delivery be allowed. In these cases an extensive episiotomy will avoid the excessive perineal distension that is produced by the wide biparietal diameter.

#### Asynclitism

Steele has shown that in normal labour with the head in

the transverse the posterior, parietal bone presents at the brim (Litzmann's obliquity). Engagement is achieved by descent and lateral flexion of the head, resulting in subsequent anterior asynclitism (Naegele's obliquity).

This favourable mechanism of asynclitism presents the smaller subparieto-supraparietal diameter of 9 cm. as opposed to the biparietal diameter of 9.5 cm.

The anterior variety is frequently encountered in cases of deep transverse arrest—hence the relative ease with which one can feel the ear anteriorly to confirm the position of the vertex. Asynclitism can readily be corrected by Kielland's forceps with its sliding lock, and should always be achieved before rotation. If this correction is not spontaneous during initial traction, then it should be brought about by a gentle pull on the posterior shoulder of the handle. In this way pressure over the carotid sinus by the tip of the more advanced anterior blade is avoided.

#### Powers

The common association between posterior positions and incoordinate uterine action, usually of the hypotonic variety, is well known. It seems ironical that the mechanism that is so dependent on good uterine contractions to promote flexion of the invariably extended head should so often be accompanied by inefficient uterine action. It is debatable whether the malposition is the cause or effect of this incoordinate state. Does the deflexed head by its asymmetrical distension of the cervix predispose to the abnormal uterine action, or is it the weak contractions themselves that fail to flex the head, so inhibiting long rotation?

No matter which is the primary cause, it is obvious that strong, expulsive forces are a necessity in preventing a deep transverse or posterior arrest.

It has already been shown (Fig. 3) that the axis of uterine thrust in posterior positions tends to operate at a mechanical disadvantage since it is out of alignment with the axis of the pelvis. This malalignment is further aggravated by the deep angle of pelvic inclination so often found in anthropoid pelvis. The effective force of uterine contractions is therefore misdirected and misspent, especially in the first stage of labour.

Caldyro-Barcia and Alvarez (1952)<sup>5</sup> have shown by their intramural tocometric studies that first-stage contractions raise the basal intra-uterine pressure from about 4 mm.Hg to 40-90 mm.Hg. However, in the second stage bearing-

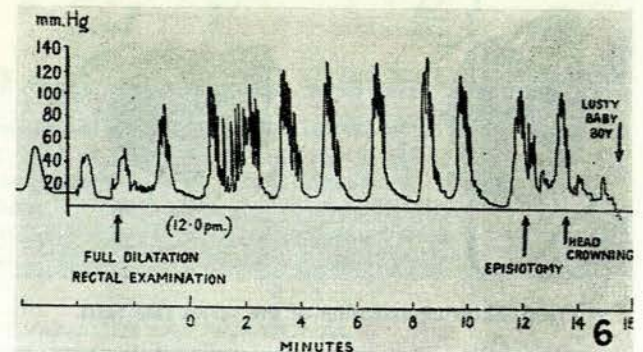


Fig. 6. Record of intra-uterine pressure during delivery [from Williams and Stallworthy (1952): *Lancet*, 1, 330].



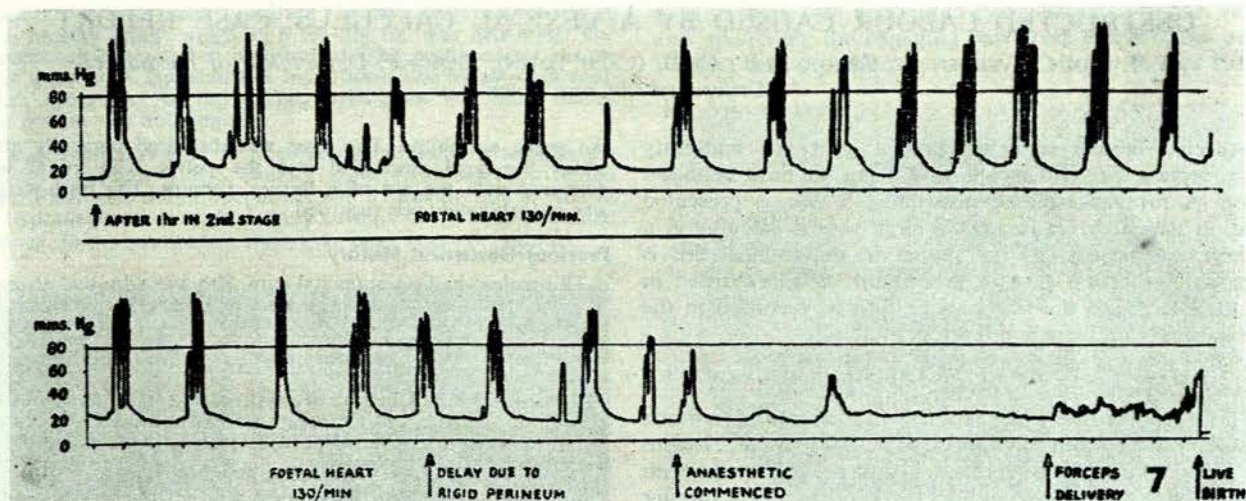


Fig. 7. Recordings of intra-uterine pressure taken during the second stage of labour. The lower graph illustrates the effect of general anaesthesia on the force and frequency of uterine contractions.

down efforts superimposed on uterine contractions can raise this pressure to 120 or even 180 mm.Hg. As these patients with transverse or posterior arrests are usually primigravidae with well developed anterior abdominal walls, their bearing-down efforts should be retained if possible. Williams and Stallworthy<sup>6</sup> have confirmed these findings (Fig. 6), and have also shown that with a general anaesthetic, not only do uterine contractions almost cease, but those that do occur are of a very low intensity (Fig. 7).

Other advantages of regional as opposed to deep general anaesthesia are many. There is no further depression of the foetus, which has usually been exposed to a prolonged labour and heavy sedation. Flexion may be encouraged by digital pressure over the syncliput during contractions, and remnants of the anterior lip of the cervix can also be reduced if present. By complaining of pain down one leg the patient will give ample warning of excessive pressure over the sacral plexus. The chances of a postpartum haemorrhage, already predisposed to by the prolonged and often incoordinate labour, are also reduced.

In view of all these advantages, we prefer to use Kielland's forceps under regional anaesthesia (pudendal nerve block and occasionally caudal anaesthesia). Over the past 3 years at the Peninsula Maternity Hospital, Kielland's forceps have been applied successfully on 48 patients for rotation and extraction, including one mento-posterior presentation. In 33 of these cases regional anaesthesia was used, and on no occasion did it have to be abandoned in favour of a general anaesthetic. In most of the other 15 cases, general anaesthesia was indicated by the presence of pre-eclamptic toxæmia. Among the 48 cases, the child was born alive in 45 (in addition to 1 neonatal death) and there were 2 stillbirths. The neonatal death was possibly due to an intracranial haemorrhage but permission for a postmortem was refused. The only other trauma in a foetus was one facial abrasion. In both stillbirths, intra-partum death, due in one case to prolapse of the cord, and in the other possibly to postmaturity, had already occurred before delivery.

### Conclusions

The use of Kielland's forceps demands a thorough knowledge of its characteristics and methods of application as well as a good understanding of both the physiology of labour and the architectural anatomy of the pelvis.

Contrary to previous beliefs, traction should precede rotation, which takes place on the perineum and is usually self-directed. Only occasionally will certain pelvic abnormalities demand disimpaction and rotation before extraction.

The powerful expulsive forces produced by the summation of uterine contractions with bearing-down efforts should not be wasted. For this and many other reasons regional anaesthesia is preferable to a general anaesthetic in most of these cases.

When applied correctly and used gently, Kielland's forceps provide an easy, safe and physiological method of delivery in cases of arrest due to malrotation of the occiput.

I am indebted to the late Prof. James T. Louw and to Dr. C. J. T. Craig for the interest they showed in the preparation of this paper, and for their encouragement and advice.

### REFERENCES

1. Steele, K. B. and Javert, C. T. (1942): *Surg. Gynec. Obstet.*, **75**, 477.
2. D'Esopo, D. A. (1941): *Amer. J. Obstet. Gynec.*, **42**, 937.
3. Caldwell, W. E., Moloy, H. C. and D'Esopo, D. A. (1934): *Ibid.*, **38**, 824.
4. Hunter, W. (1943): *J. Obstet. Gynaec. Brit. Emp.*, **50**, 260.
5. Caldayro-Barcia, R. and Alvarez, H. (1952): *Ibid.*, **59**, 646.
6. Williams, E. A. and Stallworthy, J. A. (1952): *Lancet*, **1**, 330.

### BIBLIOGRAPHY

- Caldayro-Barcia, R., Alvarez, H. and Reynolds, M. (1950): *Surg. Gynec. Obstet.*, **91**, 646.
- Caldwell, W. E., Moloy, H. C. and Swenson, P. (1939): *Amer. J. Roentgenol.*, **41**, 505 and 719.
- Calkins, L. A. (1947): *Amer. J. Obstet. Gynec.*, **53**, 488.
- Idem* (1949): *Ibid.*, **57**, 106.
- Danforth, D. N. (1953): *Ibid.*, **65**, 120.
- Donald, I. (1956): *Practical Obstetrical Problems*, 1st ed., p. 335. London: Lloyd-Luke.
- Holmes, J. M. (1958): *J. Obstet. Gynaec. Brit. Emp.*, **65**, 310.
- Hunter, G. C. S. (1960): *East Afr. Med. J.*, **37**, 289.
- Hunter, W. (1953): *J. Obstet. Gynaec. Brit. Emp.*, **60**, 327.
- Jones, E. P. (1952): *Kielland's Forceps*, 1st ed. London: Butterworth.
- Idem* (1957): *Brit. J. Clin. Prac.*, **11**, 434.
- Percival, R. (1959): *British Obstetric Practice*, 2nd ed., p. 624. London: Heinemann.
- Redman, T. F. (1953): *Amer. J. Obstet. Gynec.*, **66**, 607.
- Williams, E. A. (1952): *J. Obstet. Gynaec. Brit. Emp.*, **59**, 635.