

OVERLAPPING OF THE FOETAL SKULL BONES IN BREECH PRESENTATION

L. C. HANDLER, M.B., CH.B., *Department of Radiodiagnosis, Groote Schuur Hospital, Cape Town*

The pitfalls of Spalding's sign in vertex presentation are well known and due care is taken in the interpretation of the sign. In breech presentation, however, it is generally held that this sign is definite evidence of intra-uterine death. Based on two cases of breech presentation, this paper discusses a possible pitfall.

SPALDING'S SIGN

'With the X-ray, the decreased size of the foetal head from postmortem shrinkage can be determined because the cranial bones remain at nearly the same size and shape.' Spalding¹⁸ wrote these words in 1922 in an article entitled 'A pathognomonic sign of intra-uterine death', in which he first described this sign.

He presented a series of 21 cases, 3 of which were cases of intra-uterine death due to congenital syphilis. These 3, together with a 4th (non-fatal) case (vertex presentation with a prolonged first stage of labour), all demonstrated the radiological sign that today is known by his name. In the conclusion of his article he stated that this overlapping (owing to labour) 'can be easily differentiated from that produced by foetal death'. In the former there is no diminution of skull contents, as is shown by the bulging of the vault bones between the suture lines. Present-day opinion holds the view that labour can produce a radiographic appearance identical with that of foetal death.

The sign as described by Spalding in his original article embraced the following two elements:

1. *Overlapping* of the free edges of the flat bones of the cranium in much the same way as tiles on a roof (imbrication or plication). The necessary prerequisite to overlapping is that the bones are at different levels (disalignment, malalignment or displacement). This disalignment is implied; the overlap is stated explicitly.
2. *Maintenance of shape*. The bones must maintain their shape. They may not buckle as they did in Spalding's patient with prolonged stage 1. 'The radius of curvature of the shrunken head becomes obviously smaller than that of the unchanged cranial bones';¹⁸ in other words, there is disproportion between skull bones and contents (Fahmy⁹).

Rohan Williams²² describes Spalding's sign as disalignment and overriding of the cranial vault bones at the sutures. In his very next sentence he describes the appearance of 'moulding' as disalignment only; and states that angulation and actual overriding, which is common in foetal death, is only seen in the rare extreme degree of moulding.²²

Nevertheless, most people define Spalding's sign as overlapping of the free edges of the flat skull bones resulting from death, and do not mention the angulation.^{10,5,1,19}

Spalding's Sign in Vertex Presentation

Over the past 40 years it has been recognized that the following conditions sometimes produce a radiological appearance of overlap in a living foetus, with audible heart sounds (false Spalding's sign):

1. During or just before labour.^{11,18,21} Today most agree with Schnitker *et al.*¹⁷ that the overlapping seen after engagement of the head or during labour cannot be differentiated from the imbrication of foetal death (cf. Spalding's article). In support of this contention, Borell and Fernström²⁰ reviewed the illustrations in the literature and came to the conclusion that Spalding's sign has often been confused with normal moulding, which, owing to technical factors, simulates overriding (pseudo-Spalding's sign).

2. After rupture of the membranes.^{7,11,9}

3. In the normal foetus, as the result of radiographic projectional errors. This was described by Jungman¹² in 1928, and has long been a source of anxiety to those radiologists who may commit themselves to a diagnosis of foetal death on a single shadow in a single plate. In 1939 Hartley¹⁰ stressed the point that this diagnosis may be made only if *all* the vault bones overlap and in *all* views. At about that time Milne¹⁴ recorded a face presentation with Spalding's sign in a live infant, and his radiograph showed imbrication in one suture line on one plate; was the overlap not a projectional effect?

- 4 and 5. Microcephaly²¹ and craniostenosis.²¹

6. Oligohydramnios and diminished foetal viability—placental senility.⁹

7. Compression of skull between fibroids and bony pelvis.⁵

These exceptions, especially the first, have altered the description of Spalding's sign from 'pathognomonic' to 'strong presumptive evidence'.²¹ Nevertheless, the presence of an apparent Spalding's sign with a 'floating' head before the onset of labour is virtual proof of foetal death.^{22,16} Does this hold for the *breech* presentation?

In Breech Presentation

Two cases are now described in which a live infant presented and was delivered by the breech after X-ray examination had indicated overlap—false Spalding's sign.

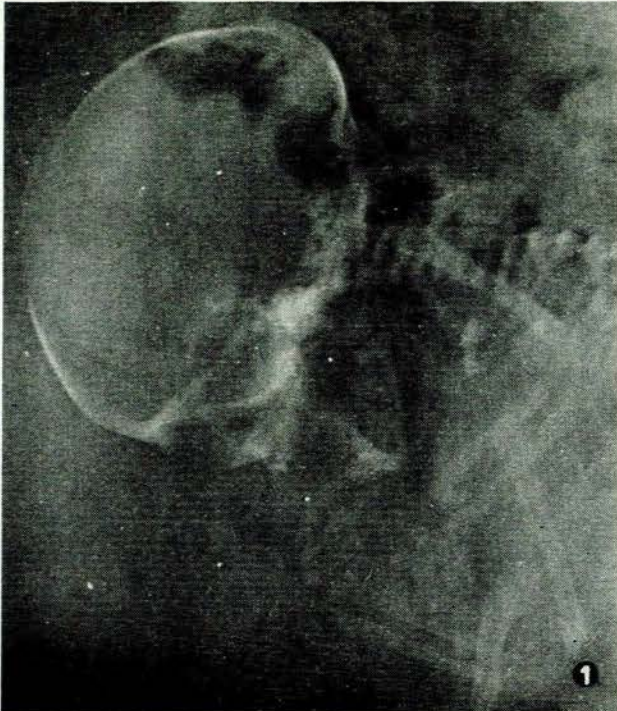


Fig. 1. Case 1. Lateral view of mother's abdomen, showing overlap of foetal skull bones (2.2 cm. at coronal suture, 1.0 cm. at lambdoid suture).

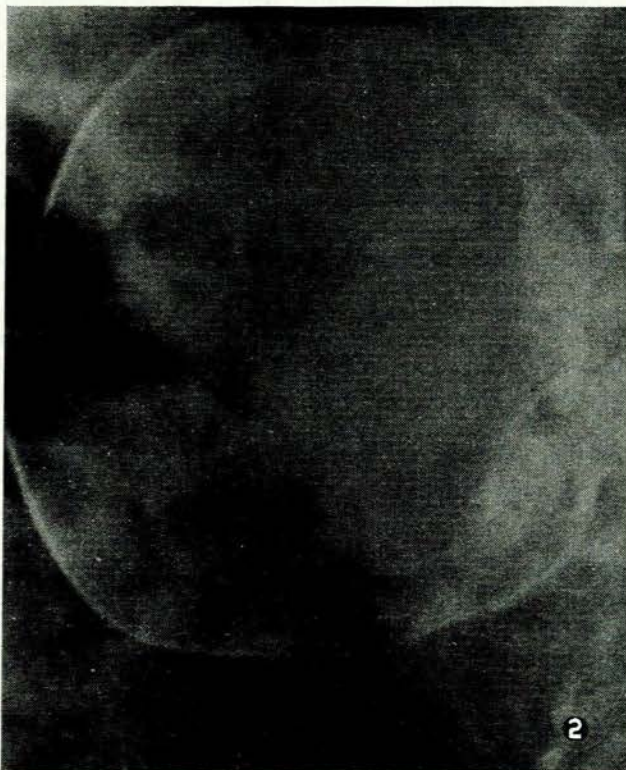

Fig. 2. Case 1. Prone view of mother's abdomen, showing displacement without overlap (0.4 cm. at sagittal suture).

Case 1

Coloured, aged 41 years, para-5, gravida-6. At 38 weeks' pregnancy she was referred for radiological examination to exclude an abnormality in a persistent breech after a 4th unsuccessful attempt at external cephalic version. Lateral view (Fig. 1) demonstrated a breech presentation with overlap of skull bones—Spalding's sign. The prone view (Fig. 2) did not show this sign, but showed displacement of the bones. Next she was admitted to the maternity hospital, having had a show. Labour pains began about 36 hours after X-ray and the membranes ruptured 8½ hours later. A baby weighing 6 lb. 13 oz. was delivered by the breech, and the healthy mother and infant were discharged during an uneventful puerperium.

Case 2

Coloured, aged 31 years, para-3, gravida-4. A radiological examination was conducted to confirm the diagnosis of breech

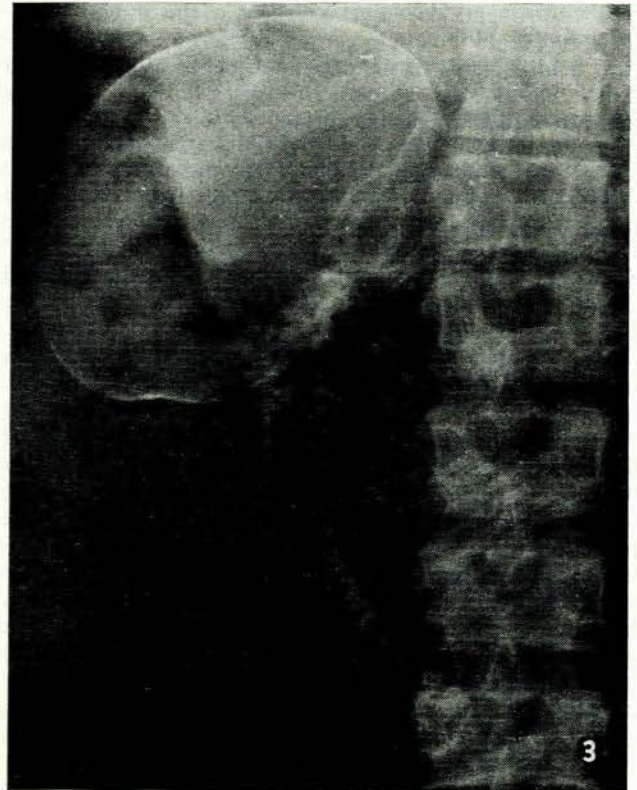


Fig. 3. Case 2. Prone view of mother's abdomen, showing overlap of foetal skull bones (2.4 cm. at coronal suture).

presentation at term. The prone view (Fig. 3) showed a breech with overlapping of the skull bones, notwithstanding that foetal movements were felt by the mother and clearly palpated at the time. Using identical positioning and radiographic factors the radiograph was repeated in an effort to reproduce the sign. Unfortunately, the foetal head had rotated and assumed a new position, and no overlap was apparent (Fig. 4). A 3rd radiograph (Fig. 5)—localized view—was taken with the mother in a supine position, and confirmed perfect alignment. (The last plate was exposed because the radiologist supervising the examination considered that the overlap was in fact a mechanical effect caused by pressure between mother and couch.) She was delivered of a full-term live infant a week later.

DISCUSSION

Mechanism of Spalding's Sign

Since Spalding's original article on the subject, his argu-

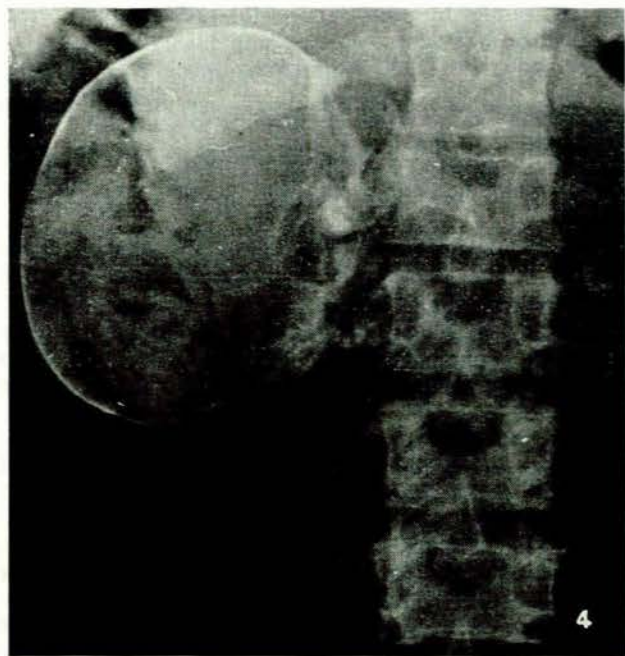


Fig. 4. Case 2. Showing no overlap but 0.1 cm. of displacement.

ment that the overlapping of foetal skull bones is due to postmortem shrinkage of the intracranial contents has been accepted by almost everyone. Hartley¹⁰ believes that the weight of the foetus increases the overlap in the vertex presentation, whereas in the breech presentation Spalding's sign may not be found. On the basis of this argument, Snow¹⁹ recommends that all obstetric radiological examinations should be made in the lateral recumbent position

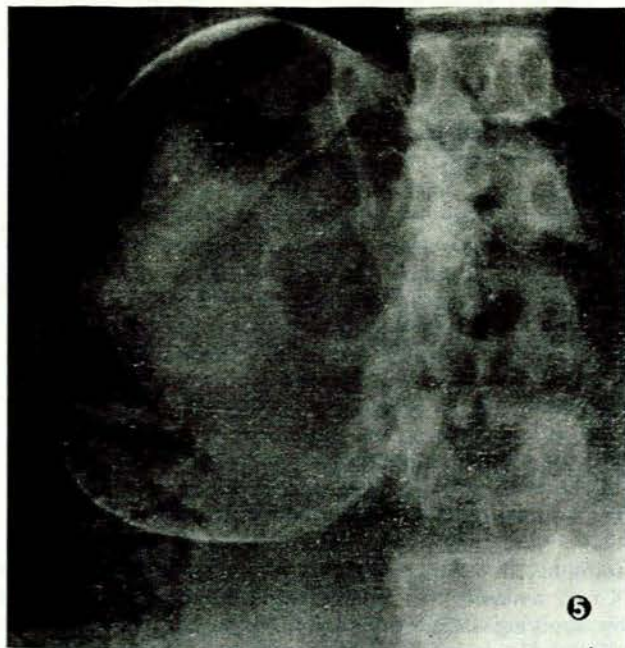


Fig. 5. Case 2. Supine projection. Localized view of foetal skull showing neither displacement nor overlap.

as well as the standing position, thereby facilitating the overlap.

A minority, however, feel that the sign is caused by (a) absence of cerebral fluid,⁸ (b) desiccation of foetus after maceration, (c) increased intra-uterine pressure, or (d) decalcification of the cranial bones.

The pathological changes of maceration are entirely due to autolysis, for intra-uterine death almost always occurs in an aseptic environment. Now it is known that the cerebral softening and liquefaction take place about 3-4 days after foetal death. According to Caughey,² most estimates place the precise time of foetal death at about 4-7 days before overlapping and separation of the foetal skull bones appear.^{22,19,16,15} Because of this time relationship it is felt that Spalding's sign is a manifestation of autolysis, the liquefied contents having leaked out of the cranium and produced shrinkage.

Overlap in the Breech Presentation

Although little has appeared in the literature on the problem, it is widely held that overlapping of the foetal sutures in a breech presentation is an infallible sign of foetal death, or at the very least strongly presumptive. A slight degree of overlap on a single radiograph in a breech case is often accepted as confirmation of the clinical diagnosis of intra-uterine death.

Several writers^{12,20,19} have felt that in breech presentation Spalding's sign will appear later and be less frequent because less pressure is transmitted to the head. It is certainly taught that Spalding's sign occurs later in the breech presentation and when present is most reliable. Holm¹¹ investigated 33 cases of foetal death, 3 of them being breech presentations. In one of the latter there was slight overlapping after an estimated 4 days of intra-uterine death. In another the foetus showed kyphosis and free gas, but no overlapping; and in the 3rd case there were no radiological signs after 7 days of intra-uterine death.

In his article 'Radiology in pregnancy' Hartley¹⁰ did not even discuss the spurious appearance of Spalding's sign with a live breech pregnancy. In fact, he was perturbed because overlap was both tardy and difficult to identify in its lesser degrees, and therefore advocated the ball sign (hyperflexion), especially in breech cases.

The importance given to Spalding's sign when present in a breech case seemed to grow as its significance in the vertex presentation waned. The breech is quoted as the exception in which the sign always held—whether membranes were intact or not, whether labour had commenced or not. The common causes of false Spalding's sign do not apply in a breech presentation.

However, radiographic projectional errors play the same role whatever the lie of the foetus. The obliquity of the X-ray beam relative to the sutures was felt to be the cause of false overlapping,¹² (i.e. the presence of Spalding's sign in a viable pregnancy), and in 1941 Billing³ performed the following experiment to clinch the matter: A hollow glass hemisphere 10 cm. in diameter was cut in half and the two halves X-rayed in various positions relative to each other. He described the effect on the images when the 2 pieces of glass were separated by 5 mm. and one was placed 5 mm. above the other (this corresponds

to displacement of vault bones without overlapping). When the beam is parallel to the suture line the image records the displacement only; but, apparent overlapping of the images is produced if the beam is oblique relative to the suture line. Thus Billing proved experimentally that displacement could produce an appearance of overlapping under certain projectional conditions.

The larger the angle of the incident X-ray beam the greater the degree of seeming overriding. Borell and Fernström^{3a} investigated this phenomenon, using foetal heads as models; they found that 'seeming overriding over a distance of 2 cm. or more is not produced if the angle the beam forms with the suture does not exceed 30°'. Because of the difficulties in application they consider Spalding's sign to be present only in those cases where the overriding exceeded 2 cm. and the beam formed a small angle with the suture'.

Both the breech cases described in the present article appeared to show displacement of the vault bones in one view and overlap in another. One may ask why two apparently normal breech presentations should show displacement of skull bones. The following are possible explanations:

1. Both mothers were at term. Borell and Fernström³ have shown that displacement (as distinct from overlap) is seen in (a) intra-uterine death and (b) during or shortly (up to one week) before labour; in their group of live births disalignment before the onset of labour was present in 10% of foetuses presenting by the breech, and during parturition 65% showed this feature. I believe that this factor is of importance.

2. Prone projection is commonly used in obstetric radiography because this view causes compression of soft tissues, with resulting increase in detail and reduction in exposure. Magnification of the foetus is reduced to a minimum by its close apposition to the film. In both of the cases described, the mother, supported by pillows, lay on her baby during exposure, and liquor amnii at term may not be of sufficient volume to prevent unequal pressures being applied to the skull. This aspect of the problem is not referred to in the literature.

3. The numerous attempts at external cephalic version that had been made in case 1 probably had no effect on the foetal skull, because (a) they were attempted at intervals of one week, and (b) 18 hours elapsed between the final attempt and X-ray. Caffey⁴ states that moulding persists for no longer than several hours after birth.

It is therefore felt that the probable explanation of the Spalding's sign in these two breech presentations is a combination of (a) displacement of skull bones (by approach-

ing labour⁵ and by pressure) and (b) radiographic projectional error.

SUMMARY

1. The mechanism of Spalding's sign in intra-uterine death is discussed.
2. The causes of overlapping are listed and the difference between Spalding's sign and displacement are discussed.
3. Two cases of breech presentation with apparent overlapping of the cranial bones are discussed and possible explanations listed.
4. Whereas the prone position is a most satisfactory one in obstetric radiology, and widely used, attention is drawn to its incrimination in the production of a false Spalding's sign.
5. The question of any appearance resembling a Spalding's sign on a *single prone film* is raised. It is felt that it carries weight (a) in the presence of clinical support and (b) if other satisfactory radiological criteria of intra-uterine death are present. In the absence of (a) or (b), Spalding's sign should be further investigated by exposing radiographs in the prone or lateral recumbent position, especially in cases of breech presentation and cases where the liquor amnii is deficient either through oligohydramnios or rupture of the membranes.

I wish to thank Drs. L. Werbeloff and R. E. Kottler, of the Department of Radiodiagnosis, Groote Schuur Hospital, for helpful advice and criticism, and Dr. J. G. Burger, Medical Superintendent, for permission to publish.

REFERENCES

1. Berman, R. (1955): *Obstetrical Roentgenology*, 1st ed., p. 379. Philadelphia: Davis.
2. Billing, L. (1941): *Acta radiol. (Stockh.)*, **22**, 277.
3. Borell, U. and Fernström, I. (1958): *Ibid.*, **49**, 409.
- 3a. *Idem* (1958): *Acta obstet. gynec. scand.*, **37**, 286.
4. Caffey, J. (1961): *Pediatric X-ray Diagnosis*, 4th ed., p. 19. Chicago: Year Book Medical Publishers.
5. Coughy, A. F. (1961): *Obstet. Gynec. Surv.*, **16**, 153.
6. Donald, I. (1959): *Practical Obstetrical Problems*, 2nd ed., p. 42. London: Lloyd-Luke.
7. Donaldson, I. A. (1962): *Brit. Med. J.*, **1**, 638.
8. Dyer, R. P. (1962): *S. Afr. Med. J.*, **36**, 627.
9. Fahmy, E. C. (1938): *Edinb. Med. J.*, **45**, 137.
10. Hartley, J. B. (1939): *Brit. J. Radiol.*, **12**, 193.
11. Holm, O. F. (1957): *Acta obstet. gynec. scand.*, **36**, 58.
12. Jungman, M. (1928): *Zbl. Gynäk.*, **52**, 2788.
13. Kehrer, E. (1931): *Ibid.*, **55**, 2530.
14. Milne, G. P. (1939): *J. Obstet. Gynaec. Brit. Emp.*, **46**, 77.
15. Roberts, R. E. (1936): *Brit. J. Radiol.*, **9**, 415.
16. Schinz, H. R., Baensch, W. E., Friedl, E. and Uehlinger, E. (1954): *Roentgen Diagnostics*, Vol. 4, p. 3930. New York: Grune & Stratton.
17. Schnitker, M. A., Hodges, P. C. and Whitacre, F. E. (1932) *Amer. J. Roentgenol.*, **28**, 349.
18. Spalding, A. B. (1922): *Surg. Gynec. Obstet.*, **34**, 754.
19. Snow, W. (1952): *Roentgenology in Obstetrics and Gynaecology*, 1st ed., p. 118. Springfield, Ill.: Thomas.
20. Szello, F. (1931): *Arch. Gynäk.*, **145**, 495.
21. Thomson, J. L. G. (1950): *Brit. J. Radiol.*, **23**, 122.
22. Williams, E. R. (1958): *A Textbook of X-Ray Diagnosis*, 3rd. ed., p. 585.