

TWO INTRA-ORAL IMPLANTS*

ROSSALL SEALY, M.A., M.MED. (RAD. T.), F.F.R., P. L. M. LE ROUX, M.Sc., A. INST. P., and E. J. VAN DER MERWE, M.Sc.†

Department of Radiotherapy, Groote Schuur Hospital, Cape Town, and University of Cape Town

The methods of treatment described here are the product of necessity. While the department in which these techniques are being evolved has for many years enjoyed such facilities as clinical cooperation and consultation clinics second to none, it has laboured under the disadvantages of lack of supervoltage equipment and distance from the suppliers of radioactive isotopes. These two last factors have produced somewhat unusual therapeutic approaches to two intra-oral cancers which may be of

interest to our overseas colleagues and those similarly placed to ourselves. The first method is perhaps not new, but should not be forgotten, and the second is a new application of a well tried isotope, Tantalum 182.

I. CARCINOMA OF LOWER ALVEOLUS

Cancer of the alveolus and gum margin has classically been the preserve of the surgeon, and hemi-mandibulectomy the treatment of choice. This operation is rightly said to leave surprisingly little deformity, but the functional result is often poor. The wearing of a lower denture, without reconstruction, is impossible, and chewing

*From a paper read at the African Radiology Congress, Bulawayo, 1962.

†Now at the Karl Bremer Hospital, Bellville, Cape.

of food may be difficult or inefficient. Speech is impaired. Plastic surgeons rightly tend to delay reconstruction until about 3 years after the primary operation, when the chances of local recurrence are reduced to a minimum. By this time the patient, often old, has come to accept the disability, and because of his acquiescence, his age, and the disease for which mandibulectomy was performed, reconstruction is often never attempted.

It therefore seemed worth while, in spite of the absence of high-energy beams, to see if radiation could be offered to these patients, the price being a course of radiotherapy before possible mandibulectomy.

We have always treated early carcinoma of the gum with intra-oral radium moulds, and the very large lesions, with or without clear evidence of invasion of bone, with X-ray therapy, usually on a palliative basis. Like many other workers we have sometimes found this approach to be of great value, the 'palliation' to be curative, and the necrosis of bone not to ensue.

Growths too large for moulds, with evidence of moderate bone invasion, had, until this method of treatment was introduced, been treated by mandibulectomy, and it was in this group of patients that it was felt that irradiation should be attempted.

Table I summarizes the views of a number of authorities. It would appear that a majority favour a radium mould for the superficial growth, high-energy beam or surgery for the intermediate group, and excision for those with extensive bone involvement. Only Martin and Craffey advocate radium needles as the major method of treatment, giving 6,000 to 12,000r in 7 days. Various patterns of implant were used and 8 necroses ensued.

Paterson suggests biplanar implants for lesions in the posterior third, and states that the central dose between the cheek plane and the tongue should not be less than 5,000r and that 7,000r in 7 days is maximum, presumably 0.5 cm. from either plane. One gathers that high-dose effects are not uncommon. Bond and Mansfield suggest a radium mould in combination with implant for growths with spread to cheek or floor of mouth.

We, however, decided upon partial treatment with radium needles, in the form of a biplanar implant, to take advantage of the bone-sparing effect of gamma rays, and partial treatment with X-ray therapy (250 kv., 3.5 mm. Cu HVL) to reduce the inhomogeneity of the implant and hot spots near the bone and to reduce the high dosage needed in the radium-needle implant planes for separations of 2.5 to 3.0 cm.

We have treated 6 patients (Table II) in this way and feel it to be of value. The planar separations varied from 2.0 to 3.5 cm. and the low dose in the centre possibly contributed to bone-sparing effect. No necroses have ensued, and primary control has been achieved in 5 out of 6 cases. One lesion (case 3) was small and perhaps suitable for a mould, but because there was invasion of bone a wider approach was attempted.

We think it is important in this type of treatment to extract any teeth before treatment, rigorously treat any sepsis with antibiotics and irrigations, treat for a total of 4-6 weeks, and give approximately equal contributions (biologically speaking) from the two modalities.

Details are given in Table II.

Two patients are alive and free from disease (cases 1 and 3) and four are dead. Only one had uncon-

TABLE I. TREATMENT OF LOWER ALVEOLUS

Author	Year	Mould	Implant	L VXRT	DXR	HE	Excision
Paterson	1948	Ant.	2/3 Post.				
Cade	1949	Early	No	Early		Large	Late
Ledlie and Harmer	1950					Most	Not stated
Mattick and Meehan	1951	Early		Early			Bone
Martin and Craffey	1952		Yes				
Ackerman and Regato	1954	No	No	Early	Early		Bone, late
Nuttall and Chester-Williams	1955	Early					
Lampe	1955				All		
Bond and Mansfield	1959	Early	Local spread			Large	Bone
Moss	1959	Small	No	Small		Large	Late
Snelling	1959	Early				Large	
Conley	1959						All

L VXRT = low-voltage X-ray therapy. DXR = deep X-ray. HE = high-energy irradiation.

TABLE II. CARCINOMA OF LOWER ALVEOLUS: RADIUM IMPLANT AND X-RAY THERAPY

Case No.	Site	Size (cm.)	Type (infiltrating or papillary)	Bone (erosion on X-ray)	Radium (doses in hundreds of r. in days given)	X-rays	Total time (days)	Fu (months)
1	∪	5×3	I	+	41-33/5	30/22	31	39
2	∪	5×3×2.5	P	—	38/5	25/21	28	D, 24, M2P
3	∪	1.5×1.0	I	+	38-27/5	35/32	40	39
4	∪	5×3×2.0	P	—	42-23/7	17/15	25	D, 39, ?
5	∪	2.5×1.5×1.5	I	+	43-29/5	25/17	28	D, 6, L
6	∪	3.5×2.0×2.0	P	+	30/8	38/20	27	D, 12, M

D = dead, M = metastases, L = local disease, 2P = primary growth, ? = cause of death unknown, no evidence of malignancy.

trolled local disease (case 5); this patient died 6 months after treatment: In case 2 the patient died at 24 months from metastases of a second (pharyngeal) primary cancer, and patient 6 died of neck nodes, having repeatedly refused surgery. In case 4 the patient did not die of oral cancer, but the cause remains unknown. We realize that late necrosis of the jaw can still occur, but feel that this is perhaps unlikely since both surviving patients are edentulous, and should it occur they will have at least retained their jaws for over 3 years. Moreover, those that died, with the exception of case 5, in which a mandibulectomy was followed by recurrence, retained their

jaws until death from other than local disease.

Figs. 1, 2 and 15 refer to case 1, Figs. 3 and 7 to case 2, and Fig. 4 to case 3.

We put this method of treatment forward because, although we have perhaps erred in 'burying radium near bone', it seems to be successful and might be of use to others similarly placed to ourselves. We hope in the not far distant future to have high-energy equipment and therefore will probably abandon this method of treatment, since with the numbers of patients available to us we can never statistically prove our point. Nevertheless, we do feel that we have shown that this method of treatment

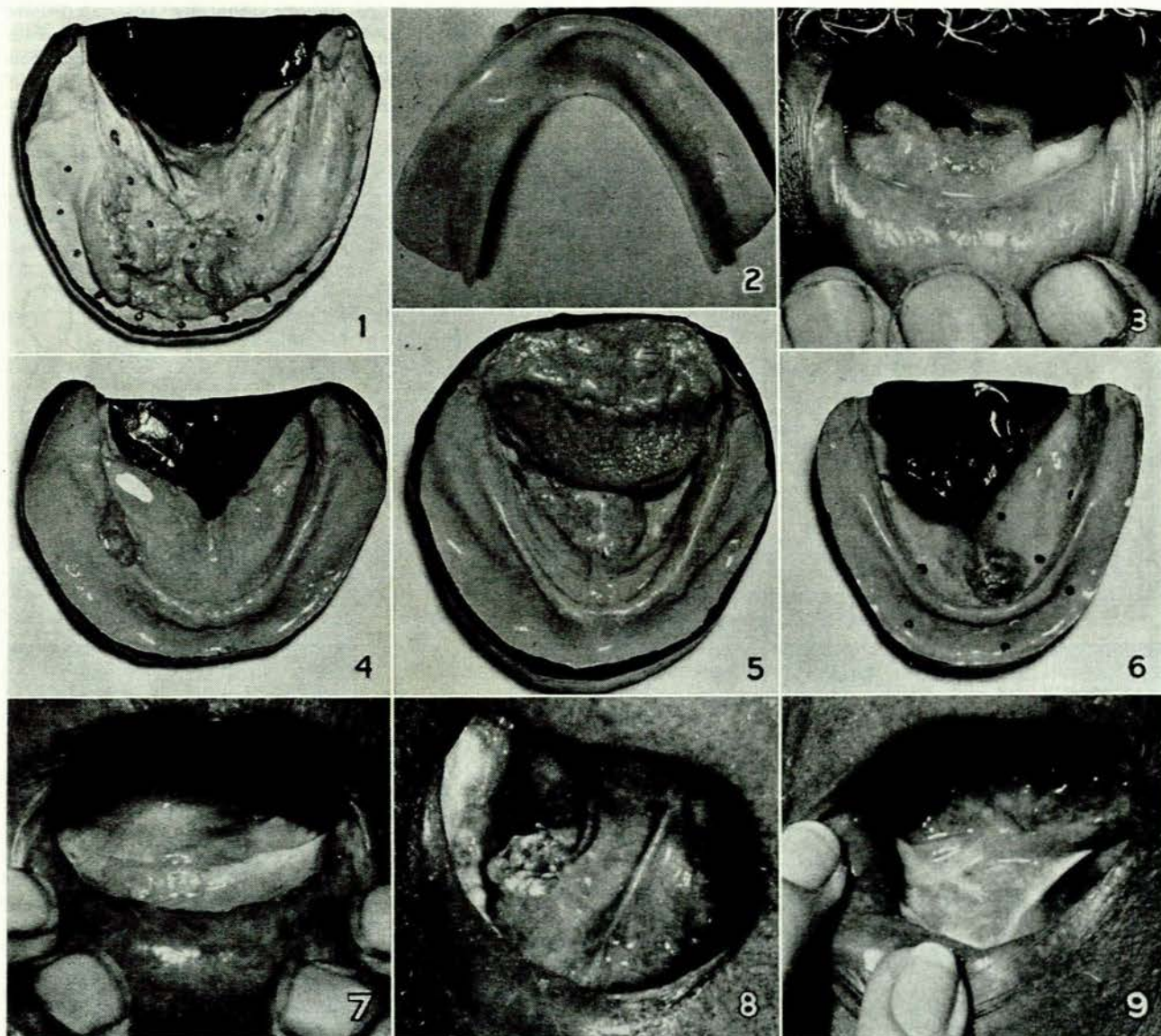


Fig. 1. Carcinoma of lower alveolus. Case 1. Cast of lesion. Plan of radium implant indicated. *Fig. 2.* Carcinoma of lower alveolus. Case 1. Modified denture for bony defect. *Fig. 3.* Carcinoma of lower alveolus. Case 2. Before treatment. *Fig. 4.* Carcinoma of lower alveolus. Case 3. Cast of lesion. *Fig. 5.* Carcinoma of floor of mouth. Case 8. Lesion in posterior position (see text). *Fig. 6.* Carcinoma of floor of mouth. Case 7. Small growth in midline anteriorly, adjacent to gum margin. *Fig. 7.* Carcinoma of lower alveolus. Case 2. After treatment. *Fig. 8.* Carcinoma of floor of mouth. Case 9. Lesion before implant. *Fig. 9.* Carcinoma of floor of mouth. Case 9. Initial healing.

provides a more acceptable alternative than excision, and it also illustrates that the judicious use of the older modalities may in certain circumstances be as effective as high-energy beams.

II. CARCINOMA OF FLOOR OF MOUTH

The floor of the mouth presents rather different problems. Very large lesions, often with invasion upward into tongue, laterally into jaw, or downward into muscle, have been treated palliatively with two opposing X-ray fields. Smaller, posterior, lesions spreading onto the tongue are attacked either with small planned fields or with a radium-needle implant, depending on their exact size and situation. Small growths anteriorly, usually in the midline against the gum margin, have been treated in the standard way with an intra-oral mould and a single supporting X-ray field from below. Case 7 (Fig. 6) shows an exception to this since the growth penetrated deeply and, owing

to cervical spine disease, the patient was unable to extend the head. Treatment by radium implants was successful until death from tuberculosis and carcinoma of the bronchus just over a year later.

There remain a considerable residue of cancers of the floor of the mouth, usually lateral, superficial, flat, and spreading in type. These are best treated by implant, since they are a little too far posterior for intra-oral moulds, which tend to be displaced by the tongue. Case 8 (Fig. 5) provides an example.

Radium needles are often difficult to handle in this site, especially on the inner aspect of the curve of the jaw, and if very short needles (e.g. 1 cm.) are used they tend to fall out. Gold-grain implants are generally advocated here but seem never to turn out quite as intended, and in Cape Town may take several weeks to obtain. For this reason we have turned to tantalum wire, which is pliable, can be kept permanently in stock, and provides a remov-

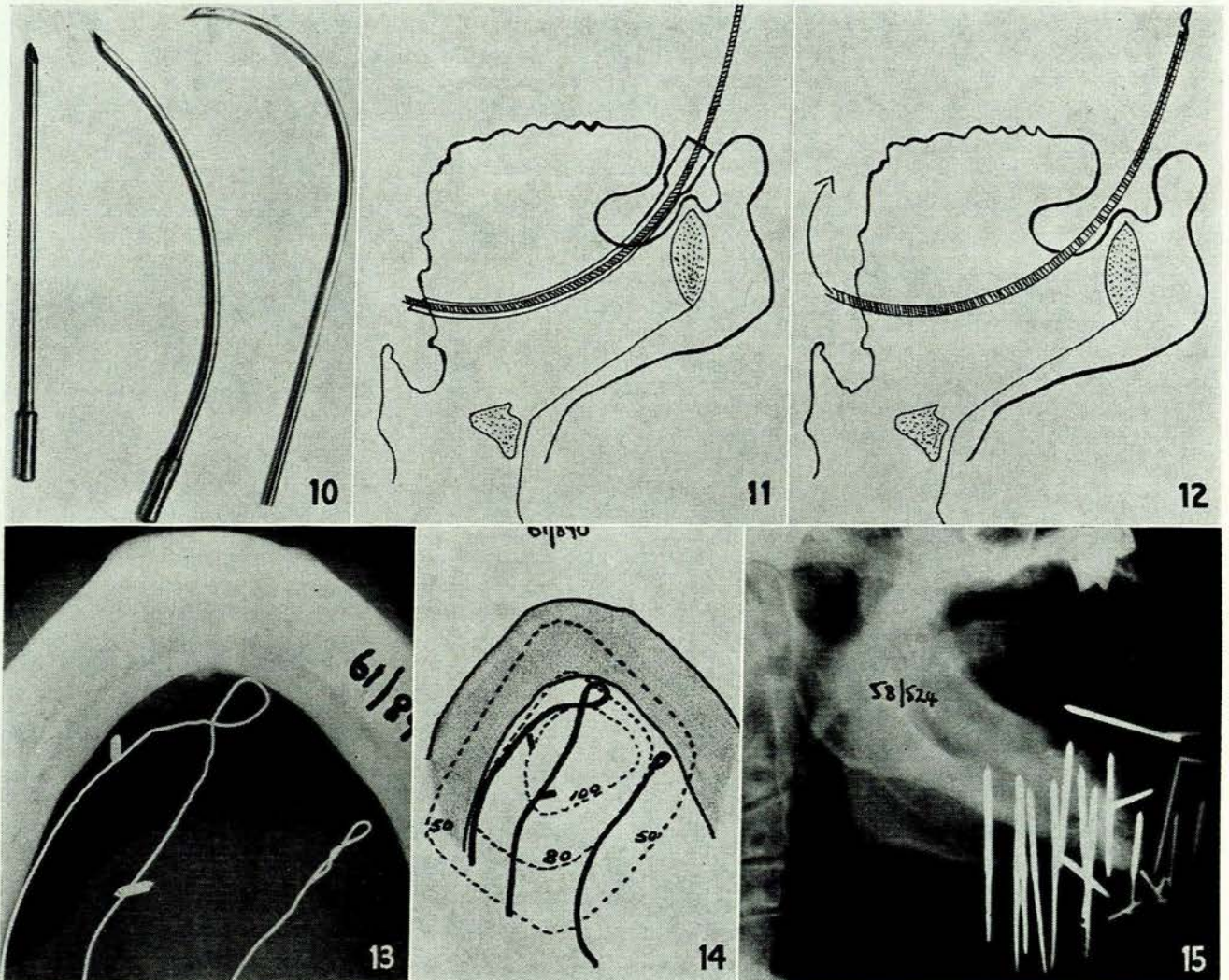


Fig. 10. Tubes for the implanting of ^{182}Ta wire in the treatment of carcinoma of floor of mouth (see text). Figs. 11 and 12. Implantation of ^{182}Ta wire in the treatment of carcinoma of floor of mouth (see text). Fig. 13. Carcinoma of floor of mouth. Case 9. Tantalum wires *in situ*. Fig. 14. Carcinoma of floor of mouth. Case 9. Calculated planar isodose at 0.5 cm. Fig. 15. Carcinoma of lower alveolus. Case 1. X-ray of radium implant.

able implant with all the advantages of control and finite radiation time. The linear activity used has been of the order of 0.8 mg. radium equivalent per cm. and the wire length approximately 5 cm.

The standard bladder introducer is not suitable in this site, because there is no room to manipulate it. We have therefore made needle-pointed stainless-steel tubes (Fig. 10), which can be inserted into the floor of the mouth and threaded with size-O polythene tubing, when the introducer is removed (Fig. 11). This is repeated for each wire it is desired to introduce. Each tube is then after-loaded with a single tantalum wire and pulled through, leaving the wire *in situ* (Fig. 12), to be secured with a single silk suture. The only difficulty is running a wire along the inner curve of the jaw. To do this we have made several surgical needles with screw-ends in place of eyes. The needle is screwed into the polythene tubing (which should not be sterilized by heat) and handled with a needle holder in the usual way.

We have only treated 3 cases within the past year. All have responded with initial healing. The attempted dose was 6,000r in 7 days in each. A specimen case (case 9) is illustrated by Fig. 8 (lesion before implant), Fig. 13 (tantalum wires *in situ*), Fig. 14 (calculated planar isodose at 0.5 cm.), and Fig. 9 (initial healing).

If possible the crossed ends, that is, the loops of the wire, should be placed about 0.75 cm. anterior to the

lesion, and allowances must be made for the uncrossed posterior ends. It is our present practice to mark the lesion with inert radon seeds or gold grains and to determine the individual isodose in each case. We shall probably abandon this after more experience.

It would appear that this method of treatment provides a reasonable alternative to those involving the use of shorter-lived isotopes where great distance from the source of supply presents problems or causes delay.

Thanks are due to Dr. J. G. Burger, Medical Superintendent, and to Prof. J. Muir Grieve for permission to publish these cases. The appliances for tantalum implantation were made by Mr. E. F. Rhategan and the casts of the mouth by the staff of the mould room of the Radiotherapy Department. Photography by the Hospital Photographic Department.

BIBLIOGRAPHY

- Paterson, R. (1948): *Treatment of Malignant Disease with Radium and X-rays*. London: Arnold.
- Cade, Sir Stanford (1949): *Malignant Disease and its Treatment by Radium*, Vol. 11, p. 113. Bristol: Wright.
- Ledlie, E. M. and Harmer, M. H. (1950): *Brit. J. Cancer*, **4**, 6.
- Mattick, W. L. and Meehan, D. J. (1951): *Surgery*, **29**, 249.
- Martin, C. L. and Craffey, E. J. (1952): *Amer. J. Roentgenol.*, **67**, 420.
- Ackerman, L. V. and Regato, J. (1954): *Cancer*. London: Kimpton.
- Nuttall, J. R. and Chester-Williams, F. E. (1955): in *British Practice of Radiotherapy*, p. 273. London: Butterworth.
- Lampe, I. (1955): *Amer. J. Roentgenol.*, **73**, 628.
- Bond, W. H. and Mansfield, O. T. in Kunkler, P. and Rains, A. J. H. eds. (1959): *Treatment of Cancer in Clinical Practice*. p. 263. Edinburgh: Livingstone.
- Moss, W. T. (1959): *Therapeutic Radiology*. St. Louis: Mosby.
- Snelling, M. D. in Raven, R. ed. (1959): *Cancer*, Vol. 5, p. 159. London: Butterworth.
- Conley, J. in Pack, G. T. and Ariel, I. M. eds. (1959): *Treatment of Cancer & Allied Diseases*. Vol. 3, p. 263. New York: Hoeber.