

HORMONAL CYTOLOGY*

DEIDRE MOORE, M.O. & G. (CAPE TOWN), *Cape Town*

The screening test for malignant disease is the best-known application of cytological investigation, and as a result no gynaecological examination is complete without it.

Unfortunately smears taken for screening purposes are rarely suitable for hormonal assessment, being too often obtained by the 'scoop and stir' method. A blind scoop

*Lecture delivered at Karl Bremer Hospital to the South African Society of Obstetricians, Cape Western Branch, on 24 April 1963. This was part of a symposium entitled 'The widening field of vaginal cytology'.

from the cervix or posterior fornix and finally a good hard stir on the slide effectively disrupts normal cellular grouping and morphology. Where smears are required for hormonal evaluation they should be taken from the upper third of the lateral vaginal wall, preferably by aspiration, and spread evenly on a clean slide so as to disturb the natural arrangement of cells as little as possible.

It is important to be extremely careful about the site from which the smear is taken. Smears taken from the lower third of the vagina will show a high percentage of

mature cells. The epithelium of the lower third of the vagina and the ectocervix is much less responsive to hormonal stimulation than that of the middle and upper thirds.

Where vaginal bleeding prevents the collection of satisfactory vaginal smears, cells of the urinary sediment may be examined in the following way:

The urine should be collected immediately after voiding. To 90 ml. of urine 10 ml. of formalin should be added to preserve the cells.

The urine is centrifuged at 200 r.p.m. for 15 minutes and the sediment spread onto slides that have been treated with egg albumin. If this is omitted most of the cells are washed off during the staining process.

The bladder epithelium is less sensitive than the vagina to hormonal influences and this must be taken into account.

Vaginal smears showing evidence of infection with bacteria or trichomonads, with accompanying leukocytosis, are not suitable for hormonal assessment. Infection as such results in varying degrees of cornification which has no relation to hormonal levels. Marked cytolysis with accompanying over-growth of Döderlein's bacillus will also obscure the hormonal picture. While cytolysis is usually found in the luteal stage of the cycle or during pregnancy, it cannot be taken as a reliable measure of progesterone activity. Vaginal infections must be cleared up by appropriate therapy before assessment is attempted. A single antibiotic pessary by destroying Döderlein's bacillus will abolish the cytolytic picture, resulting in occasional massive desquamation of the superficial epithelium.

Smears, when taken, may be stained by either the Papanicolaou or Shorr technique.

If only one fact is known about the hormonal aspect of cytology, it is that the 'cornification index' is a measure of oestrogen activity. It is well known that the action of oestrogens on the vaginal epithelium is to induce proliferation and maturation of the vaginal cells. The mature cells of the vagina are never truly cornified and are more accurately described as eosinophilic cells. The number of these cells occurring per 100 squamous cells is expressed as the eosinophilic or cornification index.

The number of eosinophilic cells in the smear depends to a certain extent on the type of stain used and on its freshness and the staining technique. Many workers prefer to use the 'karyopyknotic index' as their measure of oestrogen activity, since it is less likely to be influenced by these factors. The karyopyknotic index may be defined as the number of superficial cells showing pyknotic nuclei per 100 squamous cells. A pyknotic nucleus is one whose diameter is less than 6 μ . Where the eosinophilic index is found to be high over a count of 3-500 cells one cannot necessarily assume high oestrogen output. Infections, vitamin deficiencies and abnormal metabolic states may alter the picture. Liver disease is a particularly good example, where the breakdown of oestrogens is impaired and a highly cornified smear will result in the absence of much ovarian activity. Genetic factors also play a part and may result in wrong conclusions being drawn, especially about the time of the menopause. Despite these difficulties, the assessment of oestrogen levels by cytology remains fairly

accurate. The same cannot be said of the assessment of progesterone activity.

The effect of progesterone^{1,2} is variable and depends to a large extent on the previous action of oestrogens. Where the vagina is atrophic, progesterone will have very little proliferative effect, but where the epithelium has been primed by oestrogen there will be marked proliferation of the vaginal epithelium with increased desquamation of intermediate cells and a regression of superficial cells. This change is usually seen in the luteal phase of the cycle.

This cytological picture is, however, not specific for progesterone activity and may be simulated by either a drop in oestrogen levels or by an increase in androgens. It is interesting to note that some of the synthetic progestogens appear to have a multihormonal effect and smears show features of both oestrogenic and androgenic action.

Androgens in large doses produce atrophy of the well-proliferated vaginal epithelium. Where the epithelium is atrophic, androgens may actually increase the proliferation of the parabasal and intermediate layers, possibly owing to conversion of some of the androgenic substance to an oestrogen metabolite.

Cortisone has a progesterone-like action in high dosage.

ENDOCRINAL ASPECTS OF GYNAECOLOGY

It is in the endocrinal aspects of everyday gynaecology that cytology has its greatest application. One of the commonest problems in this group is infertility, and here it is of paramount importance to establish the regular occurrence and timing of ovulation. Smears should be taken every 2-3 days for at least 2 months so that the type of ovarian cycle can be observed. It is useful to combine cytological studies with basal temperature recordings and with the estimation of spinnbarkeit.

In the normal cycle, proliferation of epithelial cells commences before the end of menstruation, and there is a steady rise of superficial cells to a maximum just before ovulation. This should occur just before the postovulatory shift in the temperature chart, where the rise is rapid, and during the rise where the postovulatory shift takes 2-3 days (Fig. 1).

After ovulation the cells tend to clump, and intermediate squames replace the superficial cells. The edges of these cells curl and fold and they are referred to as 'navicular' and 'folded' cells. There is also an increase in the number of leukocytes present.

Fig. 1. Pre-ovulatory cornified smear showing cytoplasmic granules.

Fig. 2. Endocervical cells at ovulation showing nuclear tints.

Fig. 3. Enavid smear showing the typical pregnancy changes in the intermediate cells. Note well-marked glycogen deposits.

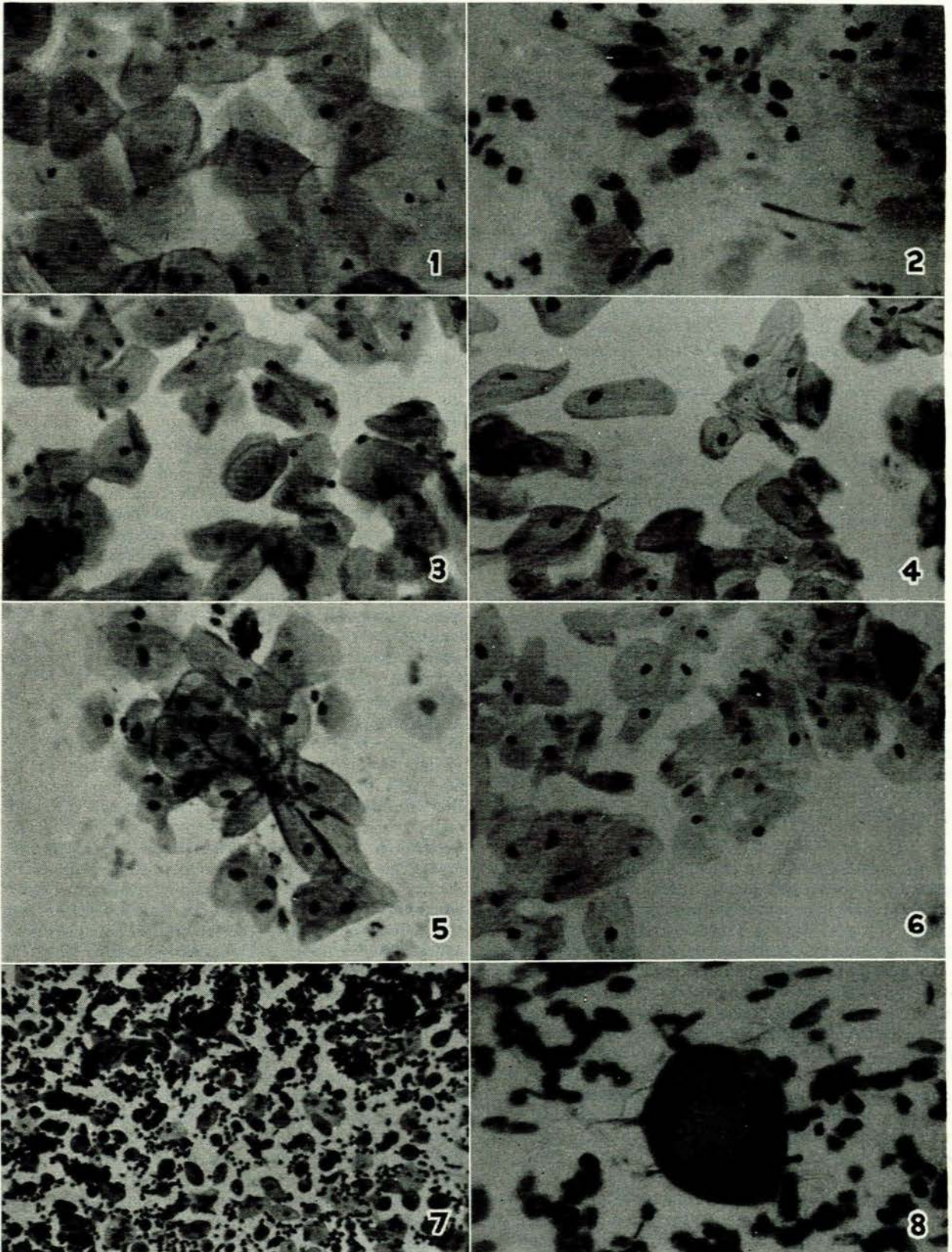
Fig. 4. Pregnancy smear showing 'folding' of intermediate cells.

Fig. 5. Intermediate cells in pregnancy in typical 'rosette' formation.

Fig. 6. Smear taken from day-old baby. Compare with pregnancy smear in Fig. 4.

Fig. 7. Postpartum smear showing an infected atrophic type of smear with parabasal cells and leukocytes.

Fig. 8. Large multinuclear histiocyte from an atrophic postmenopausal smear.



Cells from the endocervix also show cyclical changes although these are not easy to follow. At the time of ovulation the nucleus of the cell produces a small, nipple-like protrusion known as the endocervical-nuclear tit (Fig. 2). This is not always easy to find and it is not of much practical value.

In anovulatory cycles the pre-ovulatory picture of pyknotic eosinophilic squames persists into the second half of the cycle. The nuclei of the intermediate cells tend to become more pyknotic, but no clumping of the cells takes place. Just before menstruation a rapid autolysis of all cell layers takes place. Regression here is due to oestrogen withdrawal and is more rapid than where progesterone is present. This type of picture is sometimes associated with cystic ovaries and high oestrogen levels, but not necessarily with the Stein-Leventhal syndrome.

PRIMARY AMENORRHOEA

The cytological study of the patient with primary amenorrhoea should always include a chromosomal count. The two main conditions showing absence of sex chromatin are the feminizing-testis syndrome and Turner's syndrome (80% of patients).

Aetiology	Cytology	Nuclear sex
1. Gonadal dysgenesis	Markedly atrophic	80% Negative
2. Ovarian eunuchoidism	Markedly atrophic	Positive
3. Pituitary hypogonadism	Atrophic to moderate proliferative	Positive
4. Uterine defect	Proliferative to cycling	Positive
5. Feminizing-testis syndrome	Proliferative, slight to moderate	Negative
6. Congenital adrenal hyperplasia	Atrophic or slight proliferation	Positive

In patients with an inborn uterine defect, absence of the uterus or hypoplasia, normal cycling may be observed in the vaginal smear. In a case of hypoplastic uterus, evidence of vaginal response to exogenous oestrogen administration does not necessarily imply uterine response. The endometrium is much less sensitive to oestrogen stimulation than the vagina.

SECONDARY AMENORRHOEA

Where no pathological cause for secondary amenorrhoea is present, it is not infrequently found to follow psychological trauma with resulting pituitary inhibition. The cytological picture here is variable and may at times be found to correspond to the stage of the cycle in which the trauma took place. Similar findings have been reported from endometrial studies. Though this striking correlation is not found in the commoner, long-standing, stress conditions, the physiological basis remains the same.

In ovarian failure of long standing an atrophic picture is to be expected; however, in the early stages of the menopause a picture indistinguishable from that of pregnancy may be found. It is of interest here to note that pseudocyclosis is accompanied by a smear of the pregnancy type, as is the smear of the patient who has been on 'enavid' (Fig. 3).

Where amenorrhoea is due to persistent oestrus, the smear will show a high cornification level. This type of smear is found in metropathia haemorrhagica, granulosa-

cell tumours and thecomas.

Amenorrhoea with galactorrhoea is found during normal lactation when the smear is of the normal postpartum type. In the Chiari-Frommel syndrome the smear is markedly atrophic, and corresponds to the atrophy of the genital organs. The smears of chromophobe adenoma of the pituitary, which presents with very similar symptoms, rarely exhibits the same degree of cellular atrophy.

Syndromes associated with hirsutism occasionally give rise to difficulties in diagnosis. Here cytology is not very helpful in differentiating the pathological states. While in hirsutism of the simple genetic type normal cycling will be observed in smears, the masculinizing ovarian tumours and the Stein-Leventhal, Cushing and the adrenogenital syndromes give rise to very varied cytological pictures.

From amenorrhoea to precocious puberty, in the constitutional type, normal cycling smears may be observed where ovulation is taking place. Precocious puberty from other causes, e.g. ovarian tumours or intracranial lesions in the region of the fourth ventricle, generally causes a proliferative type of smear.

PREGNANCY

The cytology of pregnancy is both the oldest and the newest branch of the subject. It is the oldest because it was Papanicolaou's early efforts to diagnose pregnancy from the vaginal smear that led to the present application of the cytological method in the diagnosis of malignant and premalignant cervical lesions. Papanicolaou was not successful in his original project, and today it is recognized that in early pregnancy changes are not sufficiently specific for it to be a useful test. The reliability of the method is in the region of 70%, and 10% of false positives can be expected.

The pregnancy smear³ develops gradually from the luteal smear of the second half of the cycle (Fig. 4). During pregnancy there is a marked proliferation of the vaginal epithelium with an increase in cell layers (Fig. 5). The cells themselves fail to reach maturity, resulting in the desquamation of masses of intermediate cells. These cells are rich in glycogen which may be seen as yellow deposits in the cytoplasm. Their edges are folded and the typical pregnancy cell is navicular in shape with increased density at the cytoplasmic border. The nuclei tend to assume an almond or oval shape and are larger than in the non-pregnant cell. The abundance of glycogen encourages the growth of Döderlein's bacillus, which in its turn often brings about massive cytolysis of cells, so that the cytoplasm disappears and only the pale nuclei remain. The incidence of superficial cells falls steadily during normal pregnancy and by the end of the third month the karyopyknotic index has dropped to below 10%. The appearance of the smear at this time may be used for forecasting the outcome of pregnancy. A normal smear with a karyopyknotic index below 10% suggests that the pregnancy will end normally, at term, in 99% of cases. Where the karyopyknotic index remains high there is a 30% chance of an abortion in the absence of treatment. Hormonal, i.e. progesterone, treatment will only be successful in those cases where the cytological picture returns to normal. Progesterone production increases from an esti-

mated 25-50 mg. daily in the first half of pregnancy to 280 mg. in the second half. Initial failure of cytological response to progesterone therapy may be due to inadequate dosage and should be followed by a higher dosage. Where a high karyopyknotic index persists, particularly if it increases, an abortion may be expected. Patients with symptoms of threatened abortion, where the pregnancy smear is satisfactory, will not benefit from progesterone therapy, and some other cause for the abortion must be sought. This test is of considerable value, therefore, in sorting out those patients likely to do well on progesterone. Should syncytial cells be found in the smears of a threatened abortion,⁴ it is a waste of time attempting treatment because placental damage is too extensive to allow the pregnancy to continue. These syncytial cells are actually best looked for in smears from the cervical os rather than the vagina.

Not infrequently the foetus dies during the treatment of a threatened abortion, but is not expelled. Where this is suspected and a pregnancy type of smear is present, the administration of 10 mg. of dienoestrol daily for 3 days will produce a typical oestrogenic epithelial reaction if the foetus is dead. This test can be used at any stage of pregnancy where foetal death is suspected.

The normal pregnancy smear persists more or less unchanged from the third month until just before term. The cytological changes at or about term have been the basis of numerous contradictory articles in the last few years. It has been stated, originally by Pundell,^{5,6} that the pregnancy smear undergoes an abrupt change about 5-7 days before term to what he calls the 'at term smear'. This is characterized by an exfoliation of cells with diminished clumping and an increase in the number of intermediate cells with flat edges. The appearance of this type of smear presages delivery within 7 days in 90% of cases. The persistence of this 'at term smear' beyond the chronologically expected date of delivery, is evidence of postmaturity and an indication for induction of labour. Where the smear is still of the pregnancy type at chronological term it is deduced that biological term has not yet been reached and no indication for termination exists.

The appearance of basal cells and a rise in the karyopyknotic index towards the end of pregnancy indicates a degree of placental insufficiency. This type of smear is most commonly seen in toxæmia of pregnancy. Independent observers⁷ have recorded that where induction of labour is undertaken for obstetrical indications, the induction-delivery interval is least where the at term picture has been present for less than a week. The induction-delivery interval is greatest where the 'prior to term' smear is present. This then is a useful way of determining the optimum time for induction of labour.

It is interesting to observe that vaginal smears taken from the newborn accurately reflect the hormonal level of their mothers (Fig. 6). The smears are not, as is so often stated, cornified, but of the pregnancy or at term type, with a predominance of navicular and folded cells. As the child gets older the number of cells decreases, and an increasingly atrophic cell picture gradually emerges.

After parturition the vaginal smear again undergoes an abrupt change (Fig. 7). It is heavily blood-stained for

the first three days with masses of leukocytes and histiocytes. The intermediate cells disappear to be replaced by a particular type of basal cell with a well-formed, partly pyknotic nucleus and vacuolated, blueish cytoplasm. This type of cell is usually found only in the first 10 days; it gradually becomes more like the normal type of parabasal cell, and the smear is atrophic in type. This picture will persist during lactation and the postpartum period, and gradually merges into the normal pre-ovulatory smear when regular ovarian function is resumed.

MENOPAUSE

At the menopause vaginal cytology is, of course, extremely varied depending on the degree of ovarian atrophy that has taken place.

In the early stages there is a diminution of superficial squames, and the nuclei of the intermediate cells tend to be larger and more vesicular. As ovarian activity decreases so the number of superficial cells decreases and thick clusters of intermediate and parabasal cells make their appearance. Glycogen deposits are frequent in the cytoplasm and the smear may closely resemble that of pregnancy. To many patients periods of amenorrhoea at the time of the menopause are a great source of worry—the 'change of life' baby is a much dreaded event. While these two conditions cannot always be differentiated cytologically, it is always possible to induce an oestrogen response in the absence of pregnancy.

The gradually increasing atrophy of the genital tract results finally in the true atrophic smear. The cell types here are mainly parabasal cells showing some enlargement, and with an enlarged and degenerate type of nucleus eosinophilic staining of the cytoplasm is present at times. Filaments of blue-staining nuclear material are common and should not be mistaken for degenerate spermatozoa, which they superficially resemble, lest the wrong impression be gained of the patient. Multinuclear histiocytes are also fairly common and do not indicate malignancy (Fig 8).

Any smear showing a high eosinophilic index after the menopause must be carefully evaluated. It is known that malignant disease, particularly of the genital organs and breast, is often associated with a high cornification index—in fact it is rare to find malignant cells in a completely atrophic smear. Possibly the commonest cause for a high cornification index is the use of oestrogens either known or unknown by the patient. Any medication the patient is receiving must be identified to exclude this possibility, and this includes many facial and wrinkle creams.

While many of the finer points of the hormonal aspects of cytology are yet to be evaluated, it remains a useful, inexpensive and easily applied tool in the elucidation of many of the common aberrations encountered in the average gynaecological practice.

I wish to thank Mr. Duncan Middleton for the trouble he took with the photographs.

REFERENCES

1. Rakoff, A. E. (1961): *Acta Cytol. (Philad.)*, 5, 153.
2. Del Sol, J. R. and Rohrbach, C. (1962): *Ibid.*, 6, 278.
3. Von Haam, E. (1961): *Ibid.*, 5, 320.
4. Fayed, M. M. and Youssel, A. F. (1963): *J. Obstet. Gynaec. Brit. Emp.*, 70, 39.
5. Pundel, H. (1959): *Acta Cytol. (Philad.)*, 3, 253.
6. *Idem* (1962): *Ibid.*, 6, 359.
7. Leeton, J. F. (1963): *J. Obstet. Gynaec. Brit. Emp.*, 70, 46.