

LEFT UPPER-ABDOMINAL DIAGNOSTIC PNEUMOPERITONEUM AN ILLUSTRATIVE CASE

P. D. DE VILLIERS, *Diagnostic Radiologist, Lister Buildings, Johannesburg*

The introduction of gas into the peritoneal cavity as an aid to the diagnosis of upper-abdominal conditions is often impressive. I feel very strongly that the method should be used far more frequently. The conditions in which I have personally used it include diaphragmatic defects, obscure lesions in the stomach wall, and upper abdominal masses generally.

Case Report

Fig. 1 shows the result of a barium-meal examination of a girl aged 11 years, under investigation for the cause of upper abdominal pain. There is an indentation on the upper part of the lesser gastric curve. Is the mass in the stomach wall? What is its relation to other upper-

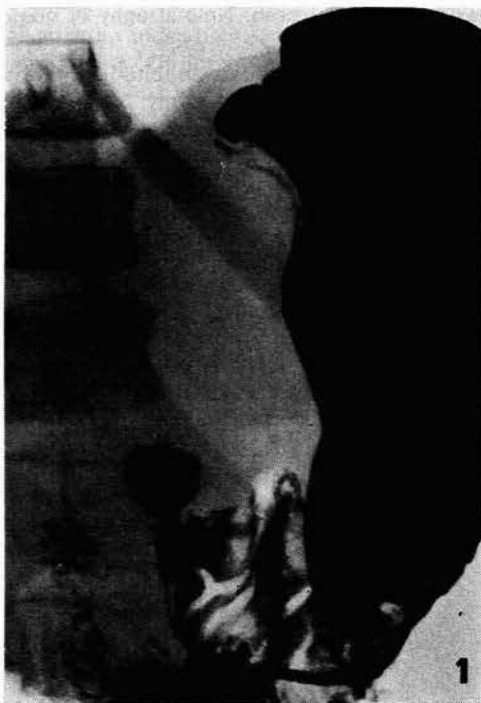

Fig. 1. See text.

abdominal organs? Could the appearance be produced, for instance, by pancreas or liver? It was felt that a diagnostic pneumoperitoneum would be eminently suitable here.

Fig. 2, during injection of gas into the peritoneal cavity (note the needle shadow over the lower abdomen on the left side), shows the mass separated from spleen, kidney, diaphragm and probably liver.

Figs. 3 and 4 show that barium has been introduced into the stomach, and microtrast into the oesophagus. The relationship of the mass to the stomach and oesophagus is seen.

Technique of Diagnostic Pneumoperitoneum

Every operator will evolve his own method of inducing a pneumoperitoneum, suited to his needs and experience. The examination is simple, harmless and relatively pain-

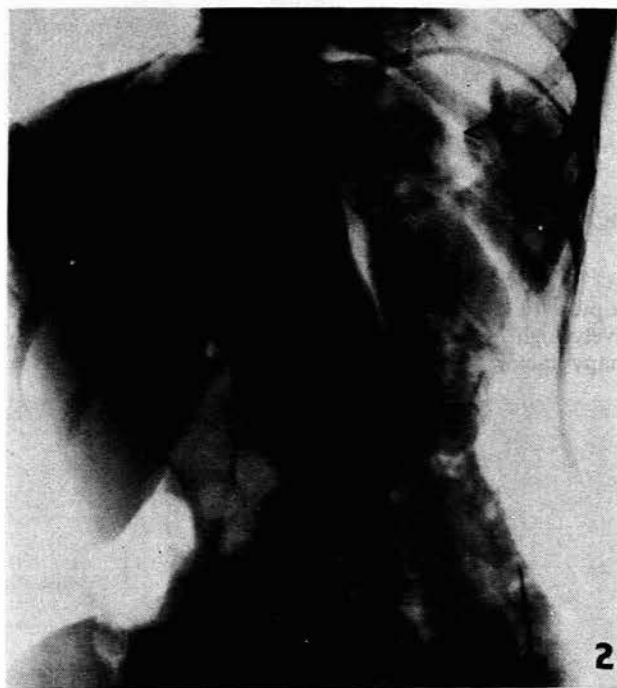


Fig. 2. See text.

less. Personally, I prefer to use nitrous oxide, because it is so soluble that it minimizes the risk of gas embolism if it is inadvertently injected into a blood vessel, and also because it is absorbed rapidly. For convenience I prefer to use an anaesthetic machine to supply the gas. The amount of gas required varies, but will be enough to produce visible distension of the abdomen and loss of liver-dullness to percussion. The most instructive films are often those exposed under screen control, with the table tilted head up by some 30 degrees, in supine, prone and oblique projections.

Operation

In this child no abnormality was apparent when the abdomen was first opened. Because the mass had been clearly seen radiologically, however, the lesser sac was opened. Further dissection revealed a removable cyst in the stomach wall.

The patient reported on in this illustrative paper was referred by Mr. R. Fleming.