

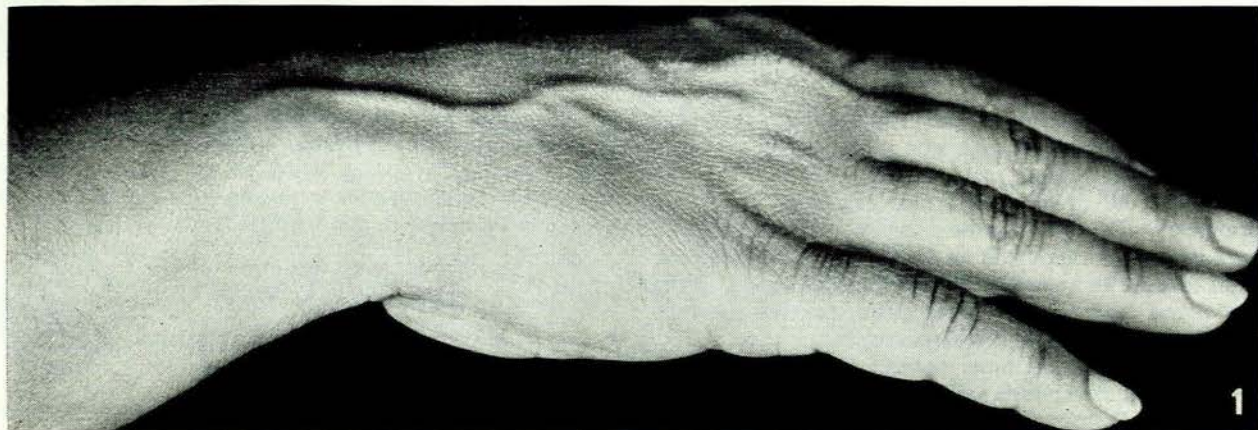## TENOvagINITIS OF THE EXTENSOR CARPI ULNARIS

L. SOLOMON, M.D. (CAPE TOWN), F.R.C.S. (ENG. and EDIN.), *Royal National Orthopaedic Hospital, London*

Chronic tenovaginitis is well known in its usual form affecting the tendons of abductor pollicis longus and extensor pollicis brevis at the radial border of the wrist. The same condition occurring in less usual sites, however, is

often not recognized and it is common to find a diagnosis of 'sprain' of the ankle or wrist in such cases.

This paper describes the findings in 5 cases of chronic tenovaginitis of the extensor carpi ulnaris. They had all



*Fig. 1.* Case 1. Swelling of the tendon sheath of extensor carpi ulnaris.

attended the orthopaedic outpatient department because of pain in the wrist following minor injury, which failed to respond to simple physiotherapy or rest. Two patients were operated on and provided material for histological examination.

#### CASE REPORTS

##### Case 1

A housewife, aged 40 years, struck the ulnar border of her right wrist on the side of a table. Not unexpectedly, she had pain over the ulnar styloid process, but when this failed to subside during the next 3 months she was sent to hospital.

Examination showed a small, but clearly visible, swelling over the tendon of extensor carpi ulnaris just distal to the head of the ulna, tender on pressure and painful on resisted active extension of the wrist (Fig. 1).

A diagnosis of tenovaginitis of extensor carpi ulnaris was made and 25 mg. of hydrocortisone acetate were injected into the tense sheath at the wrist. Two weeks later she pronounced herself 'cured' and she has had no recurrence in 2 years.

##### Case 2

A girl aged 17, soon after starting to train as a typist, suffered pain and swelling over the radial styloid at the left wrist. De Quervain's disease was diagnosed and she was treated by injection of hydrocortisone and immobilization in plaster. After several recurrences the sheath of extensor pollicis brevis and abductor pollicis longus was incised, giving complete and lasting relief. Thirteen months later, she returned with pain at the ulnar border of the wrist and 'numbness' along the ulnar border of the hand. Pain was aggravated by extension and ulnar deviation of the wrist. There was slight thickening over the ulnar styloid process and marked tenderness over the tendon of extensor carpi ulnaris. There was no objective loss of sensibility.

A diagnosis of tenovaginitis of the extensor carpi ulnaris was made. The sheath was injected with 25 mg. of hydrocortisone acetate and the wrist immobilized for 2 weeks. On resuming typing the pain recurred with even greater intensity. Three months after the injection the sheath was divided longitudinally. There was little thickening but the tissues were oedematous and abnormally vascular. Histological examination showed numerous clumps of round cells in the subsynovial layers (Fig. 2).

After operation she had complete relief for several months. There was then a recurrence of pain, which later subsided spontaneously. Two years after operation she still had slight discomfort over the ulnar border of the wrist.

##### Case 3

A schoolgirl aged 16 sustained a hyperextension injury of her right wrist during gymnastics. When the initial pain subsided she resumed normal activity. Six weeks later, however, she developed increasing pain at the medial border of the wrist, diagnosed as a 'sprain' and treated by immobilization in plaster for 4 weeks. She was completely relieved, but a month later the pain recurred. Hydrocortisone acetate (25 mg.) was injected into the medial side of the wrist, again with temporary success.

At this stage it was observed that the greatest tenderness was situated just distal to the head of the ulna and that the sheath of extensor carpi ulnaris was slightly swollen. This was exposed at operation and divided. A narrow strip was taken for histological examination. Microscopically there was thickening of the fibrous sheath but no evidence of inflammation or any other abnormality.

Eighteen months later pain had not recurred.

##### Case 4

A housewife, aged 55, suffered pain at the ulnar border of the right wrist, passing up the forearm for a distance of 3 or 4 inches. Pain was aggravated by twisting movements of the wrist or by active extension and ulnar deviation. On examina-

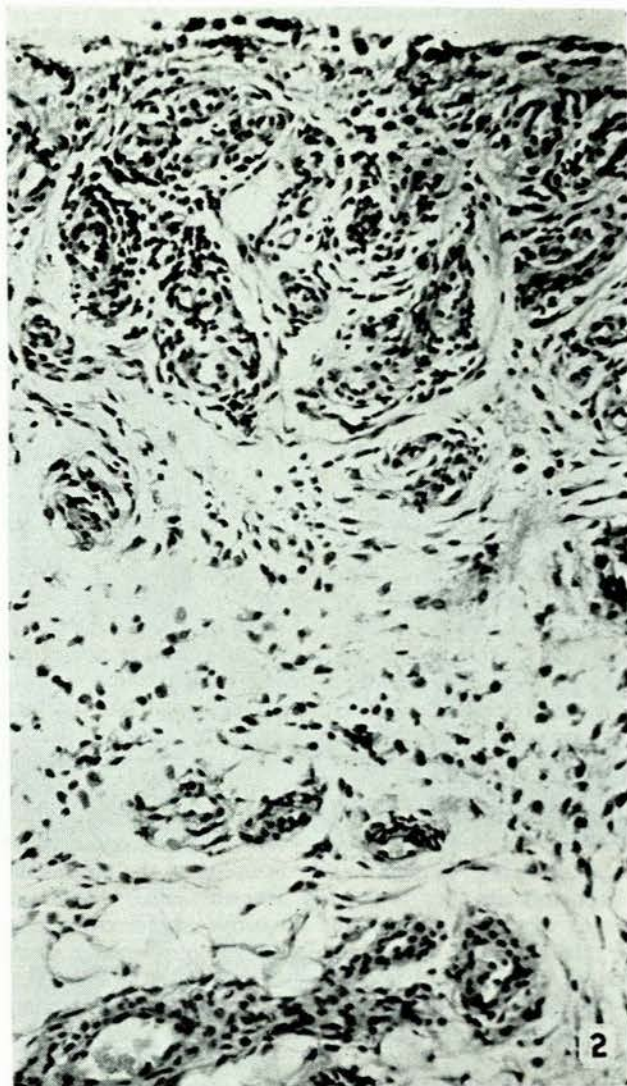


Fig. 2. Case 2. Round-cell infiltration in the subsynovial layer of the tendon sheath.

tion there was a visible swelling about 1 cm. long, just distal to the head of the ulna, corresponding to the point of greatest tenderness.

Tenovaginitis of the extensor carpi ulnaris was diagnosed and 25 mg. of hydrocortisone acetate injected into the tendon sheath at the wrist. A week later she was free of pain and she has had no recurrence in 2 years.

##### Case 5

A man, aged 47, after a day of tennis at the start of the season, complained of pain in the right wrist, particularly at the ulnar styloid. Tenderness at this point was ascribed to an injury to the medial ligament of the wrist. Hydrocortisone acetate was injected and the pain subsided. Though he continued to have some discomfort he resumed normal activity.

A year later, again at the start of the tennis season, the pain recurred. Examination showed a slight swelling just distal to the head of the ulna, with tenderness on pressure over the extensor carpi ulnaris tendon. A diagnosis of tenovaginitis was made and 25 mg. of hydrocortisone acetate injected into the tendon sheath. Pain was completely relieved and he has been able to play tennis without discomfort ever since.

## DISCUSSION

*Anatomy*

The medial attachment of the extensor retinaculum at the wrist is to the styloid process of the ulna proximally and the triquetral bone distally. Between these two points the tendon of extensor carpi ulnaris crosses the wrist in its own fibro-osseous compartment, lying in the groove between the styloid process and the head of the ulna. It is inserted into the base of the fifth metacarpal.

Acting by itself it produces ulnar deviation of the wrist and hand. It is also a powerful extensor and helps to stabilize the wrist during movements of the hand.

With the forearm pronated the most prominent feature on the back of the wrist is the head of the ulna. In full supination, it is the styloid process that stands out as the radius rotates around the head. At about 15° of supination these two bony points are the least conspicuous and the tendon of extensor carpi ulnaris can be easily palpated between them.

*Clinical Features*

The tendon sheath of extensor carpi ulnaris is one of the less common sites of chronic tenovaginitis, yet it would be diagnosed more often if it were kept in mind as a cause of pain at the ulnar border of the wrist following an injury or repeated hyperextension strain.

As with other forms of tenovaginitis most of the patients are women (Lapidus and Fenton<sup>1</sup>). There is almost always a history of injury—either direct trauma or a twisting strain—followed by pain along the inner side of the wrist which fails to subside in the expected way. The pain is more or less constant, though worse after activity and easier after rest. It may be felt diffusely up the ulnar side of the forearm, but is greatest over the ulnar styloid. In one of these cases there was subjective 'numbness' along the ulnar border of the hand, a symptom encountered, too, by Dickson and Luckey.<sup>2</sup>

The swelling, when present, is situated over the tendon of extensor carpi ulnaris just medial and distal to the head of the ulna (Fig. 1). This also corresponds to the point of maximum tenderness, which should be accurately distinguished from the ligament of the wrist joint more medially and the radio-ulnar joint more laterally. There may be limitation of all movements at the wrist.

*Differential Diagnosis*

The common error is to call the condition a 'sprained medial ligament of the wrist'. A comparatively mild injury preceding the pain, the chronicity of the symptoms, and tenderness limited to the dorsum of the wrist, are against this diagnosis. A tear of the medial ligament is

usually the result of a severe injury and may cause considerable swelling and bruising.

More difficult to exclude is a tear of the articular disc at the wrist, which may follow a twisting injury of the joint. Forceful rotation of the wrist produces pain and, sometimes, a characteristic click in the joint. The point of greatest tenderness is usually over the radio-ulnar joint.

Tenovaginitis of extensor digiti minimi resembles that of extensor carpi ulnaris in all respects except that the tenderness is on the radial side of the ulnar head over the fifth compartment of the extensor retinaculum.

Other local conditions causing pain at the inner side of the wrist, but generally easily diagnosed either clinically or radiologically, are fracture of the ulnar styloid, subluxation of the distal radio-ulnar joint, bone lesions at the distal end of the ulna, osteoarthritis of the wrist, and the ubiquitous ganglion.

*Treatment*

Tenovaginitis of extensor carpi ulnaris appears to respond to the same treatment as the corresponding condition elsewhere. All the cases were improved, temporarily, by rest. Three had lasting relief after injection of hydrocortisone acetate into the synovial sheath at the wrist. The other two required division of the fibrous sheath.

## SUMMARY

Although it is well known that tenovaginitis may affect any of the sheaths around the ankle or wrist, this condition may readily be overlooked when it occurs in any of the less usual sites.

Five cases of tenovaginitis of extensor carpi ulnaris are described. In all but one there was a history of mild trauma and a diagnosis of 'sprained wrist' had been made in 3 of the cases.

The clinical features distinguishing this from other painful conditions of the wrist are discussed.

In the early stages the condition can usually be cured by injecting hydrocortisone acetate into the synovial sheath, though occasionally division of the sheath is required.

I wish to thank Mr. P. H. Newman, Mr. D. Trevor and Mr. J. N. Wilson for allowing me to publish these case histories. I am also grateful to Mr. J. N. Wilson and Mr. H. Jackson Burrows for their helpful criticism of the paper.

Fig. 1 was produced by Mr. R. J. Whitley of the photographic department and Fig. 2 by Dr. P. Byers of the morbid-anatomy department of the Institute of Orthopaedics. I am grateful to them for their assistance.

## REFERENCES

1. Lapidus, P. W. and Fenton, R. (1952): *Arch. Surg.*, **64**, 475.
2. Dickson, D. D. and Luckey, C. A. (1948): *J. Bone Jt Surg.*, **30A**, 903.