

AMOEBC VAGINITIS

HERMAN A. VAN COEVEDEN DE GROOT, M.B., CH.B., Registrar, Division of Obstetrics and Gynaecology,
University of Cape Town and Cape Provincial Administration

Amoebic vaginitis is a rare though well-recognized form of amoebic infestation of the human female. In 1928 - 1929 Dr. Carl G. Hartman discovered amoebae, morphologically indistinguishable from *Endolimax nana*, in vaginal washings from certain Rhesus monkeys during experiments. This appears to be the first time amoebae of any kind have been reported from this site.⁸

Since then, sporadic reports have appeared, mostly from China, India, the former Dutch East-Indies, Egypt and America. Weinstein and Weed,¹⁴ reviewing the literature until 1946, were able to find only 10 cases to which they added 4 of their own collected over a period of 9 months. Bhoumik² stated that by 1951 about 20 cases of amoebic infestation had been described, 18 of which had vaginal lesions. The exact number of cases reported by the end of 1961 is difficult to calculate, but is estimated as between 40 and 50. As far as can be ascertained the only case reported from South Africa was by Garin.⁷ Several writers have emphasized the importance of routine search for amoebae in vaginal discharges. Bhaduri¹ found 14 cases of genital amoebiasis in a series of 123 patients with leucorrhoea in Calcutta. Bickers³ detected 1 case in a similar series of 200 patients. A few authors describe secondary invasion of carcinoma of the cervix uteri by *Entamoeba histolytica*.^{4,5,10}

There is almost always a history of past or present dysentery, and amoebae can usually be detected in the stools. The presenting features are a profuse purulent or sanguinous vaginal discharge and often severe pain. The condition is usually mistaken for advanced carcinoma of the vulva, vagina or cervix. This illustrates the obvious necessity for insisting on histological proof before starting therapy in every case of suspected carcinoma.

CASE REPORT

M.M., a Coloured female aged 48, attended the gynaecological outpatient department, Groote Schuur Hospital, on 26 March 1962, complaining of a profuse watery discharge for the past 2 weeks. For the past week the discharge had become bloody. She was in great pain and had very marked dysuria with some frequency. In June 1958 the patient had a total abdominal hysterectomy for fibroids and menorrhagia. Histological examination had confirmed the presence of fibroids and showed a few dilated glands filled with secretion in the cervix. There was no evidence of malignancy. Until 2 weeks before her present visit she had been perfectly well. She had not bled vaginally since the operation. She had never been pregnant. There were no further relevant features in the past history.

Examination revealed an obese, well-looking female in

obvious pain. General examination showed no abnormalities. The haemoglobin was 12.5 G. per 100 ml. The vagina was filled with a necrotic slough appearing at the vulva. The vulva itself showed no lesions. Speculum examination was impossible owing to extreme tenderness. Vaginal examination was unsatisfactory, but showed the slough to fill the whole length of the vagina (Fig. 1).

The patient was admitted with the diagnosis of carcinoma of the vagina and a snip was taken from just inside the introitus for histological examination. As there seemed to be no doubt about the diagnosis, routine investigations for genital carcinoma were started; these included a Wassermann test, blood-urea estimations, a skeletal survey, chest X-ray, intravenous pyelogram, and cystoscopy. The histological report by Dr. J. A. H. Campbell read as follows:

'Histology shows an intact surface epithelium with an intense underlying acute inflammatory reaction. In this inflammatory response are many amoebae and though the abundant polymorphs are unusual in an amoebic lesion one feels that this is, nevertheless, the diagnosis in this case.' (Fig. 2.)

Several warm stools were then examined, but no amoebae found. Sigmoidoscopy to 21 cm. was entirely normal. A random biopsy taken showed normal colonic mucosa on histological examination with melanosis coli, and no amoebae were observed. On 5 April the patient was examined under anaesthesia. After removal of the vaginal slough the whole underlying mucosa was fiery red and bleeding. No ulcers or other lesions were seen. Several biopsies were taken which showed histologically 'extensive superficial necrosis showing the pronounced autolysis so characteristic of amoebiasis. In areas numerous amoebae were demonstrated'. A vaginal swab was taken at this time and showed vegetative forms of *Entamoeba histolytica*. Microscopic examination of *Entamoeba histolytica* showed ingested red corpuscles and exudate containing numerous pus cells (Fig. 3).

Treatment consisted of: Emetine, gr. 1 daily, intramuscularly for 10 days; diiodoquin, 9 gr. t.d.s., orally for 21 days; and achromycin, 500 mg. 6-hourly, orally for 6 days.

The patient was kept strictly in bed. After a few days the pain disappeared and the discharge became less. After little more than a week the discharge had cleared up. On 9 May the patient was re-admitted for a check-up. She was symptom-free, and there was no vaginal discharge. A barium enema proved normal. Repeat swabs were negative. The vagina was stenosed from about 1 inch from the introitus. These adhesions were separated under general anaesthesia, and the patient instructed in the use of vaginal dilators.

On 30 July the patient was seen again. She had not continued with dilatation of the vagina. She felt quite healthy and though the vagina only admitted one finger for a distance of about 5 cm., no further therapy was contemplated. The patient is separated from her husband and is not considering remarriage.

DISCUSSION

This case is unusual in several respects. As has been stated, most patients have a history of dysentery. Careful

(Byvoegsel — Suid-Afrikaanse Tydskrif vir Obstetrie en Ginekologie)

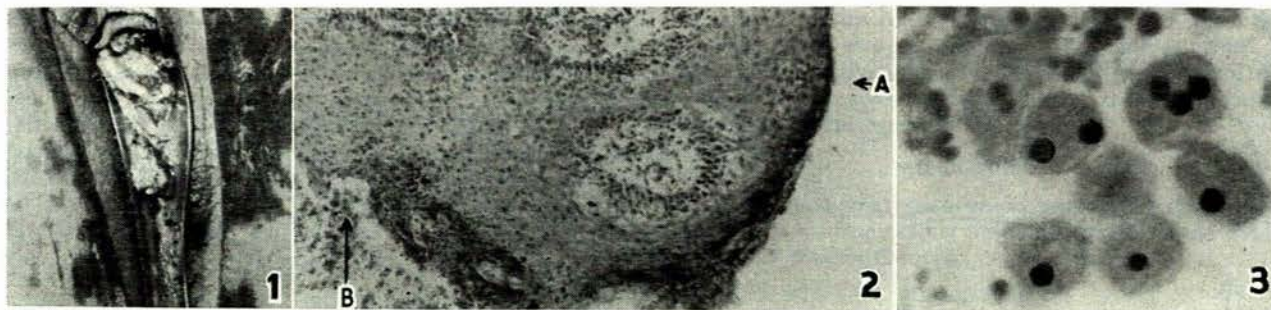


Fig. 1. Slough pouring out of vagina following insertion of speculum.

Fig. 2. Biopsy of vagina. A = intact epithelium, B = amoebae.

Fig. 3. High power magnification ($\times 1,000$) of *Entamoeba histolytica* showing ingested red blood corpuscles and exudate containing numerous pus cells.

questioning could not elicit such a history in this patient. She has lived in the Cape Peninsula all her life. No fistulous communication between rectum or colon and the vagina was found. She had not had intercourse for a number of years.

In all the cases reported in the literature the patients had one or more discrete ulcers on the vulva, vagina or cervix. This appears to be the first case of diffuse amoebic vaginitis involving the whole length of the vaginal mucosa without ulceration. This may be due to the fact that the lesion had only been present for a few weeks before treatment was begun. Usually the history is of many months before a doctor is consulted.

The pathogenesis of the condition in this case remains obscure.

SUMMARY

A case of diffuse amoebic vaginitis of unknown pathogenesis is reported. Several unusual features are mentioned. The importance of histological diagnosis before starting treatment in every case of suspected carcinoma of the female genital tract is well illustrated by this rare condition.

OPSOMMING

'n Geval van amebiase van die skede word beskryf. Verskillende ongewone bevindings word bespreek. Die oorsaak

van die letsel in hierdie geval bly onbekend. Die seldsame geval beklemtoon die absolute noodsaaklikheid van mikroskopiese diagnose voordat met die behandeling van 'n klinies-vanselfsprekende geval van karsinoom van die vroulike geslagsdele begin word.

I should like to thank Prof. James T. Louw and Dr. P. J. Massey for their interest and help, Drs. C. J. Uys, J. A. H. Campbell and C. E. Watson from the Department of Pathology for their kind cooperation, and Messrs. Todt and Middleton for the photographs. I am also indebted to Dr. J. G. Burger, Medical Superintendent of Groote Schuur Hospital, for permission to publish.

REFERENCES

1. Bhaduri, K. P. (1957): *Amer. J. Obstet. Gynec.*, **74**, 434.
2. Bhoumik, A. (1951): *Indian Med. Gaz.*, **86**, 355.
3. Beckers, W. (1943): *Virginia Med. Mth.*, **70**, 135.
4. Carter, B. *et al.* (1954): *Amer. J. Obstet. Gynec.*, **68**, 1607.
5. Cleland, J. B. (1944): *J. Trop. Med. Hyg.*, **47**, 54.
6. Elsdon-Dew, R. (1962): Personal communication.
7. Garin, H. (1947): *S.Afr. Med. J.*, **21**, 32.
8. Hegner, R. (1930): *J. Parasit.*, **16**, 91.
9. Heilbrunn, A. (1949): *Ned. T. Geneesk.*, **93**, 3268.
10. Lee, S. W. (1932): *Chin. Med. J.*, **46**, 1096.
11. May, M. Y. (1943): *Indian Med. Gaz.*, **78**, 250.
12. Moghraby, A. S. (1960): *J. Obstet. Gynaec. Brit. Emp.*, **67**, 332.
13. Sen, N. C. (1949): *Brit. Med. J.*, **1**, 808.
14. Weinstein, B. B. and Weed, J. C. (1948): *Amer. J. Obstet. Gynec.*, **56**, 180.