

# A CASE OF SELF-MUTILATION BY MEANS OF PINS

B. PARKER, M.B., CH.B., *Oranje Hospital, Bloemfontein\**

Elizabeth B. is a 37-year-old White imbecile, an inmate of Witrand Institution, Potchefstroom. She has contractures of her knees and a paretic left upper limb.

From 1952 onwards, her folder contains frequent notes about superficial areas of inflammation, e.g. 'multiple boils', 'cellulitis', 'furunculosis', etc. As witness to this, she has numerous scars on many parts of her body. In December 1962 she developed an inflammatory swelling of her left forearm.

On X-ray examination her forearm was seen to contain 21 pins (Fig. 1). Subsequently, the rest of her body was X-rayed, revealing 202 foreign bodies in her tissues. Most appeared to be pins, of which the heads had been broken off, but sewing-machine needles, darning needles, and pieces of wire were also present. These objects were seen

in both lower limbs, buttocks, left upper limb, neck, face, breasts, and within the thoracic cavity (Fig. 2).

The patient herself, on account of her partial paralysis, is unable to search for pins where they are likely to be found. It has been discovered that several other imbecile patients have made a practice of collecting sharp objects and presenting these to the patient. One was discovered in the act of taking a cigarette-box to her filled with rusty nails.

There is no doubt that the patient herself introduced the pins, since she is well able to defend herself against attack by others, and her sound arm is conspicuously free of pins.

When accused of having pushed pins through her skin, the patient denied it, and was quite unruffled. She became very angry when a superficially situated pin was removed under local anaesthesia. She reacts normally to painful stimuli administered by other people.

\* Previously of Witrand Institution, Potchefstroom

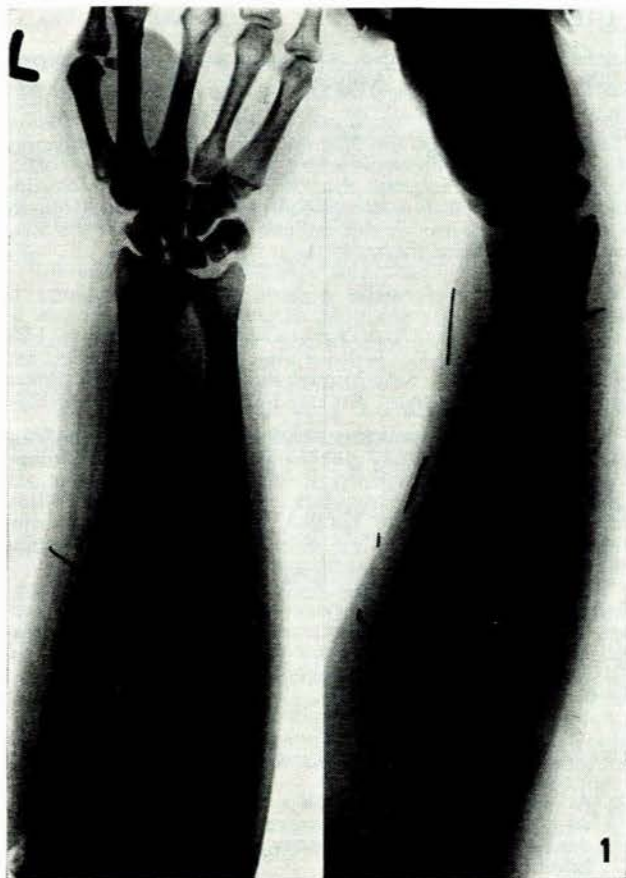


Fig. 1. Left forearm. Note erosion of the ulna by the point of a pin.

It is remarkable that, in spite of the frequency with which suppuration occurred, she was never noted to have discharged a foreign body from an abscess. In all cases the pins have remained *in situ* and caused no further harm.

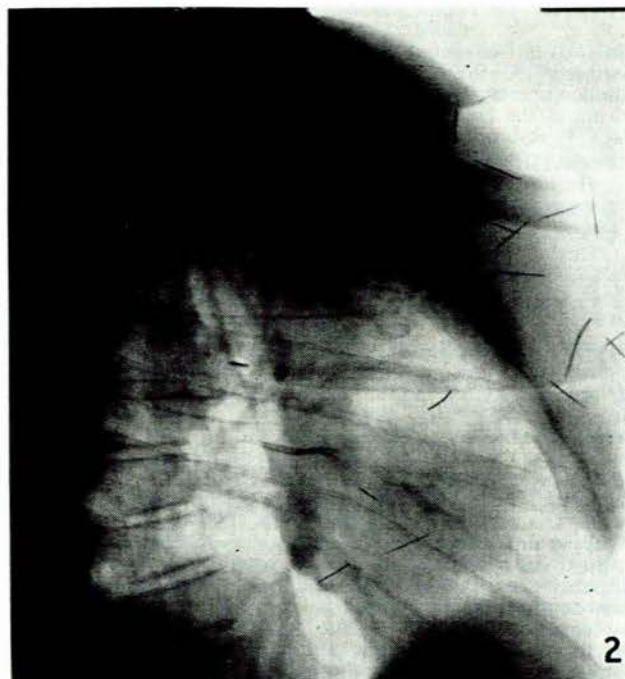


Fig. 2. Lateral view of the chest. Note the piece of wire which has moved with systole. An antero-posterior view of the chest shows that this is in the left lung, adjacent to the heart.

#### SUMMARY

A short report is given of the case of an imbecile who has repeatedly introduced pins into her tissues. Altogether 202 foreign bodies were revealed by X-ray examination.

I wish to thank the Commissioner for Mental Health and the Superintendent of Witrand Institution for permission to report this case.