

THE DANGERS OF ADMINISTERING STEROIDS TO PATIENTS SUFFERING FROM INCIPIENT, LATENT OR INACTIVE TUBERCULOSIS

J. M. TOBIAS, M.B., B.CH. (RAND), *Rietfontein Hospital, Johannesburg*

During the past 18 months 3 patients with active tuberculosis have been admitted to the European ward of the Rietfontein Hospital in whom the condition could be ascribed to the administration of steroids without a suitable umbrella cover of anti-tuberculosis drugs. It is to focus attention on this danger that these cases are now described.

Case 1. Male aged 47

There is nothing of significance in the previous history or family history.

For feelings of faintness on two occasions the patient consulted his doctor, who referred him to a urologist because albuminuria was found to be present. After investigations the right kidney was removed in January 1962. The pathological

On 2 November 1962 a pericardiectomy was performed by Mr. E. Joubert. The pericardium was found to be very adherent and the operation was a very difficult one technically. The patient, however, made a very good recovery and has now been discharged to an outpatient clinic.

The comparison of the chest X-rays before and after the steroid treatment is so striking that it puts the aetiological factor in the spread of the tuberculosis beyond doubt.

Case 2. Female aged 36

Pleurisy with effusion 17 years ago. Asthma since the age of 12. Appendicectomy and an ovarian cyst removed a few years ago.

Ever since the attack of pleurisy with effusion 17 years ago she was X-rayed every year and told that there was no change in her condition. Three months before admission she started feeling tired, and when she ultimately was X-rayed she was found to be suffering from active tuberculosis. Sputum positive on admission.

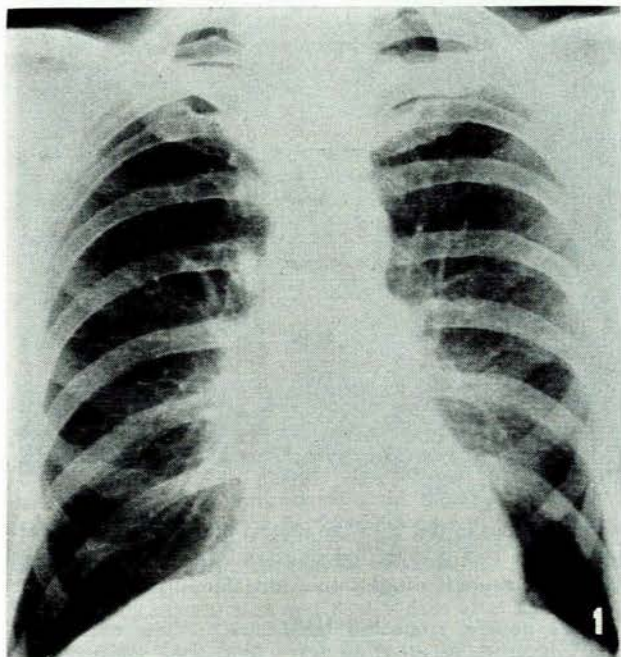


Fig. 1. Case 1. See text.

report was as follows: 'Histologically long-standing evidence of a burnt-out pyelonephritis, most likely of the tuberculous type. However, no evidence of current disease is present.' Because of a normal chest X-ray (Fig. 1) no anti-tuberculosis therapy was given.

Three months later his left wrist became painful. He again sought medical advice and, after various forms of treatment had failed to relieve his pain, he was given steroid treatment. A few weeks after the commencement of this treatment he started to feel tired and weak; he consulted an orthopaedic surgeon, who asked for an X-ray of his chest (Fig. 2) as well as his wrist.

At this stage he was admitted to Rietfontein Hospital, where he was found to be suffering from cardiac failure, and the diagnosis was made of pulmonary tuberculosis and constrictive pericarditis. Sputa examinations were negative both on direct examination and on culture, but there can be no mistake that he was suffering from an active pulmonary tuberculosis.

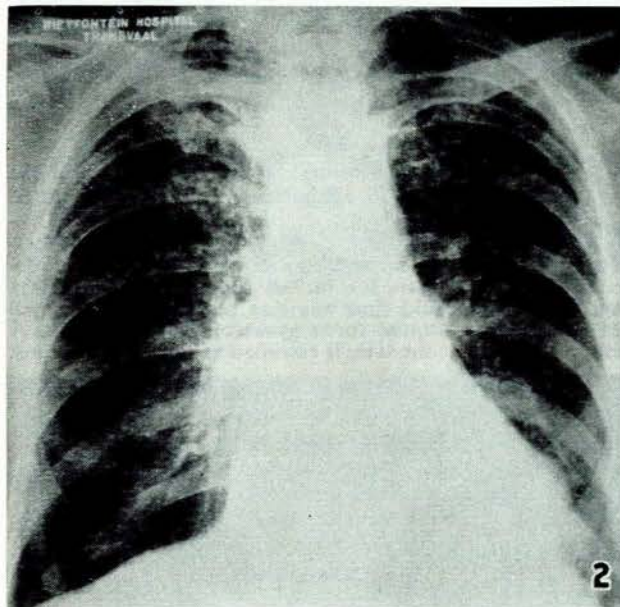


Fig. 2. Case 1. See text.

Particular enquiries were made of the patient whether she was ever given steroids for asthma, but this was denied. She did state, however, that shortly before she became ill she was given and used twelve suppositories with a steroid base for haemorrhoids.

Unfortunately, the plates that were taken annually before admission were destroyed and therefore one cannot compare them with the plate taken on admission (Fig. 3). This shows old calcification in the left upper lobe and, whereas the flare-up in this case can be presumed to be possibly due to the steroid administration, one cannot be so definite as in the previous case. The radiologists' reports for 26 May 1955 and 29 May 1957 read as follows:

'1955: There is an old fibrosed and calcified Koch's lesion present at the left apex. It has the appearance of being quiescent. However, without previous films for comparison it is not possible to dogmatize on the question of activity.

'1957: Compared with the previous films of 26 May 1955 there has been no marked change in the left apical and infraclavicular lesions then noted. If anything, they appear to be harder and more calcified now than formerly. There is no

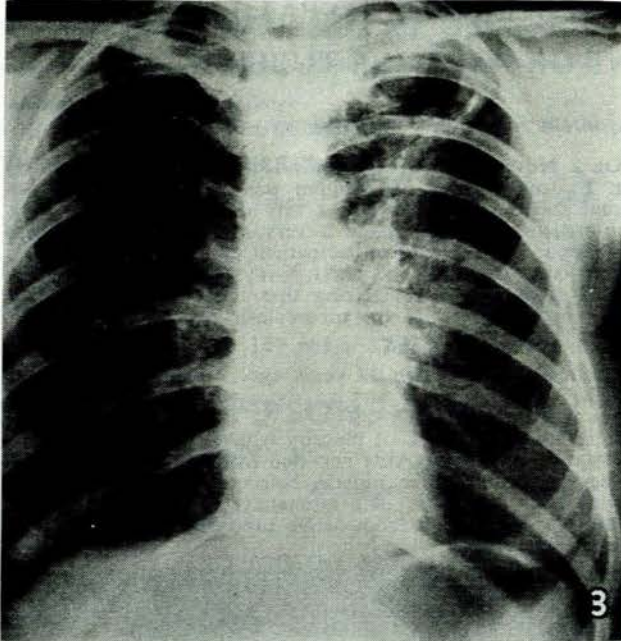


Fig. 3. Case 2. See text.

indication of activity. Conclusion: The Koch's lesions at the left apex are considered to be quiescent.'

Case 3. Female aged 43

This patient had been attending a hospital outpatient department for some years for various complaints. The earliest hospital record I could find was that in June 1956 she had been admitted to hospital for a gynaecological complaint. A chest X-ray taken at the time is recorded as normal. In August

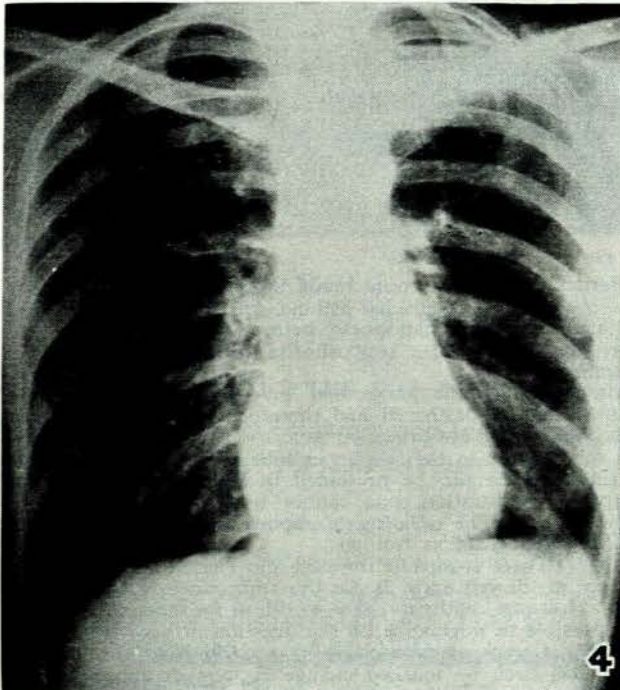


Fig. 4. Case 3. See text.

1957 she developed rheumatoid arthritis and attended the same outpatient department, where she was given steroids.

In October 1959 she was admitted to hospital with the diagnosis of hydropneumothorax on the left side. All investigations for tuberculosis both on culture and direct examinations were negative. In spite of this she was given a course of streptomycin and rimifon. She seemed to have made a good recovery and her X-ray (Fig. 4) shows a normal right lung, with a pleural thickening over the apex of the left lung.

At this stage she started attending outpatients again for her rheumatoid arthritis, and was put back on steroids but given no anti-tuberculosis treatment.

In November 1961 she was admitted to Rietfontein Hospital with a history of cough and weight loss. The X-ray (Fig. 5) shows bilateral disease with cavity formation. There

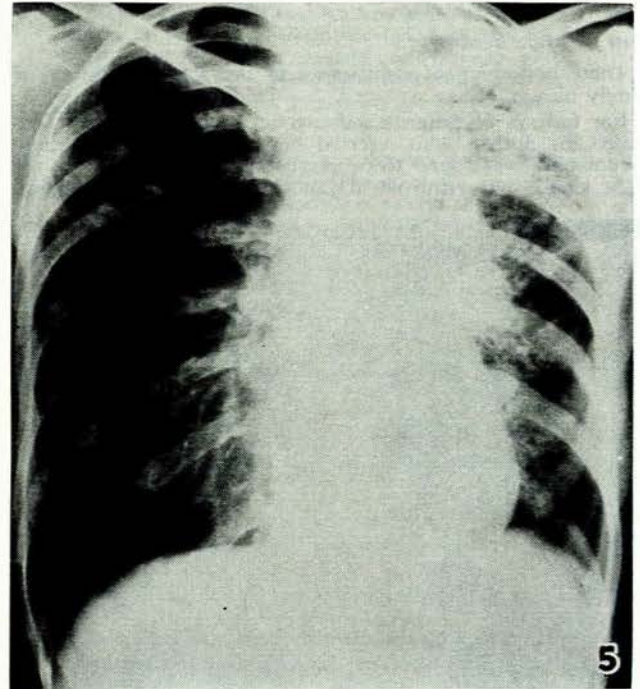


Fig. 5. Case 3. See text.

is no doubt that in this case the pleural effusion was of tuberculous origin and that the administration of steroids without any anti-tuberculosis drugs caused the flare-up.

SUMMARY

Three cases are described none of which showed signs of active disease at the time when steroids were administered, and in all three signs of active tuberculosis developed after the steroid treatment was given. Although steroid treatment has a definite place in the adjuvant treatment of some cases of tuberculosis, it should never be used unless an adequate course of anti-tuberculosis treatment is given at the same time.

I wish to acknowledge with thanks the permission of the Secretary for Health and Dr. F. H. Pieterse, Superintendent of the Rietfontein Hospital, to publish these cases.

Since this article was written another patient has been admitted to the same hospital in whom there has been a rapid spread of tuberculosis following upon the administration of steroids.