

THE TRANS-SCLERAL APPROACH

E. EPSTEIN, D.O.M.S., R.C.P. & S., *Senior Ophthalmic Surgeon, Boksburg-Benoni Hospital, Boksburg*

I. REMOVAL OF PERSISTENT PRIMITIVE VITREOUS MEMBRANES

The trans-scleral or posterior route as a surgical approach to the interior of the eye has had limited uses. Until now its main application has been for the removal of foreign bodies and occasionally parasites from the vitreous chamber. It has been used as a preliminary or as an emergency measure for glaucoma. It is recommended for expulsive haemorrhage, and there are reports concerning division of vitreous membranes. About 150 years ago, it was the route used by Saunders in the surgical treatment of congenital cataract. In a letter to one of his assistants, John Stevenson, he wrote that 'the instrument' (the well-known Saunders needle) 'should enter the sclerotica a line behind the ciliary ligament and should be conducted through the anterior part of the lens which is softest'. The recently reintroduced procedure of vitreous implant for retinal detachment naturally also uses this approach.

Horton Young in 1957 presented a paper to the Ophthalmological Society of the United Kingdom in which he described and advocated the posterior route for the routine extraction of cataracts.

Thirteen years ago I used this route to remove the retrolental membrane in a case of hyperplastic primitive vitreous. The patient was a 3-months-old full-term baby. The mother had noted a white pupil soon after birth. A diagnosis of retinoblastoma had been made and enucleation had been advised. The typical picture of the so-called persistent hyperplastic primary vitreous (persistent fibrovascular sheath) was found, viz. small eye, whitish retrolental membrane with vessels, stretched ciliary processes. By focal illumination and transillumination with the pupil fully dilated it was possible to deduce that the retrolental white tissue did not extend as a solid mass into the depth of the eye. The clinical signs and pathology of this condition need not be discussed further here. They have been fully described by many authors, including Treacher Collins, Ida Mann, Algernon Reese, Manshot, Francois and Wolter, etc. (Fig. 1).

Although I reassured the mother that this condition was not malignant she was most unhappy in case I should be wrong. Having been told it was malignant she could not rest until it had been definitely proved to be non-malignant. Perhaps a mother's intuition told her about the one case recorded in the literature, by Jokl, of retinoblastoma that arose in a hyaloid remnant! Faced with this impasse I suggested removal of the membrane, and that after it was frozen-sectioned enucleation should be proceeded with if it were found malignant. I felt quite confident that enucleation would not be necessary; removal of the membrane, however, is necessary for other reasons. Reese has pointed out that one never sees adults with persistent membrane, which seems to indicate that these cases usually end with enucleation.

Sooner or later the eye is removed, if not through a mistaken diagnosis of tumour then on account of glaucoma that supervenes. The abnormal tissue thickens as it invades

the lens. Spontaneous haemorrhages result in more fibrous tissue and destruction. The anterior chamber gets shallower and eventually the tension rises. A case I saw a year earlier in a young boy of 5 years showed all these features. Although the membrane was easily removed the eye was too far gone, so that further deterioration took place and phthisis bulbi followed. It was therefore felt that early intervention would prevent the complications, and also it was hoped that the child might obtain useful vision.

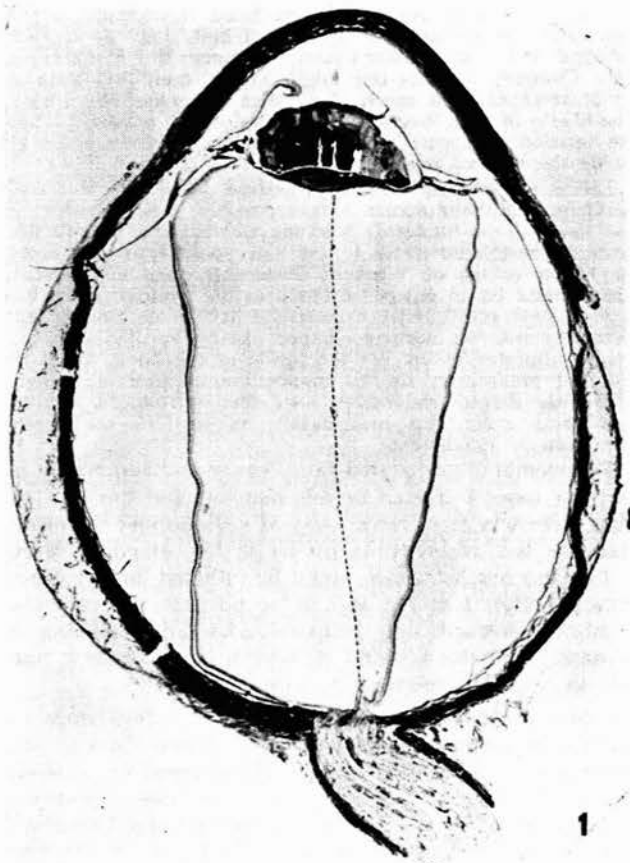


Fig. 1. Section of infant's eye showing persistent primary vitreous—the dense membrane posterior to the distorted lens between the stretched ciliary processes. The persistent hyaloid vessel can be seen where it just leaves the disc and joins the membrane. The dotted line represents the rest of the vessel not on the section. The retinal detachment is an artefact.

The surgical procedure is relatively simple. Although the operation is naturally done under general anaesthesia it must be stressed that complete local anaesthesia is given, as for any cataract operation. By 'complete' is meant blocking of the extra-ocular muscles as well as a retrobulbar injection and lid akinesia. The reason for this is self-evident. The extra-ocular muscles are paralysed to completely inhibit their tone. The presence of this tone, and especially the changes that sometimes occur if general anaesthesia is uneven, may add considerably to the danger

when the eye is opened. A simple ordinary retrobulbar injection is therefore not enough.

A large lateral canthotomy was a routine preliminary. The lateral bulbar conjunctiva was incised near the apex of the lateral fornix, and the anterior flap, including Tenon's capsule anterior to the external rectus insertion, was raised up to the limbus. After all bleeding spots had been cauterized the sclera was incised in a slightly curved line, concave forwards, but almost parallel to the limbus and a short distance anterior to the external-rectus insertion. The length of the incision is about equal to the corneal diameter, and its ends are turned rather sharply forwards for a few millimetres towards the limbus. Two 6×0 mild chromic sutures were placed a short distance from the ends of this incision. The scleral flap was gently elevated and the exposed uvea was lightly diathermized ('hyfrecator'). Although I have not used one nor found a need for it, a Flieringa ring might be fitted for greater safety. The uvea was opened with a cataract knife and the incision enlarged with a de Wecker's scissors through the diathermized area. Contrary to what one might expect, there was little or no bleeding and not much of a bulge or escape of vitreous. The blades of a de Wecker's scissors were then passed through the incision and cuts were made below the membrane to divide the hyaloid remnants.

This is not entirely a blind procedure. With the monocular headlamp ophthalmoscope it was possible in some cases to just visualize the blades deep to the membrane as one looked through the dilated pupil. It was also possible to look along the blades of the de Wecker's scissors through the incision. There might be an escape of blood as the hyaloid is cut, but as yet I have not found it excessive. I have since thought that diathermy with an electrode shaped like a Tyrrell's hook, but enamel-insulated except for the inside of the hook, might be a useful preliminary to this manoeuvre. A pair of straight or slightly curved iris forceps were then introduced and the membrane, grasped as near nasally as possible, was gently torn from its attachments.

The membrane separated fairly easily and completely in the four cases I treated in this manner, and the lens, or what there was of it, came away as well. Should the membrane be too adherent, as occurs in long-standing cases, so that too much trauma would be inflicted upon the eye (ciliary body), I feel it should be possible to grasp the membrane towards the temporal edge and, drawing it down a little, use suitable scissors first to incise it and then to excise a large central piece.

Before the scleral incision was closed, a few drops of hydrocortisone suspension were injected into the vitreous. This was done in three of these four cases and the vitreous cleared completely; whereas in the other case (the first), organization of some of the blood resulted in a fine membrane in the vitreous. Additional edge-to-edge 6×0 mild chromic catgut sutures were then placed to seal the scleral wound thoroughly. The conjunctiva was closed and the canthotomy repaired with the same gut.

A fifth case was treated first by discission of the lens and then the membrane too was divided. The result was not very satisfactory. The opening achieved was small, the tissue did not retract well, and it was very difficult to study the fundus and refract the case satisfactorily.

These cases were all treated with spectacles and occlusion of the sound eye to try to stimulate the visual development of the affected eye. Of the five, two were lost for follow-up studies after 2 years, one after 3 years (the needling case), another was followed-up for 5 years and one is still seen at times (11 years). The follow-up failed to show any development of useful vision in the affected eye nor, indeed, even any improvement in the fixation of

a light. The parents cooperated fully, but the children could not adapt themselves to the aphakic correction.

The postoperative growth of the eyes proceeded well. The difference in the size between the two eyes in each case became less noticeable. The two cases that were followed-up for 5 and 11 years both became 'myopic', the aphakic correction changing from +12.0 / +0.75 and +12.5 / +1.5 to +5.0 / +0.5 and +2.0 / +1.0 respectively. The case that was treated only by needling lagged behind the others in its development. All became esotropic.

It might be asked whether the functional results justified the major surgical procedure. In this small series of cases one is not justified in drawing conclusions from the functional results achieved. Most of the cases could not be followed-up long enough. It is just possible too that there were more retinal defects in this small group than usually occur. From the cosmetic point of view, the complete removal of the membrane led to a much more pleasing appearance than resulted in the case treated by needling only.

This condition should be treated as soon as possible. Delay merely allows the membrane to thicken. I have seen a membrane that extended apparently only half way behind the lens (so that an optical iridectomy was done) gradually thicken and extend so that it completely blocked off all view of the fundus. There is also just the chance that in an early case surgical intervention might remove the membrane and leave the lens intact; but, from the literature and the limited material I have been able to study, I think the lens is inseparable from the abnormal tissue.

II. EXTRACTION OF POSTERIORLY DISLOCATED LENSES

My experience with the above cases and the not infrequent unsatisfactory results of the usual anterior approach for posteriorly dislocated and subluxated lenses, prompted me to apply the posterior-route extraction to this problem.

My first case was a traumatic one, with the lens loose in the vitreous, complicated by subacute glaucoma that had been present for several months. Miotics and 'diamox' failed to control the tension.

The first procedure was to fix the lens in its normal position behind the iris by means of two needles as described by Barraquer. Under local anaesthesia the lids were held open by means of sutures that were fixed with adhesive tape to the forehead and cheek (Fig. 2). The conjunctiva was then incised and raised as already described. Surface diathermy was applied to the sclera a few millimetres anterior to the insertion of the external rectus—the region to be penetrated by the needles. The patient was then placed prone on the table in reverse Trendelenburg position with the head projecting over the table to face straight downwards. The lens thus settled into its normal position and could be seen through the pupil (Fig. 3). The surgeon wearing the headlamp ophthalmoscope is seated below the patient. Two straight fine needles, preferably with cutting points but, failing these, ordinary fine household needles, were introduced through the sclera about 4 mm. from the limbus. Even with a relatively opaque lens the needles can be seen as they traverse the vitreous just posterior to the lens. The first needle then transfixes the sclera nasally so that the lens was wedged against the iris. The second needle was introduced parallel to and about 5-6 mm. from the first. The needles were held in the usual holder.

Fixation of the globe is best achieved by means of double fixation forceps such as Monoyer's. Moner has improved on the two-needle method in that he uses a double needle (made

by Greishaber) in the shape of a staple, which is more easily applied (Fig. 4).

With the needles in position the patient was now turned on to his back again (Fig. 5). A canthotomy is again a useful procedure. The pupil is maintained in miosis if possible; pilocarpine is better for this than eserine in view of local anaesthesia.

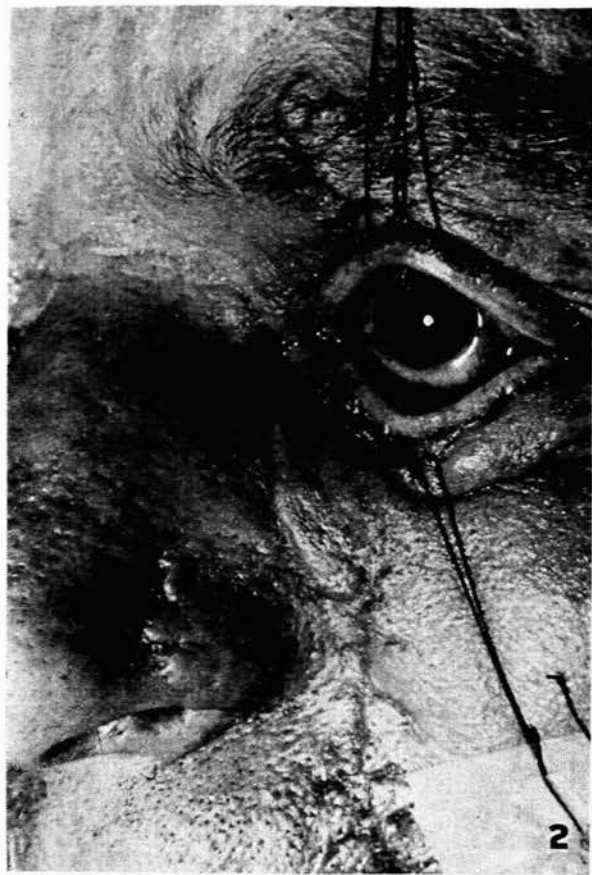

Fig. 2. The patient on his back. The facial scarring from the accident that caused the dislocation of the lens is evident. There is a marked traumatic mydriasis and the pupil is very black because the lens is lying on the retina at the posterior pole of the eye.

The incision in the sclera was made just anterior to the needles. After the ciliary body had been opened along a line of diathermy applications (Figs. 6 and 7) a Snellen or Arlt type of vectis was introduced through the wound and manipulated to fit round the lens. The end of this elongated vectis loop was bent a little more forwards so that it could fit round the nasal edge of the lens and function as a better scoop to draw the lens towards the wound (Figs. 8 and 9). A pair of capsule forceps without teeth were kept in readiness as the lens was delivered. A little manipulation of the needles in the posterior flap of the scleral incision might be necessary to allow the vectis to be placed in position and permit the withdrawal of the lens. The needles were left in position until the scleral wound was thoroughly sutured (Fig. 10). They help to maintain the form of the eye. When the sclera had been sutured a little diathermy was applied to each needle on the nasal and temporal sides before they were withdrawn (Fig. 11).

The postoperative course was uneventful. The glaucoma settled spontaneously; but it had been present too long and only a small temporal field of vision remained. However, the man retained his eye, and I feel that had the lens been removed via the usual anterior route, the glaucoma would most probably not have subsided.

I have done this operation in four other cases, all trau-

matic, two of which had also developed a raised tension. They all settled well without complications. Six months later, anterior chamber lenses were inserted in two of these cases and the visual acuity attained in both was 6/9 with a small additional correction.

My colleague at Boksburg-Benoni Hospital, Mr. J. Swartz, has operated on two cases of spontaneous degenerative dislocation, both in glaucoma—one very severely, with long-standing corneal haze. He followed the same technique except that he did not apply diathermy. Both cases settled well, although the one that had the very severe glaucoma was hypotonic when last seen. The other patient wears her correction and is very happy with her vision.

These seven cases, I feel, indicate the value of this procedure. The anterior-route extraction of lenses dislocated into the vitreous is well recognized as having definite hazards—distorted pupil, retinal detachment and glaucoma as can occur with any case of cataract extraction complicated by loss of vitreous. Five of the seven cases were already in glaucoma, so that the prognosis would have been very poor with an anterior-route extraction. Five cases obtained excellent visual results. The two with poor vision had had glaucoma far too long.

How is the glaucoma relieved? I thought at one time that the diathermy applied to the ciliary body acted like a cyclodiathermy that alleviated the tension. However, my colleague omitted the diathermy and yet the glaucoma settled in his two cases. Does the mere incision of the ciliary body if extensive enough act in the same way as cyclodiathermy? One can only speculate, but I do not think so. In February 1952 I excised a largish tumour from the ciliary body and postoperatively there was no hypotension. The patient has been followed up regularly and the eye is still functioning well. All cases of parasitic cysts removed from the vitreous by this approach, and the primary persistent vitreous cases mentioned in section I, settled without hypotension.

The persistence of glaucoma after an anterior-route extraction or its postoperative development in cases that preoperatively were without tension is most probably due to the vitreous that almost certainly entered the anterior chamber and lodged in the section. The thicker the vitreous the more likely are complications to follow. Subsequent changes in the vitreous probably strangle the entrance of the canal of Schlem. The further ingress of the vitreous into the anterior chamber must be much less, if it occurs at all, with the posterior-route extraction.

The probability of retinal detachments is I feel no greater, and perhaps less, with the posterior-route extraction. The surgical disturbance in the vitreous must seemingly cause traction bands fanning from the region of the incision. The greatest pull is therefore most likely to be on the opposite nasal retina. Time, and a larger series of cases, will show if this is a real danger and whether a barrage of diathermy or light coagulation should be laid down on the nasal hemisphere between the equator and the ora. However, any bands that might form with the posterior route will, I feel, still be less than would form with an anterior approach with the vitreous impacted in the

limbal wound. Thick vitreous in contact with aqueous condenses and shrinks, as evidenced by the deformation of the pupil that develops slowly after vitreous loss. Disturbed vitreous surrounded by normal vitreous does not seem to react in the same way as vitreous surrounded by

aqueous. If that were not so the operation of vitreous implant for retinal detachment would be irrational.

I am grateful to Dr. N. S. F. Proctor of the South African Institute for Medical Research for the section shown in Fig. 1, and to the Department of Surgery, University of the Witwatersrand, for help with the photography.

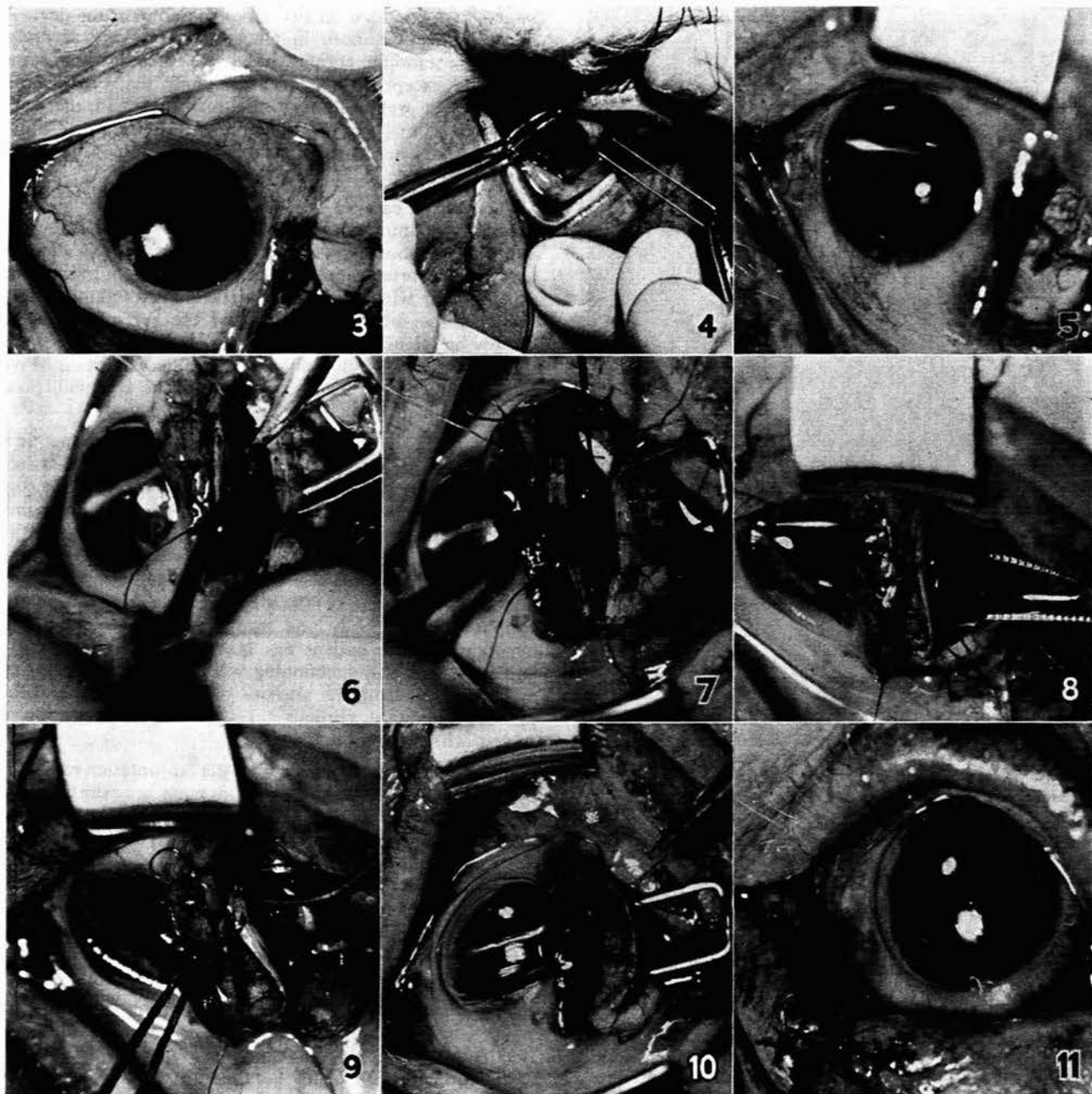


Fig. 3. Patient lying prone. The photograph has been taken from below. The lens can be seen lying in the pupil area except for a small crescent at 12 o'clock.

Fig. 4. Patient prone, the surgeon below looking up. The eye is fixed by the Monoyer double forceps and the Barraquer double needle is being inserted.

Fig. 5. Patient again on his back. Head has been retowed. Lid speculum in place. The points of the double needle can be seen subconjunctivally near the closed forceps. The needles supporting the lens are visible. The obliquity of the photograph apparently displaced them inferiorly.

Fig. 6. The sclera has been opened; 2 catgut sutures placed and the uvea is being diathermized.

Fig. 7. The commencement of the incision in the uvea.

Fig. 8. The lens is 'crowned' by the incision as it is delivered by the vectis.

Fig. 9. The lens is steadied as a capsule forceps approaches to remove it.

Fig. 10. The scleral incision is being closed. Air has entered the anterior chamber spontaneously.

Fig. 11. The completed operation.