

FRIEDLANDER'S OSTEOMYELITIS

REPORT ON THREE FURTHER CASES

J. FARMAN, M.B., CH.B., *Department of Radiodiagnosis, Groote Schuur Hospital, Cape Town*

Komins, Skapinker and Kay¹ reported klebsiella infection of the long bones in two adult male Bantu patients in 1950. The literature was reviewed at the time and comment was made on the infrequency of reports of osteitis caused by this organism.

A year later, Muskat and Findlay² reported a third case and, following this, 3 further cases were described by Findlay and Skapinker.³

Since the last report, the world literature has been reviewed, but no further cases have come to light.

All 6 cases that were reported had occurred in Bantu adult male patients. The following 3 patients were seen at Groote Schuur Hospital during the past 3 years, and several points of similarity are to be seen in the 9 cases.

Case 1

A.I., a Coloured female, aged 34 years, was admitted to Groote Schuur Hospital under the care of Prof. J. T. Louw on 17 May 1961, having been referred to hospital with an incomplete abortion. Her haemoglobin was 6 G. per 100 ml. on admission, for which she received 3 pints of blood. Under antibiotic cover of penicillin and 'sulphatriad' an evacuation was performed; products of gestation were present on histology of the scrapings and, in addition, a chronic endometritis was noted by the examining pathologist. A cervical swab taken on admission showed growth of coliform organisms on culture.

The patient made a good and uneventful recovery and was discharged on 20 May 1961.

On 29 June 1961 the patient was readmitted to Groote Schuur Hospital under the care of Prof. J. H. Louw, with the complaint of continuous pain in the right thigh for 3 weeks before her admission. She was first seen at the outpatient department some 8 days previously, with pain and tenderness on the anterolateral aspect of the right mid-thigh.

Examination, when the patient was first seen at the outpatient department, showed that her general condition was good; her temperature was 98°F., but an ill-defined swelling in the region of the mid-thigh on the right was present. This swelling was about the size of a saucer, it was tender to palpation, no fluctuation was noted, and no glands were palpable.

When the patient returned to the outpatient department on 27 June 1961, the temperature was found to be 99.2° F. and the thigh was still painful and slightly swollen. Her ESR at this stage was 40 mm. per hour and the white blood count was 11,000 per c.mm.

The patient had been placed on 'achromycin', 250 mg. 6-hourly, when first seen at hospital on 21 June 1961, but this had not resulted in any improvement in her condition.

X-ray of the right femur and tomography (Fig. 1) undertaken at the time showed cortical erosion on the anterior surface of the upper shaft of the femur, with no evidence of periosteal reaction. The lesion was thought to be compatible with a diagnosis of an early osteomyelitis, but the outside possibility of an early non-benign lesion was also suggested. An operation was performed on 5 July 1961, and a 3-inch long area was found on the anterolateral aspect of the middle third of the right femur, with appearances suggestive of a chronic osteitis. A biopsy was taken and a swab sent for culture. The surgeon at the time stated that the features were those of a chronic osteomyelitis, and the wound was closed in layers. This observation was confirmed by the histologist and, in addition, a heavy growth of klebsiella organisms was obtained. The patient was then put on 'terramycin', 500 mg. 6-hourly, for a month. An uneventful recovery ensued and the patient was discharged some 2 weeks later.

Case 2

C.J.V., a European male, aged 50 years, had been diagnosed in Port Elizabeth in August 1961 as having haemochromatosis. His serum iron was 244 mg. per 100 ml., and liver biopsy and skin biopsy showed the histological picture of haemochromatosis.

On 1 January 1962 he collapsed with severe abdominal pain, radiating to the back, associated with generalized rigors and anuria. Acute renal failure was diagnosed. He was given large doses of steroids and 'levophed' to maintain his blood pressure. On 6 January 1962 he was transferred from a Port Elizabeth hospital to the Volks-hospitaal in Cape Town, and found to have generalized oedema with abdominal distension. Blood urea at the time was 125 mg. per 100 ml. and serum bilirubin 4 mg. per 100 ml.

Thirty-six hours before admission to Groote Schuur Hospital the patient became anuric. Retrograde ureteric catheterization was performed and the ureters were found to be patent. Catheterization produced a gush of urine and brown debris.

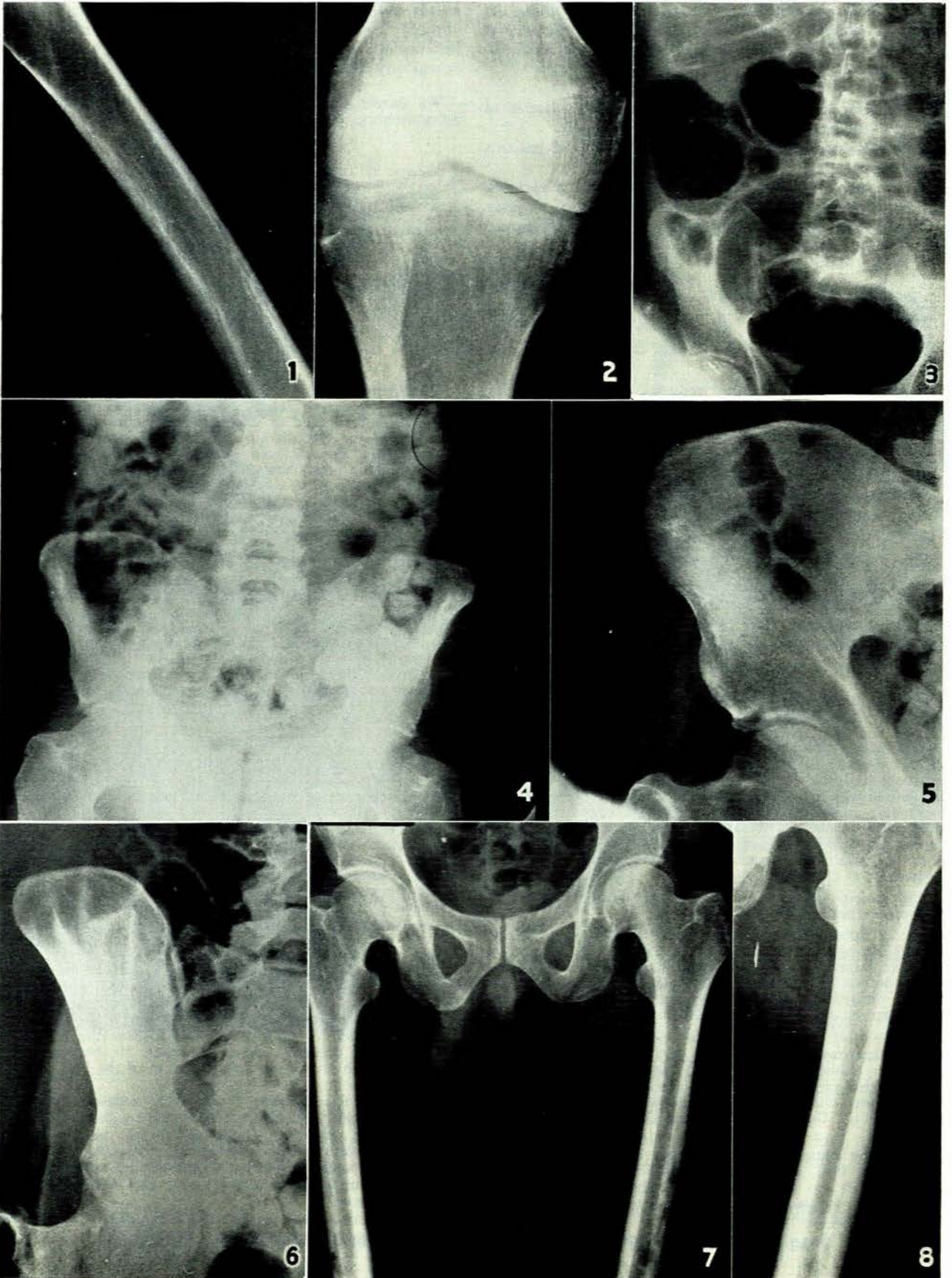
On admission to Groote Schuur Hospital the patient was extremely ill, anaemic and oedematous. He was moderately jaundiced with grey-brown pigmentation of the face, neck and forearms.

Cardiovascular system: Pulse 112, regular, BP 150/85 mm.Hg, no cardiomegaly, not in congestive cardiac failure.

Respiratory system: Impaired basal percussion with decreased breath sounds. Abdomen: moderate distension; 4-finger hepatomegaly; 2-finger splenomegaly; moderate ascites.

CNS: Cranial nerves intact; motor and sensory nerves and reflexes normal.

Investigation: Haemoglobin 15 G. per 100 ml.; white blood



count 3,000 per c.mm. normal differential count, ESR 25 mm. in the first hour.

X-ray of chest: No active lung lesion was seen.

Soon after admission the patient passed 600 ml. of urine, but 48 hours after admission he collapsed with a blood pressure of 100/0 mm.Hg. His temperature was 100.6°F. and it was thought that he had a gram-negative septicaemia.

On hydrocortisone, digitalis, 'chloromycetin' and 'celbenin' the patient rallied and his urinary output improved; within 10 days his urinary output was satisfactory and remained so until the time of his discharge, and there was no recurrence of the oedema. He was never clinically in congestive failure and it was thought that the generalized oedema resulted from previous over-hydration. *Klebsiella pneumoniae* was cultured from the patient's blood and his urine, and it was obvious that he now had a klebsiella septicaemia.

The blood urea on 20 January 1962 was 188 mg. per 100 ml. and this rapidly came down to 28 mg. per 100 ml. by 28 January 1962.

Repeated blood culture after therapy failed to grow the klebsiella organism and urinary cultures were also negative.

Coliform organisms were, however, cultured in the urine and 'furadantin', 100 micrograms 6-hourly, was given to combat this infection.

Adrenal function tests confirmed that the glands were functioning normally and that there was no suggestion of Addison's disease. The patient remained weak for a long time but, in spite of a high-protein diet and short courses of plasma intravenously, he was still emaciated at the time of his discharge.

During the course of his illness the patient complained of severe pain in the region of his iliac crests, and examination revealed excruciating tenderness over both anterior superior iliac spines which radiated backwards along the iliac crests. X-ray of the pelvis revealed bony erosion in the region of the anterior superior iliac spines and, in addition, the right femur also showed periosteal reaction with subperiosteal erosion (Fig. 2) In the femur pain was severe and the patient was very tender to palpation. 'Colistin' therapy, 500,000 units 6-hourly, was commenced and was later increased to 1,000,000 units 6-hourly. This was given for a total of 14 weeks, at the end of which time a great improvement was noted in both the patient's general condition and his reaction to palpation of his iliac crests and femur.

X-rays of his pelvis (Fig. 3) at the beginning of his stay in hospital showed both iliac bones to be quite normal. X-rays on 8 March 1962 showed no lesion either, but cortical and sub-cortical bone erosion was present on the film on 21 March 1962, on both the right and left sides (Figs. 4 and 5).

By 30 April 1962 an improvement in the appearance of the lesion was noted. The bone was beginning to recalcify, and the patchy nature of the lesion was less obvious. No abscess or sequestrum had formed (Fig. 6).

After 4 months' treatment in hospital the patient was referred to his general practitioner in Richmond, Cape, for further care and continuation of antibiotic therapy.

Case 3

J.W., a Coloured male, aged 38 years, was admitted to Groote Schuur Hospital in July 1959 under the care of Prof.

J. H. Louw, with the complaint of pain and tenderness in his left leg. He had been quite well until some 6 weeks before his admission when the course of his illness was started by an influenza-like attack which caused him to remain off work for 2 weeks. A general practitioner was called, who diagnosed influenza and bronchitis. For this the patient was given an injection of penicillin and put on a course of sulphadiazine. At no time was he thought to have had pneumonia and, while he did cough a fair amount during this illness, the cough was dry and unproductive.

Infections in his right and left femora caused him to be admitted to hospital in February 1960 and again in January 1961. He had had recurrent abscesses forming in the lower end of the scar over the left femur which had broken down spontaneously and discharged pus. In between there was no sinus present and healing was complete. The highest recorded temperature during his visits to hospital was 100.5°F. His white blood count varied from 7,000 to 15,100 and the ESR, during a flare-up, ranged from 27 to 54 mm. per hour. On several occasions *Klebsiella pneumoniae* was cultured from the bone lesion, and the surgical treatment for the osteomyelitis had varied from incision, drainage and curetting to drilling of bone.

The skull, mandible, hands, bony pelvis and feet were also investigated, but no sign of infection was observed. The X-ray appearances in 1959, when the patient was seen for the first time, revealed small areas of erosion on the lateral aspect of the cortex of the middle third of the left tibia, and the first radiological evidence of femoral involvement showed cortical erosion of bone, with slight periosteal reaction (Fig. 7). No radiological evidence of sequestrum formation was observed and operation in 1959 or later did not produce any sequestrum either.

DISCUSSION

Lesions in common with the 6 cases previously recorded and reviewed in the literature show certain characteristics which may be regarded as features of this type of osteomyelitis:

1. A tendency for the bone involvement to be multiple and for the long bones to be mainly affected.
2. The site of infection is usually the shaft of a long bone. No evidence of joint involvement was seen in the 3 new cases reviewed. Muskat and Findlay's case, however, did have a septic arthritis in the late stage of infection.
3. The mode of onset in the 3 cases described was not acute, except for Case 2, where the bone infection followed on septicaemia. Even here, though, the patient had been ill for some weeks before the onset of bone involvement, with a severe urinary infection.
4. No preceding pneumonic infection was observed in the present series, but Case 3 had bronchitis. In 4 of the 6 cases reported from Johannesburg the patients had severe antecedent klebsiella pneumonia.
5. The earliest radiological appearances were either a mild periosteal reaction or patchy osteoporosis of the cortex of the affected bone. With early and vigorous treatment, thickening of the shaft of the bone resulted from subperiosteal new bone formation.
6. Sequestrum formation was observed in only 1 of the 9 cases reported.¹
7. All the cases occurred in adults.

Fig. 1 This is a reproduction of a tomogram of the right femur of Case 1, showing the irregular destruction of the bone cortex (in the centre of the photograph) on the antero-lateral aspect.

Fig. 2. (Case 2.) Showing the mild periosteal reaction on the lateral aspect of the lower femoral shaft, just above the condyle.

Fig. 3. (Case 2.) Normal iliac bones before onset of osteomyelitis.

Fig. 4. Patchy decalcification of both iliac bones can be seen. Radiograph taken on 21 March 1962 — Case 2.

Fig. 5. A localized view of the right iliac crest showing detail of the degree of involvement of the bone — Case 2.

Fig. 6. Showing the reconstitution of the iliac bone, following therapy. — Case 2.

Fig. 7. (Case 3.) The degree of involvement of both femoral shafts with cortical thickening is well demonstrated. The multiple translucencies noted are the result of surgical drilling. Radiograph taken on 21 June 1962.

Fig. 8. (Case 3.) Radiograph taken in November 1962 showing bone 22 months after start of illness.

(Supplement — South African Journal of Radiology)

SUMMARY

Three further cases of klebsiella osteomyelitis are reported. Unlike the previous cases described by South African authors, these occurred in a European male, Coloured male and Coloured female. The clinical and radiological features are discussed and the previous cases reviewed.

I wish to express my gratitude to Prof. J. H. Louw, under whose care Cases 1 and 3 were treated, and to Prof. L. Eales

for permission to publish details of Case 2.

I am also indebted to Dr. L. Werbeloff for help and criticism, and to Dr. J. G. Burger, Medical Superintendent of Groote Schuur Hospital, for permission to publish the cases.

REFERENCES

1. Komins, C., Skapinker, S. and Kay, S. (1950): *Brit. J. Radiol.*, **23**, 168.
2. Muskat, D. A. and Findlay, N. (1951): *Lancet*, **2**, 1154.
3. Findlay, M. and Skapinker, S. (1953): *Brit. J. Radiol.*, **26**, 358.