

## GASTRIC MUCOSAL CHANGES AFTER OPERATIONS ON THE STOMACH

D. J. DU PLESSIS, CH.M., F.R.C.S., *Department of Surgery, University of the Witwatersrand and Johannesburg General Hospital*

The reflux of bile and pancreatic secretion into the stomach has on a previous occasion been mentioned as a cause of chronic atrophic gastritis, which could in some cases proceed to the development of a gastric ulcer or even a gastric carcinoma.<sup>7</sup> Since the chief function of the pylorus is to prevent such reflux,<sup>6</sup> it seemed obvious that operations resulting in a disturbance of this protective mechanism could equally result in reflux gastritis and its complications. This paper is a report of the experiences in this department with such gastric mucosal changes in a series of patients who presented with one or other of the clinical manifestations following on postoperative reflux gastritis.

There has been an opportunity to study 36 patients with postoperative symptoms resulting from this complication of gastric surgery, and the clinical syndromes presenting in these 36 patients have been subdivided as follows: reflux gastritis 12, postoperative haemorrhage 6, gastric ulceration 6, gastric carcinoma 3, and stomal ulceration 9.

Whenever possible, the mucous membrane has been studied histologically, and if a large portion of mucosa was available for study, it was rolled up and cut across in the manner previously described by Stein,<sup>23</sup> giving an opportunity of studying long segments of mucosa on a single slide (Fig. 1).

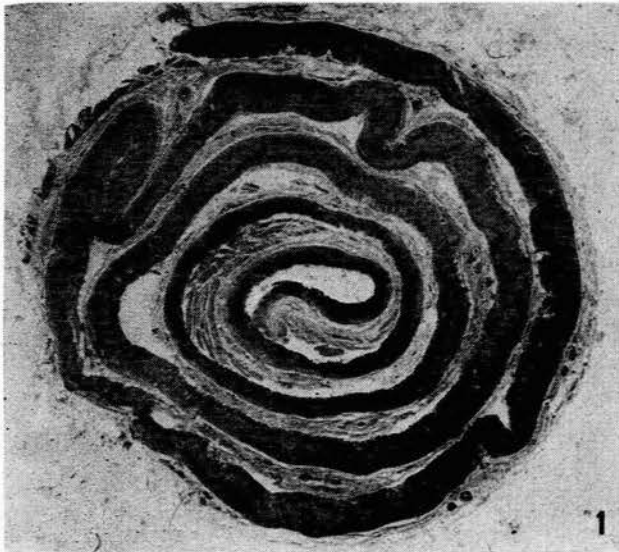


Fig. 1. A long strip of gastric mucosa rolled up, cut across and mounted for microscopic examination.

The original gastric operations had been performed by a large number of surgeons in various parts of the country. I personally performed only one of the original operations, and the others had been performed by so many different surgeons that there can be no question of ascribing the complications to a particular defect in the technique of the original operation. The majority of the final corrective operations were performed by me, but in a few instances these operations were done by various surgical colleagues, who very kindly provided

me with the details of the case as well as the tissue removed at the operation.

### REFLUX GASTRITIS

Twelve patients suffering from reflux gastritis were studied intensively. There were 6 males and 6 females in this group; the average age of the males was 40.2 years, while that of the females was 58.8 years. The significance of this difference in age distribution is obscure.

Eleven of the original operations performed were partial gastrectomies, while one was a gastro-jejunostomy. The indications for surgery were duodenal ulcers, gastric ulcers, gastric carcinomas and, in one instance, hypertrophic pyloric stenosis. The complication of reflux gastritis, therefore, does not follow any particular pathological condition. The average time following the original gastrectomy was 2.1 years, without any difference between Billroth I and Polya operations, whereas the gastritis presenting after a gastro-jejunostomy did so only 22 years after the original operation. This difference between the time interval following gastrectomy and that after gastro-jejunostomy, suggests that the retention of the pyloric antrum protects the patient against this complication.

In the series of 12 cases, 5 patients had had a second operation before presenting to us. These included vagotomy in 1 instance, negative exploratory laparotomies in 2, a change of a Polya gastrectomy to a Billroth I type of anastomosis in 1, and an entero-anastomosis in 1. None of these operations had any beneficial effect.

### Symptoms

**Pain.** All these patients presented with abdominal pain, which they described as being very much like their original pain. In 9 instances the pain was epigastric, in 2 it was described as being in the left hypochondrium, and in 1 it was substernal. In 4 patients the pain radiated to the back. The pain was variously described as being cutting or burning. Although one patient maintained that the pain was constant, the others pointed out that the pain came on shortly after eating and lasted for a variable period afterwards.

Acid was given in one instance to improve the pain, and this seemed to be of some temporary assistance, but when it was tried subsequently on other patients it had no beneficial effect. Alkalis relieved the pain in only 2 patients, and in the others it very clearly failed to produce any relief at all. It was found that 'kolantyl' relieved the pain partially in 5 patients, although it failed to have any effect in 2. The reason for the rather better results with kolantyl is thought to be the fact that it contains a demulcent which presumably protects the mucous membrane against the refluxing duodenal contents.

**Vomiting.** Ten of these patients complained of nausea and vomiting, which invariably relieved the pain. The vomitus consisted of small quantities of bile, and in 3 instances food was also sometimes vomited.

**Loss of weight.** Because of the dietary restriction resulting from this pain and vomiting, it is obvious that these patients all complained of loss of weight.

**Additional associated symptoms.** In 3 patients there was also a clear story of symptoms ascribed to the dumping syndrome, but in all 3 the dumping syndrome was of secondary importance to the pain produced by the reflux gastritis.

### Physical Signs

In none of these patients could anything abnormal be noticed on physical examination apart from slight, rather diffuse, epigastric tenderness in 5 cases.

### Special Examinations

**Haemoglobin level.** This was not significantly reduced; in males the average was 14.7 G. per 100 ml. and in females it was 13.6 G. per 100 ml.

**Maximum histamine test.** The average total acid obtained by means of the maximum histamine test was 1.46 mEq. per hour. A feature of this test was that bile was macroscopically present in the gastric aspirate of all the patients and in 3 instances there was also an abnormal amount of mucus present in the gastric aspirate.

**Barium meal.** In 7 patients this showed no abnormality, but in 1 the radiologist reported hypertrophic gastritis, and in 2 there was a suggestion of a shallow gastric ulcer. Diagnosis of an ulcer was not subsequently substantiated.

**Occult blood in the stool.** This was never positive in the patients investigated in this group.

**Gastrosopy.** This was performed by Dr. B. Koch and Mr. J. A. Myburgh on 5 patients. They reported hypertrophic gastritis in 1, and scattered superficial erosions in 2; and a black-silk stitch was seen hanging from the mucous membrane in the region of the stoma in 1 patient. Marked biliary reflux was reported in 1 case.

**Gastric cytology.** Nothing abnormal could be found on gastric cytology in 2 patients. In 1 patient a carcinoma was reported, but this was not subsequently substantiated at laparotomy.

### Histology

In all the patients examined there was severe atrophic gastritis around the stoma, spreading for a variable distance away from this site. This occurred after Billroth I operations (Fig. 2) as well as Polya type operations (Fig. 3). In one case 2 black-silk sutures were found hanging from the gastric mucous membrane, surrounded by a very small ulcer. It is known that the use of black-silk sutures in a suture line of this nature is undesirable and it should clearly be avoided.

### Management

No further operation was recommended in 3 patients who had comparatively mild symptoms of short duration, and they were treated by means of the usual peptic ulcer regime. Two of these have remained unchanged. The third patient improved with the use of acid, but this was temporary; he has since deteriorated and surgery is being contemplated.

In 2 patients operation was recommended but not accepted, and they were treated as for peptic ulceration. The one patient deteriorated and has very recently had a conversion to a Roux-en-Y anastomosis (a vagotomy having been performed on her at the time of her second previous operation). The immediate result is most satisfactory with a striking improvement in pain, but the follow-up period is still very short.

In 2 patients the Polya gastrectomy was changed to a gastro-duodenal type of anastomosis. In one the Polya gastrectomy was altered to a Billroth I operation, and this patient was significantly improved. In another patient who also had dumping symptoms, a vagotomy and a jejunal implant were performed from the stomach to the second part of the duodenum. The reflux symptoms and the dumping were significantly improved by this operation.

In 1 patient a gastro-jejunostomy, previously performed for a hypertrophic pyloric stenosis of the adult type, was closed and a pyloro-myotomy was done. This patient has not benefited by this operation at all.

In 1 patient a vagotomy and an entero-anastomosis were performed, but the patient still has a reflux and has not shown any improvement.

Towards the end of the series a Roux-en-Y operation was performed in 3 patients. This operation requires a vagotomy to prevent jejunal ulceration, and the vertical loop must be at least 12 inches long, to prevent any reflux of bile and pancreatic secretion into the stomach. All 3 of these patients have derived very significant benefit from this operation, but the follow-up has not been long.

### HAEMORRHAGE FROM POSTOPERATIVE REFLUX GASTRITIS

In this category there were 6 patients—4 females and 2 males. Here again the average age of the males was 42 years, and that of the females was 59.5 years. The significance of this difference in age incidence is not certain, but it is of considerable interest that, taking this and the first group of patients together (18 cases), the average age of the males was 40.7 years and that of the females 59 years.

The indications for the original operations were duodenal ulcers and gastric ulcers; therefore again we find that this haemorrhage is not a complication following any particular pathology.

The original operation was a partial gastrectomy in 5 patients and a gastro-jejunostomy in 1. Here again we find the interesting phenomenon that the average time since the gastrectomy was 5.5 years, whereas the gastro-jejunostomy had been performed 30 years previously. This also suggests that the pyloric antrum has a certain protective effect against the development of this complication.

Two of these 6 patients had had more than one operation by the time they were first seen by us. One patient had already had a second higher gastrectomy for symptoms of reflux gastritis, but derived no benefit from this procedure. The other patient had already had a second operation, which, as far as could be ascertained, was only a laparotomy for pain and vomiting, and a short while later she had a third procedure for pain and melaena; on this occasion an entero-anastomosis was performed. This had no beneficial effect and she almost immediately developed pain and bleeding again.

The clinical presentation of this group of patients could be subdivided into 3 different types: (1) Typical reflux gastritis with bleeding, either acute or chronic; (2) asymptomatic bleeding; and (3) severe haemorrhage very soon after the gastric operation.

### Typical Reflux Gastritis with Bleeding

In this category there were 3 patients, all of whom had had a Polya type of partial gastrectomy, 1 for a duodenal ulcer and 2 for haemorrhage of uncertain origin. All 3 of these patients presented with typical reflux gastritis symptoms identical to those previously described. There was pain in the epigastrium after meals, not improved with alkalis and associated with nausea, vomiting and loss of weight. In one instance a superficial erosion was seen on gastroscopy, and the maximum histamine test showed a very low total acid.

The management in these 3 patients was conservative in the first instance. In 1 patient this failed to stop the hae-

morrhage and a laparotomy had to be performed. A higher resection with a Roux-en-Y anastomosis was carried out, but unfortunately the patient, who was aged 70, died of congestive cardiac failure 4 days after the operation. The examination of the portion of the stomach which was removed showed severe atrophic gastritis with superficial erosions (Fig. 4).

In the remaining 2 patients haemorrhage stopped on conservative management and a subsequent barium-meal examination was normal in both instances. Haemorrhage recurred in both these patients, and therefore an elective operation of a vagotomy and conversion of the gastrectomy to a Roux-en-Y type of anastomosis was performed. In both the pain stopped immediately and the patients have had no further haemorrhage, although the follow-up period in both of them is short.

#### *Asymptomatic Bleeding*

In this category there were 2 patients who presented after a previous gastric operation with haematemesis, although in neither was there any suggestion of the typical clinical picture of reflux gastritis. This absence of pain in some patients with erosive gastritis is well known.<sup>8</sup>

One patient had an operation for dyspepsia and haematemesis, at which a Polya operation was performed. After that she continued to bleed, but barium-meal examination and gastroscopy were both normal, and the maximum histamine test produced only 0.96 mEq. of total acid per hour. A laparotomy was performed and no ulcer could be found, but a vagotomy and a Roux-en-Y type of anastomosis was done. After that the symptoms and the bleeding ceased, although the follow-up period has not been long. Histological examination of a small portion of the stomach which was removed showed atrophic gastritis with superficial erosions.

The other patient presented with severe haematemesis 30 years after a gastro-jejunostomy had been performed for a duodenal ulcer. Conservative management failed to stop the haematemesis and eventually an emergency Polya gastrectomy was done. Examination of the stomach again showed no ulcer, but there was severe chronic atrophic gastritis of the major part of the portion of the stomach that was removed.

#### *Early Postoperative Haemorrhage*

In this category there was only one patient who had had a Billroth I operation performed for a gastric ulcer. The postoperative course was quite uneventful until the 7th day, when severe bleeding occurred. In spite of conservative management, including the administration of 30 pints of blood, this haemorrhage did not stop and therefore a second emergency operation was performed. No ulcer was found, but the Billroth I anastomosis was changed to a Polya type of partial gastrectomy. The bleeding stopped and there was no further occurrence for 5 years until the patient died from other causes. On examination of the resected portion of the stomach, only fundic mucous membrane with small superficial erosions was found.

#### POSTOPERATIVE GASTRIC ULCERATION

In this category there were 6 patients and it is of interest to note that all the original operations had been performed for duodenal ulceration. The significance of this is not certain, but it certainly does suggest that the postoperative gastric ulcer was not one which had been missed at the time of the original operation, nor could it easily be ascribed to some common underlying factor which had also been responsible for the original ulcer.

There were 4 males and 2 females in this group; the average age of the males was 61 years and the females 62.

The original operation was a gastro-jejunostomy in 4 patients and a partial gastrectomy in 2. It is interesting to note that the average period between the original operation and the development of the gastric ulcer was 23.5 years following the gastro-jejunostomies and 2 years following the gastrectomies. Here again there is a suggestion that

the antrum has a protective action which delays the onset of this type of postoperative ulceration in the stomach.

#### *Symptoms*

These patients had the typical story of epigastric pain after meals, but they obtained relief from antacids. Vomiting was not a particular feature, but they mostly complained of loss of weight. One patient presented as an emergency with haematemesis, but in the others there was no history of bleeding.

#### *Physical Signs*

Epigastric tenderness was the only abnormality found on clinical examination.

#### *Special Examinations*

*Barium meals.* A gastric ulcer was shown clearly in 2 patients and there was some suggestion of an ulcer in a third.

*Gastric cytology.* This was only done in one case, but nothing abnormal was found.

#### *Treatment*

The patient with a Billroth I gastrectomy had excision of the distal portion of the stomach and the Billroth I anastomosis was changed to a Polya type.

In 1 patient with a Polya gastrectomy the ulcer-bearing area was excised and a higher Polya gastrectomy was performed.

In 3 patients in whom the gastric ulcer followed a previous gastro-jejunostomy, a Polya gastrectomy was performed.

In one case the age of the patient made another operation too dangerous, and conservative treatment was used. In this way the symptoms improved and the ulcer previously seen on a barium-meal examination was healed radiologically (Figs. 13 and 14).


#### *Histology*

In each case where tissue was available for investigation, chronic atrophic gastritis with gastric ulceration was found. In one patient, in addition to the gastric ulcer, a jejunal ulcer was also found. It is interesting to note that in this case a significant amount of normal fundic mucous membrane was still found in the portion of the stomach removed. It is obvious that this normal secreting mucous membrane was responsible for the jejunal ulceration in this patient (Fig. 5).

#### POSTOPERATIVE GASTRIC CARCINOMA

Three patients with postoperative gastric carcinoma were found in this series. All 3 patients were males and their average age was 53. The original operation was a gastro-jejunostomy for duodenal ulceration in 2 patients, and a Polya type partial gastrectomy for a histologically proved benign gastric ulcer in 1. The time since the original operation was an average of 30 years for the patients who had had a gastro-jejunostomy, and 11 years for the patient who had had a gastrectomy. Here again there is suggestive evidence that the pyloric antrum offers some protection against the development of this postoperative complication, and it confirms a previous report.<sup>5</sup>

The 2 patients whose carcinomas followed gastro-jejunostomies, developed their lesions in the pyloric antrum, whereas the carcinoma following gastrectomy developed in the cardiac portion of the stomach. The exact significance of this is uncertain, but it suggests that carcinoma occurs more readily in the pyloric or cardiac mucous membrane and that the fundic mucous membrane is more



resistant, although carcinoma may occur in that region of the stomach.<sup>5</sup>

#### Symptoms

The patient who developed a carcinoma in the cardiac portion of the stomach presented with dysphagia. One patient with a carcinoma following a previous gastro-jejunostomy presented with vomiting which only began once the carcinoma had obstructed the stoma. The remaining patient presented with epigastric pain and haematemesis, and it is significant that no obstructive symptoms were encountered because the stoma had not yet been obstructed.

#### Physical Examination

A palpable mass was found in one patient, but in the other two nothing abnormal was found on abdominal examination.

#### Special Examinations

**Barium meal.** The patient with the carcinoma in the cardia showed a filling defect in the cardiac end of the stomach and the lower portion of the oesophagus (Fig. 15). The patient who developed obstruction at the stoma following the previous gastro-jejunostomy showed this obstruction on barium-meal examination (Figs. 16 and 17). The third patient, who had a carcinoma in the pyloric antrum with no obstruction of the stoma, showed a normal gastro-jejunostomy, but the radiologist found it impossible to force barium through the pyloric end of the stomach.

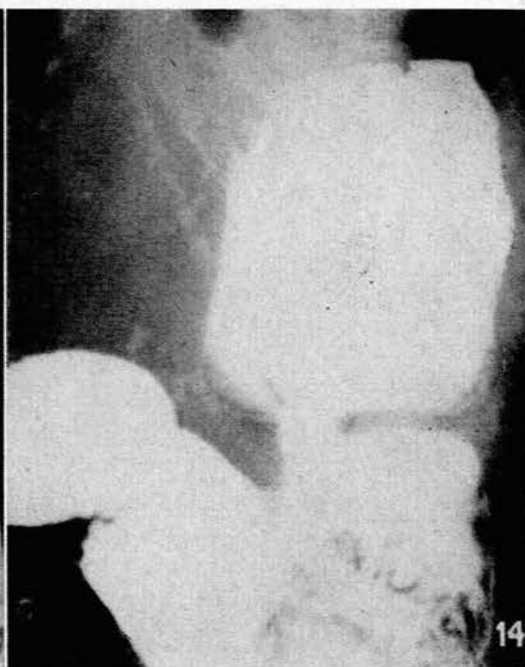
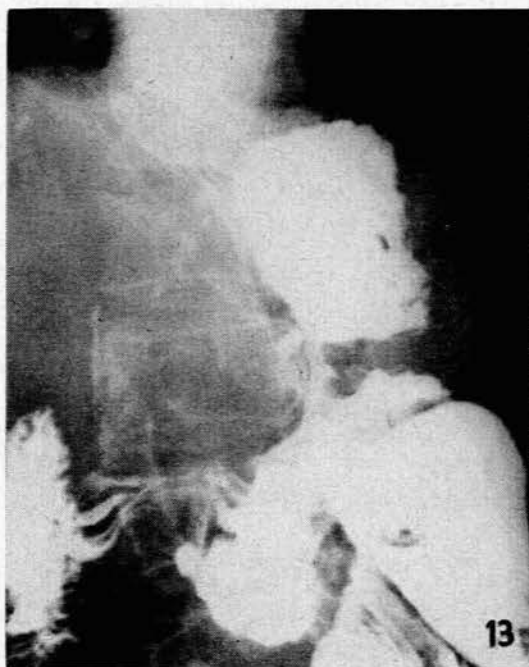

Fig. 13. A gastric ulcer on the lesser curve following a previous gastro-jejunostomy.

Fig. 14. A barium meal of the same patient as in Fig. 13 after medical treatment. The gastric ulcer has healed.

#### Treatment

Surgical resection was carried out in all 3 instances.

#### Histology

In all 3 patients the carcinoma was an adenocarcinoma occurring in a region of severe atrophic gastritis (Figs. 6 and 7).

#### STOMAL ULCERATION

The term 'stomal ulceration' is frequently used by the clinician as a generic term for postoperative ulceration,

The diagrams in Figs. 2-12 indicate the histological appearance of the gastric mucous membrane. Unless stated to the contrary, the specimens have been cut along the greater curvature.

The thick black line outlines the junction between pyloric and fundic mucosa; stippled area = normal gastric mucous membrane; interrupted transverse lines = duodenal mucous membrane; diagonal lines = chronic superficial gastritis; wavy lines = chronic atrophic gastritis; black areas = gastro-jejunostomy stoma; white areas = ulcers; square ruling = jejunum; and white triangles on a black background = adenocarcinoma.

Fig. 2. Reflux gastritis following a previous Billroth I gastrectomy.

Fig. 3. Reflux gastritis following a previous Polya type partial gastrectomy.

Fig. 4. Reflux gastritis following a previous Polya type partial gastrectomy (presented with haematemesis). The specimen consists of the anterior wall of the resected portion of stomach below and the posterior wall above the jejunum.

Fig. 5. A gastric ulcer in a region of chronic atrophic gastritis following a previous gastro-jejunostomy. This patient also had a jejunal ulcer.

Fig. 6. An adenocarcinoma in a region of chronic atrophic gastritis following a previous gastro-jejunostomy.

Fig. 7. An adenocarcinoma at the cardia following a previous gastrectomy. The gastric mucous membrane shows chronic atrophic gastritis and the carcinoma is extending up the lower end of the oesophagus.

Fig. 8. Stomach of patient with a jejunal ulcer following a previous gastro-jejunostomy for a duodenal ulcer. The fundic mucous membrane is normal and there is only a small area of atrophic gastritis affecting the pyloric mucous membrane.

Fig. 9. Stomach resected for a jejunal ulcer following a previous gastro-jejunostomy. There is an area of atrophic gastritis round the stoma, but most of the fundic mucous membrane is normal.

Fig. 10. Two jejunal ulcers following a previous partial gastrectomy. The fundic mucous membrane of the gastric stump is normal except for a few small spots of atrophic gastritis.

Fig. 11. Two jejunal ulcers following a previous partial gastrectomy. The fundic mucous membrane of the gastric stump is normal except for a few small spots of atrophic gastritis, and a black-silk stitch is present.

Fig. 12. Extensive atrophic gastritis following a previous gastro-jejunostomy and resulting in an ulcer just on the gastric side of the suture line.

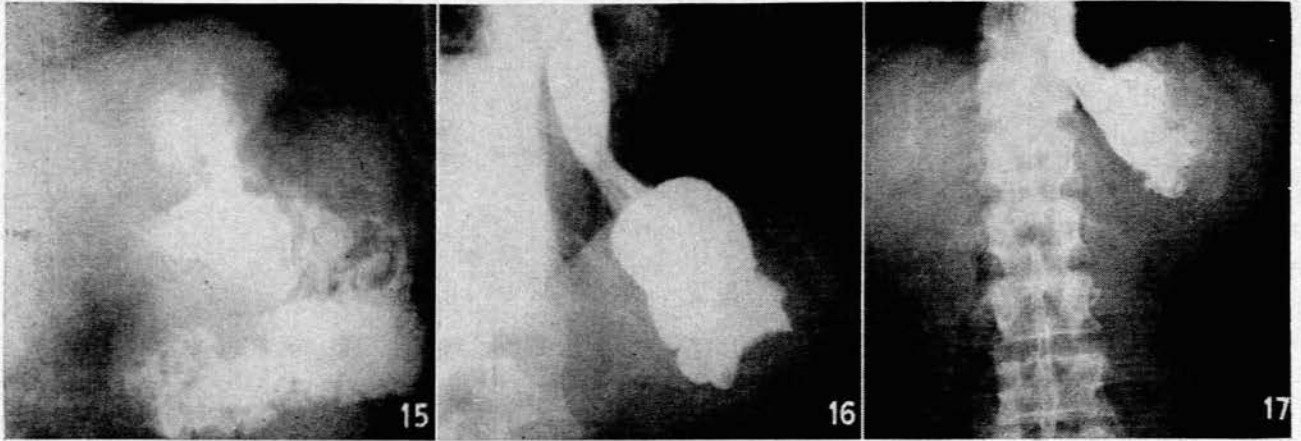


Fig. 15. A filling defect at the cardia produced by a carcinoma following a previous gastrectomy.

Fig. 16. Obstruction at the stoma of a gastro-jejunostomy caused by a carcinoma.

Fig. 17. Barium still remaining in the stomach 5 hours after the barium meal shown in Fig. 16.

but in actual fact it consists of 2 completely different types of cases:<sup>17</sup>

1. Ulceration in the jejunum close to the stoma. This is due to hypersecretion from the gastric remnant, and is therefore found in cases where many acid- and pepsin-secreting cells are left in the stomach. It is obvious that this type of ulceration is particularly likely to occur after any form of inadequate resection or after an inadequate vagotomy.

2. Gastric ulceration resulting from atrophic gastritis following on reflux of bile and pancreatic juice into the stomach.

In some instances the recurrent stomal ulcer can clearly be seen to be either gastric or jejunal. The gastric variety has been described above, and there were 4 patients with the jejunal variety in this particular series.

*Recurrent Ulceration clearly in the Jejunum following a Gastro-jejunal Anastomosis or in the Duodenum following a Gastro-duodenal Anastomosis*

All these patients were males with an average age of 61.5 years. This rather advanced age is important, because there is a common misconception that this type of disease occurs particularly in young people. It is important for the clinician to remember that jejunal ulceration does occur in elderly people, and a plain gastro-jejunostomy in this age group is therefore not a safe procedure in the treatment of duodenal ulceration.

All the operations had been performed for duodenal ulceration. One patient had a Billroth I gastrectomy, 2 had Polya gastrectomies, and 1 had a gastro-jejunostomy. The time interval since the previous operation averaged 13 months following the gastrectomies and 15 months following the gastro-jejunostomy.

The clinical picture of this type of condition is well known and will not be considered in any detail here. The cases conformed to the usual clinical condition of recurrence of epigastric pain after meals relieved by antacids and vomiting. The barium meal showed an ulcer in the jejunum in 2 of the 3 patients who had a barium-meal examination, and the maximum histamine test showed a high acid secretion.

The treatment consisted of a Polya gastrectomy for the patients with the Billroth I gastrectomy and with the gastro-jejunostomy. The patients with the Polya operation had a vagotomy performed.

The histological examination of the stomach of the patient who had had a gastro-jejunostomy previously showed a little reflux gastritis around the stoma, with a large amount of intact normal fundic mucous membrane. It is interesting to note that the pyloric mucous membrane had been largely destroyed, and this is possibly of some significance in the production of this condition (Fig. 8).

*True Stomal Ulcers*

In this category we include those ulcers occurring on the suture line between the stomach and the jejunum if a gastro-jejunal anastomosis has been performed, or on the junction between the stomach and duodenum if a gastro-duodenal anastomosis has been performed. These ulcers are difficult to classify as being either gastric or jejunal, and in this series 5 cases were encountered which fall into this category.

It is important to differentiate these true stomal ulcers into either gastric or jejunal ulcers, because, as we have seen, the one is a result of hypersecretion requiring a reduction in acid secretion for its treatment and prevention, and the other is due to reflux of bile and pancreatic secretion into the stomach, and its treatment will require excision of the ulcer and prevention of such further reflux.

Of these 5 true stomal ulcers, 3 were shown by histological methods to be jejunal ulcers, and the remaining 2 were gastric ulcers.

1. *Ulcers on the jejunal side of the stoma.* Of the 3 patients in this category, 2 were males and 1 was a female. The males were aged 26 and 29 respectively, and the female 49 years. The original operations were all performed for duodenal ulceration; 2 had a Polya type of gastrectomy and 1 a gastro-jejunostomy. The time intervals since the original operation were 6 months and 4 years respectively in the patients who had a gastrectomy, and 9 months in the patient who had originally had a gastro-jejunostomy. If these 3 patients are taken together with those patients who obviously had a jejunal ulcer, we find

that the 5 cases following a gastrectomy occurred after an average time interval of 19 months, whereas the 2 cases following a gastro-jejunostomy occurred after an average time interval of 12 months. In this small group of patients, therefore, it appears that jejunal ulceration does not occur later after a gastro-jejunostomy than after a gastrectomy, and this does not coincide with the experiences of other writers. Perhaps the present series is too small to be of any significance, but it is possible that other writers have included in this category those stomal ulcers on the gastric side of the stoma.

The clinical picture of these cases was the same as has been mentioned before, with postprandial pain relieved by vomiting and antacids. Barium-meal examination failed to demonstrate the ulcer in one instance and the maximum histamine test was uniformly high.

The treatment performed in this group of patients consisted of a gastrectomy for the patient who had had a gastro-jejunostomy and a higher gastrectomy with vagotomy in the 2 who had previously had a gastrectomy. The impression gained was that the 2 patients who had previously had a gastrectomy had too large a gastric remnant left. This was probably the cause of the recurrent stomal ulceration, and it was for this reason that a higher gastrectomy was performed.

Histological examination of the resected stomach of the patient who had previously had a gastro-jejunostomy showed a great deal of normal fundic mucous membrane, which is to be expected (Fig. 9). An important feature of this case is, however, that the pyloric mucous membrane had been severely damaged by gastritis. This again raises the possibility that the pyloric mucous membrane is in fact a protective mechanism and that the loss of this function will result in the development of a stomal ulcer. This may possibly be the explanation why in other reported series jejunal ulcers following gastro-jejunostomies occur much later than those following gastrectomies, in which of course the pyloric mucous membrane is removed at the time of the operation.

The resected portions of stomach and jejunum, removed for those ulcers occurring after previous gastrectomies, showed fairly normal fundic mucous membrane in the gastric remnant, and 2 ulcers in the jejunum, one close to the stoma on the jejunal side of the anastomosis, and the other a small distance further along (Figs. 10 and 11).

2. *Stomal ulceration on the gastric side of the anastomosis.* In this series 2 patients presented with a stomal ulcer which was shown to be just on the gastric side of the anastomosis. Both these patients had previously had a gastro-jejunostomy for a duodenal ulcer. Both were males, aged 52 and 55 respectively, and the original operation had been performed 20 and 22 years before.

The patients presented with epigastric pain aggravated by meals and not improved with antacids. In 1 patient the stomal ulceration produced obstruction of the afferent loop with the appropriate symptoms.

Barium-meal examination was normal in one case, but an ulcer was demonstrated in the other.

Both these patients were treated by partial gastrectomy of the Polya type.

Histological examination of the stomach, removed in one of these patients, showed a severe and extensive

atrophic gastritis leaving virtually no normal fundic mucous membrane in the portion of the stomach removed (Fig. 12). It is likely that similar trouble will follow on the gastrectomies performed, and it is probably wise in this type of case to perform a Roux-en-Y type of anastomosis with a 12-inch vertical limb to prevent further reflux.

#### DISCUSSION

The role of biliary and pancreatic reflux in the production of atrophic gastritis has been suggested before,<sup>21,22</sup> and many workers have reported this complication after gastric operations which allow such reflux by removing, destroying, or bypassing the pylorus.<sup>2,16</sup>

#### *Chronic Atrophic Gastritis*

For 2-4 weeks after such operations on the stomach there is an acute superficial gastritis with oedema, hyperaemia, and a purulent exudate which can give rise to severe pain. On one occasion this required a constant milk drip to alleviate the pain until the gastritis had subsided.<sup>6</sup> This acute phase is also presumed to be the cause of the occasional haemorrhage in the early postoperative period, as in the one patient described in this paper. After subsidence of this acute gastritis, the mucous membrane may return to normal or it may develop a chronic atrophic gastritis as a continuation of the acute process of the immediate postoperative period. This chronic atrophic gastritis is present in the majority of stomachs after such operations.<sup>16</sup> In some it appears as if this mucosal disease is static, as a balance is reached between the damaging effect of reflux and the remarkable regenerative power of the gastric mucous membrane, but in others it is a progressive condition producing the symptoms and complications mentioned in this article.

The incidence of such chronic atrophic gastritis after gastric operations seems high enough and sufficiently disabling to warrant its inclusion in the criteria used to assess the value of any given type of operation on the stomach. In the usual publications reporting follow-up studies of gastric operations, recurrent jejunal ulceration and dumping are the chief complications considered, but it is suggested here that gastric mucosal changes should be included in this type of study.

#### *Development of Carcinoma*

There can be no doubt that haemorrhage and gastric ulceration may occur as late complications of this chronic atrophic gastritis,<sup>8,9,14</sup> and the clinical presentations of these complications have been given above. There is, however, some uncertainty whether the development of a carcinoma is causally related to this phenomenon,<sup>1,10,15</sup> although it is easy to visualize how the vigorous regeneration of the foveolar cells, if persistent over a long period in response to the continuous necrobiotic effect of the trans-stomal reflux, can go on to neoplasia.<sup>7</sup> There are many authors who believe that the development of such a carcinoma is a direct result of this persistent regeneration.<sup>3,8,11-14,18,20,25</sup>

If this view is in fact correct, then the possibility should be kept in mind that performing an operation which will allow reflux, with its resultant chronic atrophic gastritis, may well predispose the patient to the development of a gastric carcinoma at a later date. In addition, the clinician should remember that the presence of chronic atrophic

gastritis after gastric operations may be pre-cancerous, and that either a corrective operation should be performed to stop such reflux, or the patient should be investigated regularly to recognize the onset of a carcinoma at an early stage when it is still surgically curable, as has been suggested for all patients with chronic atrophic gastritis.<sup>15</sup>

The development of a carcinoma of the stomach following a previous gastro-jejunostomy or partial gastrectomy may create a difficult diagnostic problem, and the clinical presentation will vary with the site of the carcinoma. As in the present series, the lesion often forms either in the pyloric antrum or the cardia.<sup>5</sup> If it is in the cardia, dysphagia is an early symptom, but if the carcinoma occurs in the pyloric antrum distal to the stoma, the symptoms may be vague and the barium meal will probably fail to enter the antrum, giving a radiological appearance similar to a gastrectomy. These cases may thus be missed by the clinician and the radiologist. It is always wise to regard recurrence of symptoms after a long silent period following a gastric operation with some suspicion, and if a barium meal is negative, a gastroscopy is indicated.

#### 'Stomal Ulceration'

As has been pointed out above, recurrent ulcers, although often grouped together under the term 'stomal ulceration', in fact include 2 distinct entities: those in the jejunum, and those in the stomach. The jejunal ulcers are obviously not for discussion in this paper, but must be differentiated from the gastric ulcers, which are similar to those gastric ulcers already mentioned. In some cases, as has been shown, the ulcer is on the suture line and it may be difficult to decide whether it is jejunal or gastric. Every effort should be made to differentiate between these lesions because jejunal ulceration is due to an excessive acid secretion, which must be reduced to achieve a cure, whereas gastric ulceration is due to biliary reflux, which must be prevented if a successful result is to be obtained.

#### Prevention of Reflux

Because this reflux gastritis can have such disabling and serious consequences, it is clearly advisable to avoid it as much as possible. No operation allowing reflux should be performed on the stomach unless it is absolutely necessary, and if such an operation becomes mandatory, all possible precautions should be taken to minimize or to avoid the reflux of the damaging bile and pancreatic secretion. It seems likely that a Hofmeister valve will prevent such reflux, although there is no proof of this.

A Roux-en-Y type of anastomosis will prevent such reflux completely, provided the vertical limb is at least 12 inches in length, but to avoid the higher incidence of jejunal ulceration found with this type of operation, it must be combined with a vagotomy. At present this procedure seems to be the ideal one for severe cases of reflux chronic atrophic gastritis and its complications, and

the results reported here are encouraging, although the series is small and the period of follow-up short. Thus far this procedure has only been used for patients with severe symptoms following a previous gastric operation, but one wonders whether it should not be considered at the time of the primary procedure, particularly for gastric ulcers, in which cases the acid is usually low and the gastric mucous membrane is already damaged. A Roux-en-Y anastomosis has been recommended before by different authors for bilious regurgitation,<sup>4,19,24,26</sup> but these authors do not make specific mention of the mucosal changes in the stomach. Reported results have been good when this anastomosis is used as a secondary procedure for those patients who require it for bilious regurgitation persisting for more than 2 years, but the operation is not recommended as a primary procedure.<sup>4</sup>

#### SUMMARY

The normal pylorus prevents reflux of bile and pancreatic secretion into the stomach. Any operation which interferes with this protective mechanism will allow reflux into the stomach and this will produce changes in the gastric mucous membrane. Thirty-six such cases are reviewed.

These patients presented with reflux gastritis, haemorrhage, gastric ulceration or gastric carcinoma. The clinical picture of each group is reviewed.

It is pointed out that some so-called stomal ulcers are in fact on the gastric side of the suture line and thus should also be included in this category.

This reflux can be prevented by means of a Roux-en-Y anastomosis, provided the vertical limb is at least 12 inches long. A vagotomy must be done with this procedure to prevent jejunal ulceration. The results of this operation are most encouraging, although the follow-up period is still short.

#### REFERENCES

- Barrett, M. K. (1946-7): *J. Nat. Cancer Inst.*, **7**, 127.
- Coghill, N. F. (1960): *Postgrad. Med. J.*, **36**, 733.
- Comfort, M. W., Butsch, W. L. and Eusterman, G. B. (1937-8): *Amer. J. Dig. Dis.*, **4**, 673.
- Conyers, J. H., Hall, R. A., Laing, D., Pulvertaft, C. N. and Wilson-Pepper, J. K. (1960): *Brit. J. Surg.*, **47**, 533.
- de Jode, L. R. (1961): *Ibid.*, **48**, 512.
- du Plessis, D. J. (1956): *Med. Proc.*, **2**, 29 and 77.
- Idem (1960): *S. Afr. Med. J.*, **34**, 101.
- Gilmour, J. (1961): *Brit. J. Surg.*, **49**, 278.
- Gray, H. K. and Lofgren, K. A. (1949): *Surg. Gynec. Obstet.*, **89**, 285.
- Guiss, L. W. and Stewart, F. W. (1943): *Arch. Surg.*, **46**, 823.
- Hurst, A. F. (1932): *Quart. J. Med.*, **1**, 157.
- Judd, E. S. (1942): *Surg. Gynec. Obstet.*, **75**, 424.
- Krause, U. (1958): *Acta chir. scand.*, **114**, 341.
- Magnus, H. A. (1937): *St. Bart. Hosp. Rep.*, **70**, 314.
- Morgenster, L. (1960): *Surgery*, **47**, 557.
- Palmer, E. D. (1954): *Medicine*, **33**, 199.
- Rivers, A. B. and Gardner, J. W. (1940): *J. Amer. Med. Assoc.*, **115**, 1779.
- Schindler, R. (1940-1): *J. Nat. Cancer Inst.*, **1**, 451.
- Schofield, J. E. and Anderson, P. St. G. (1953): *Brit. Med. J.*, **2**, 598.
- Shapiro, N., Schiff, L., Maher, M. M. and Zininger, M. M. (1942): *J. Nat. Cancer Inst.*, **2**, 583.
- Surola, M. and Tavast, M. (1956): *Acta med. scand.*, **153**, 451.
- Spira, J. J. (1956): *Gastro-duodenal Ulcer*. London: Butterworth.
- Stein, H. B. (1937): *S. Afr. J. Med. Sci.*, **2**, 117.
- Tanner, N. C. (1951): *Edinb. Med. J.*, **58**, 288.
- Warren, S. and Meissner, W. A. (1944): *Gastroenterology*, **3**, 251.
- Wells, C. and Johnson, J. H. (1956): *Lancet*, **2**, 479.