

TRAUMATIC PANCREATITIS COMPLICATED BY ENZYME-CONTAINING PLEURAL EFFUSION

LOUIS BLUMBERG (JNR.), M.B., CH.B. (CAPE TOWN), F.R.C.S. (ENG.), and LIONEL STEIN, M.B., CH.B. (CAPE TOWN), M.R.C.P. (LOND.), M.R.C.P. (EDIN.)

Somerset Hospital, Cape Town

As recent and authoritative a publication as *Clinical Gastroenterology*,¹ by Avery Jones and Gummer, makes no mention (in the section dealing with the pancreas) of the thoracic complications of pancreatitis. However, there is a gradually developing literature on this subject, mainly in American journals.

We report the following case of acute traumatic pancreatitis, caused by partial rupture of the pancreas following closed abdominal injury, and complicated by an enzyme-containing pleural effusion. Failure to recognize this complication may cause difficulty in diagnosis and management.

CASE REPORT

A 27-year-old African male was admitted to hospital after a fall in which he received a severe blow on the left side of his abdomen just below the costal margin.

When seen in consultation by one of us about 24 hours after the accident, he complained of epigastric pain radiating to the left side of the abdomen and through to the back. Although the pain was severe, it could not be described as agonizing. He had vomited once.

The blood pressure was 110/80 mm. Hg, the pulse rate was 80-90 a minute, and the haemoglobin level was 12 G. per 100 ml. There were no signs of surgical shock.

The abdomen moved poorly on respiration, and was slightly distended; there were abrasions over the costal margin on the left side. On palpation, tenderness and a rebound peritonitic sign could be elicited over the whole abdomen, the tenderness being most marked over the left rectus abdominis muscle just below the costal margin. In this area, too, there was guarding, but true rigidity was not a feature. On auscultation, the abdomen was completely silent.

The lung fields were clear both on clinical examination and on X-ray (Fig. 1), and free air could not be detected below the diaphragm.

A pre-operative diagnosis of intra-abdominal visceral injury was made, a partial rupture of the spleen seeming to be the most probable lesion. The absence of signs of severe blood loss, the lack of evidence of ruptured bowel, and the marked tenderness and minimal rigidity, all suggested the possibility of traumatic pancreatitis as well.

Operation (7 September 1961)

At laparotomy, through a left upper paramedian incision, a large haematoma was encountered within the rectus sheath. This was found to be due to complete transverse rupture of the left rectus muscle.

On opening the peritoneum, a heavily blood-stained serous effusion escaped and frank blood welled up on exploring the region of the spleen. The traumatic rupture of the left rectus muscle facilitated conversion of the paramedian incision to a T-incision by a transverse cut, and the improved exposure allowed the abdomen to be more thoroughly explored. The outstanding feature was very extensive and marked fat necrosis involving the greater omentum, the pancreas, and the lesser sac. The spleen was small and had a linear laceration on its convex surface.

On exploring the lesser sac, partial rupture of the body and tail of the pancreas was found. There was marked oedema and severe contusion, with a moderately large retro-peritoneal haematoma surrounding this part of the pancreas.

All the other viscera were intact.

Splenectomy was performed, and drainage of the lesser sac and splenic bed was established through an incision in the left flank. The left rectus muscle was repaired and the abdomen was closed in layers. The estimated loss of about 2½ pints of blood into the peritoneal cavity was replaced by transfusion.

Postoperative Course

The postoperative course was not smooth. Pyrexia, varying from 99°-102°F. was persistently present. Abdominal pain, though not severe, was troublesome, and a partial ileus added to the patient's discomfort. There was occasional vomiting.

The serum-amylase reading on 8 September was 628 Somogyi units per ml. (normal 70-200 units per ml.).

By the 6th postoperative day there were easily detectable signs of a large left pleural effusion (Fig. 2), but signs of underlying lung parenchymal involvement were absent. The effusion was aspirated, yielding a litre of straw-coloured non-haemorrhagic fluid which clotted. Its amylase content was 2,700 Wolgemuth units per ml. (normal 10 units per ml.). The fluid soon re-accumulated and the effusion persisted despite repeated aspirations. A chest film taken on 3 October illustrates this (Fig. 3).

Although we were unable to palpate a mass with any certainty, the probability of a pseudocystic collection of fluid in the lesser sac seemed high in view of persistent abdominal discomfort, the presence of so much amylase in the pleural effusion, and a serum-amylase level of 450 Wolgemuth units per ml. on 2 October. Moreover, the possibility of a sub-phrenic abscess could not be ruled out, especially in view of a white-blood-cell count at this stage of 22,000 per c.mm. Screening of the diaphragm was of no help, since the diaphragm was wholly obscured by the effusion.

Second Operation and Further Course

Exploration through a left subcostal incision was carried out on 5 October. Approximately 2 pints of turbid fluid were evacuated from the region of the body and tail of the pancreas. Drainage was established via a large tube drain, through which a small-bore catheter could be inserted for suction, if necessary. Examination of the fluid from the pseudocyst for amylase showed 8,000 Somogyi units per ml., while bacteriological examination, both direct and on culture, was negative.

From this point onwards there was a steady improvement. The pyrexia gradually subsided and the patient's general condition improved. Drainage from the pseudocyst was slight throughout, and skin excoriation did not occur.

The serum-amylase level on 16 October was 14 Wolgemuth units. The resolution of the pleural effusion proceeded *pari passu* with that of the pancreatitis. An X-ray film taken on 24 October showed marked improvement, while that taken on 3 November (Fig. 4)—one week after the patient was discharged from hospital—showed virtually complete resolution.

DISCUSSION

The intra-thoracic complications of pancreatic disease include a sluggish, elevated, or immobile diaphragm (usually the left leaf), interlobar adhesions, basal atelectasis, pneumonic infiltrates, and pleural effusions. During the 13-year period, 1946-1958, pulmonary abnormalities were detected

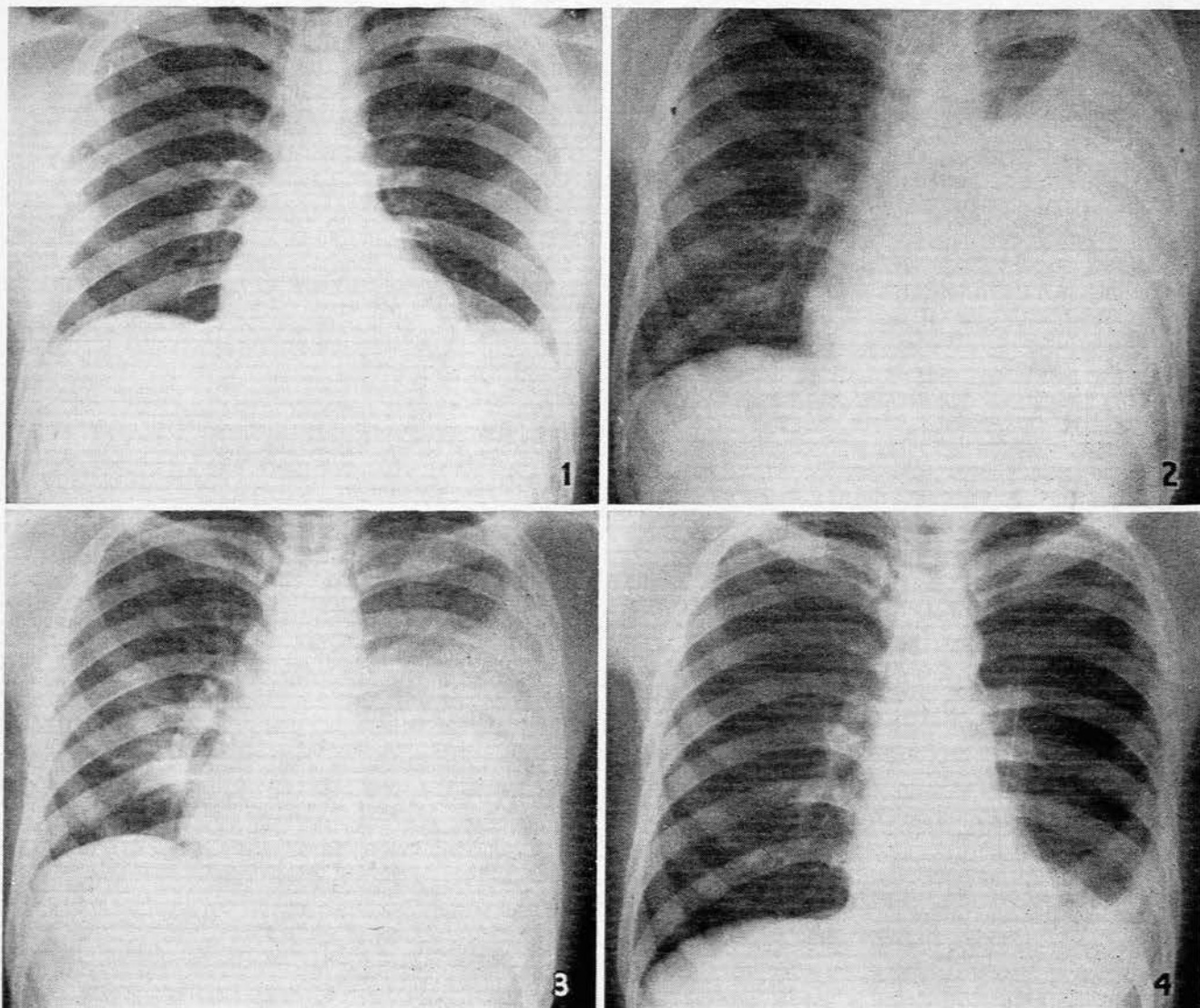


Fig. 1. Pre-operative chest film (5 September 1961).

Fig. 2. Chest film taken on the 6th postoperative day, showing large left pleural effusion (13 September).

Fig. 3. This shows the persistence of the pleural effusion despite repeated pleural aspiration (3 October).

Fig. 4. This shows virtually complete resolution of the pleural effusion following drainage of the pancreatic pseudocyst (3 November).

in 45 (or 20%) of 228 clinical attacks of pancreatitis in 205 patients in the New York Hospital.² Of these 45 pulmonary conditions, 15 were pleural effusions. The effusion is most often left-sided, but cases of right-sided or bilateral effusions have also been described. Hammarsten *et al.*³ collected 31 cases — 21 left-sided, 3 right-sided, and 7 bilateral.

Saunders and Lanzkowsky⁴ reported 2 cases of left-sided haemorrhagic effusion, but our patient, like the majority of others reported, did not have a haemorrhagic effusion. The patient reported by Juniper⁵ showed marked blood eosinophilia which seemed uniquely related to the pancreatic activity; our single differential white-cell count did not show an eosinophilia.

The outstanding feature of our case was the large amount of amylase in the pleural fluid. Juniper,⁵ Coffey,⁶ and Kalser *et al.*⁷ have also described this finding in their

cases, together with a high level of lipase. We did not estimate the lipase level in the case described, nor did we investigate for trypsin content, but from the fact that the fluid clotted we were inclined to deduce that trypsin was low or absent. In those cases where trypsin has been estimated, no increase has been found.

It is noteworthy that the concentration of amylase in our patient's pleural fluid was grossly in excess of that in the serum; this has been emphasized by Hammarsten *et al.*³ who described 4 cases of pancreatitis with a pleural effusion, in which the mean pleural fluid amylase level was 14,994 units per ml. compared with a mean serum level of 367 units per ml. In 12 cases of pleural effusion in the absence of pancreatic disease, however, they found that the pleural fluid amylase values were usually lower than those in the serum.

The most probable explanation for the difference in

values with pancreatic disease^{5,7} is the absorption of pancreatic ferments (liberated from the damaged pancreas) *via* the trans-diaphragmatic lymphatics from the abdomen to the pleural cavity. There is a sound anatomical basis for this hypothesis.⁸ The lymph vessels of the diaphragm form 2 plexuses, one on its thoracic surface and another on its abdominal surface. These plexuses anastomose with each other and are most prominent on the parts covered by the pleura and the peritoneum. The plexus on the abdominal surface is composed of fine vessels which anastomose at the periphery of the diaphragm with lymph vessels of the subperitoneal tissues.

In the case we described in this paper, the pleural effusion persisted until the pancreatic pseudocyst was drained externally. Kalsner *et al.*⁷ recorded the same experience. They regarded the pseudocyst as a reservoir of pancreatic ferments which are absorbed *via* the lymphatics, both into the blood stream and into the pleural fluid. They pointed out that the pseudocyst represents an *in vivo* equivalent of an *in vitro* experiment carried out by Bayliss and Starling in 1904, who demonstrated that when pancreatic juice is allowed to stand at 40°C. for a number of days activation of trypsinogen did not occur. This may account for the absence of increased trypsin in the pleural fluid where it has been sought, even though amylase and lipase are found in excess. However, we would point out that most of the reported cases, in which pleural effusion has been associated with pancreatitis, have not developed pseudocysts. A constant finding, however, has been continued activity of the process of pancreatitis and we believe that this is the essential feature in the persistence of the pleural effusion.

The cause of the pleural effusion in the case reported here was a diagnostic problem, until we checked the enzyme content of the pleural fluid. Up to then we had considered as possible underlying causes, postoperative pulmonary complications such as pneumonia, atelectasis, pulmonary infarction, and subphrenic abscess, none of which was found to be present. We should like to emphasize the recommendation of Roseman *et al.*² that careful radiological study of the lung fields be made in cases of pancreatitis, and, furthermore, where a pleural effusion is present without apparent explanation, the enzyme concentration be estimated, since a disproportionate rise above the serum-amylase level probably indicates the presence of associated active pancreatitis. In the case reported by Roseman *et al.*² the underlying pancreatitis remained undiagnosed for a long time.

The pancreas, because of its anatomical situation, is well protected from non-penetrating abdominal injuries, the incidence being in the region of 1%.^{9,10,13,14} Any closed trauma severe enough to injure the pancreas will usually cause damage to adjacent viscera, and it has been observed¹¹ that non-penetrating injuries of the pancreas are very rarely isolated ones. It is of interest to note in passing that the first reported case of subcutaneous injury to the pancreas appeared in *The Lancet* in 1827 (quoted by Culotta *et al.*¹²). The pancreas, though well protected from non-penetrating abdominal injuries, may be damaged during the course of upper abdominal surgical operations.

We refer particularly to possible damage to the tail of the pancreas during splenectomy.

Left-sided pleural effusion is a recognized postoperative complication of splenectomy, listed in current textbooks of surgery.^{15,16} The explanation usually offered is that pleural effusion follows on sub-diaphragmatic pathology, including such conditions as haematoma, subphrenic abscess, and trauma from freeing of adhesions. There is no doubt that such lesions may well be the cause of pleural effusion following splenectomy, but we put forward as a rational explanation that at least in some instances inadvertent damage to the tail of the pancreas at operation may produce a traumatic pancreatitis which results in a left-sided pleural effusion in the manner described above. Therefore we suggest that when a pleural effusion complicates splenectomy, the enzyme content be estimated to exclude possible pancreatic damage as the underlying cause.

SUMMARY

1. Attention is drawn to the occurrence of intrathoracic complications of pancreatitis with special reference to pleural effusions.

2. A case of traumatic pancreatitis is described in which a left-sided pleural effusion occurred, the amylase content of which was extremely high, and much higher than that of the serum.

3. The literature of enzyme-containing pleural effusions complicating pancreatitis is briefly reviewed. Emphasis is given to the suggestion that the amylase content of obscure pleural effusions be estimated, in view of the possibility of uncovering an unsuspected pancreatic cause.

4. The suggestion is put forward that the pleural effusions which may complicate the postoperative course of splenectomy also be examined for enzyme content, since such effusions may possibly be caused by traumatic pancreatitis (through inadvertent damage at operation) with subsequent absorption of enzymes through trans-diaphragmatic lymphatics into the pleural space.

We thank Dr. J. Mervis for referring this patient to us, and Dr. G. J. Joubert, Superintendent of Somerset Hospital, Cape Town, for permission to use the hospital records.

REFERENCES

1. Avery Jones, F. and Gummer, J. W. P. (1960): *Clinical Gastroenterology*: Oxford: Blackwell Scientific Publications.
2. Roseman, D. M., Kowlessar, O. D. and Slesinger, M. H. (1960): *New Engl. J. Med.*, **263**, 294.
3. Hammarsten, J. F., Honska, W. L. jnr. and Limes, J. (1959): *Amer. Rev. Tuberc.*, **79**, 606.
4. Saunders, S. J. and Lanzkowsky, P. (1956): *S. Afr. Med. J.*, **30**, 1069.
5. Juniper, K. (1955): *Amer. J. Med.*, **19**, 648.
6. Coffey, R. J. (1952): *Ann. Surg.*, **135**, 715.
7. Kalsner, M. H., Roth, J. L. A. and Bockus, H. L. (1955): *Gastroenterology*, **28**, 842.
8. Johnston, T. B., ed. (1938): *Gray's Anatomy*, 27th ed., p. 876. London: Longmans Green & Co.
9. Clarke, R. (1954): *Lancet*, **2**, 877.
10. Allen, R. B. and Curry, G. J. (1957): *Amer. J. Surg.*, **93**, 398.
11. Blandy, J. P., Hamblen, D. L. and Kerr, W. F. (1959): *Brit. J. Surg.*, **47**, 156.
12. Culotta, R. J., Howard, J. M. and Jordan, G. L. (1956): *Surgery*, **40**, 320.
13. Maingot, R. (1948): *Abdominal Operations*, 2nd ed. London: H. K. Lewis.
14. Griswold, R. A. and Collier, H.S. (1961): *Surg. Gynec. Obstet.*, **112**, international abstracts of surgery, p. 309.
15. Aird, I. (1957): *Companion in Surgical Studies*, 2nd ed., p. 1055. Edinburgh and London: E. & S. Livingstone.
16. Rogers, L., ed. (1955): *Grey Turner's Modern Operative Surgery*, 4th ed., p. 1015. London: Cassell.