

# THE MAST CELLS AND MASTOCYTOSIS\*

WITH SPECIAL REFERENCE TO BONE CHANGES

FELIX SAGHER, M.D. and ZVI EVEN-PAZ, M.B., CH.B.

*Department of Dermatology and Venereology, Hadassah University Hospital, Jerusalem, Israel*

Paul Ehrlich was the first to describe the mast cells clearly. What is more, he did this in his first scientific paper which was published in 1877 when he was still a 23-year-old student.<sup>1</sup> His paper contained a plate of drawings of granular cells stained with aniline dyes, and he described their metachro-

\* Guest lecture presented at the Congress of the Dermatological Sub-Group (M.A.S.A.), Cape Town, 17 April 1960.

matic staining with dahlia violet. Two years later he gave these cells a name.<sup>2</sup> Influenced by the fact that they were most numerous where there was increased local nutrition as a result of chronic inflammation or lymph stasis, he believed them to be overnourished cells, and therefore called them 'mast cells'. In the same way an overfed goose is known in many parts of Europe as a 'gemästete Gans'.

How these mast cells fitted into the human economy,

however, was completely unknown, and it was not until 10 years later that Unna<sup>3</sup> described the accumulation of these cells in the lesions of a rare skin disease called urticaria pigmentosa or 'Nettleship's disease'. This disease was first described in 1869 by the young British doctor, Nettleship,<sup>4</sup> who later became an ophthalmologist. He presented the case of a 2-year-old girl with an unusual form of urticaria in which the wheals were very persistent and left a light-brown hyperpigmentation. Rubbing the lesions caused urtication.

Both this disease and the mast cell itself remained medical curiosities. Only in the last 10 or 20 years has more light been shed on these subjects. The 'riddle of the mast cell' has by no means been solved, but it is proving to be one of the most fascinating of the cells found in animal connective tissue. In fact, it seems to have been something of a dark horse; it may yet prove to be a master cell of the connective tissue.

The chief characteristic of the mast cell is the presence in its cytoplasm of granules which stain metachromatically. By this is implied that the granules change the colour of the dye used in staining them.

Recent biochemical and histochemical studies have suggested an impressive number of possible functions for the mast cell. Since these cells are present in any area of connective tissue, and since connective tissue is so widely distributed, their physiologic activity is of great interest. This is especially so now that it is known that hormones such as the steroids exert their effects largely as a result of connective-tissue response. It seems that the mast cells produce or store in their granules a number of powerful substances. These seem to be similar to or identical with heparin,<sup>5</sup> hyaluronic acid<sup>6</sup> and histamine.<sup>7</sup> It has been claimed with less convincing evidence that serotonin, or 5-hydroxy-tryptamine, is also contained in mast cells.<sup>8</sup> These agents may be released by simple extrusion of granules, new ones forming within the cell, or sometimes as a result of total disintegration of the cell.

#### FUNCTIONS OF MAST CELLS

The following is a list of possible functions of mast cells related to a knowledge of the actions of these various chemicals:

##### 1. Heparin production

- (a) Prevention of blood coagulation
- (b) Local detoxification
- (c) Formation of collagen
- (d) Inhibition of hyaluronidase
- (e) Metabolism of fats

##### 2. Hyaluronic-acid production

- (a) Integrity of the ground substance

##### 3. Histamine production

- (a) Activation of defence and repair mechanisms (?)

##### 4. Serotonin production (?)

##### 1. Heparin Production

(a) *Prevention of blood coagulation.* The mast cell has been regarded as a single-celled endocrine gland pouring heparin into the blood stream. Although there is usually no obvious bleeding tendency in urticaria pigmentosa, and blood coagulation studies are often quite normal, cases have been described in which there were petechial eruptions and large purpuric areas in and around the lesions.

A case in a child, reported by Waters and Lacson,<sup>9</sup> is of especial interest. The child developed cutaneous lesions of urticaria pigmentosa in the first week of life. From the age of 3 years there was a tendency to bruise easily and a difficulty in arresting haemorrhage after minor trauma. The child developed leukaemia, in which tissue mast cells appeared in the blood. Bleeding time became prolonged and the prothrombin activity was reduced. Death occurred following the rupture of a large subcapsular haematoma in the liver. At autopsy the blood in the peritoneal cavity was found to be entirely fluid, and no clot had formed.

Some experiments on hibernating animals are relevant in this respect.<sup>10</sup> It is known that the blood-clotting time of these animals is short during the active summer period and prolonged during winter hibernation. Bats in summer were kept under temperature conditions of 5°C. Their blood-clotting time increased, and so did the number of mast cells in the duodenum. When winter bats were exposed to a temperature of 23°C, the reverse was observed. It seemed that the alterations in clotting time were at least partly determined by the availability of mast-cell heparin.

(b) *Local detoxification.* The theory has been advanced that heparin or related substances may neutralize noxious amines resulting from cell death, metabolic processes, or other factors.<sup>11</sup> The complexes formed are then taken up by ordinary fibroblasts. This theory is based on some well-conducted experiments.

(c) *Formation of collagen.* It has been shown that heparin can precipitate collagen fibrils from procollagen,<sup>12</sup> which may be secreted by fibroblasts in the inflammatory response. However, a number of other substances besides heparin may also cause such precipitation of collagen fibrils.

(d) *Inhibition of hyaluronidase.* Heparin is capable of inhibiting the action of hyaluronidase. This may indicate that mast cells play a part in the defence of the connective tissue against bacterial invasion or the spread of malignant tumours.

(e) *Fat metabolism and atherosclerosis.* Heparin seems to be concerned in the normal transport and metabolism of fat by stimulating 'clearing factor' production. This factor breaks up the large emulsified fat droplets in the blood stream, thus facilitating the passage of neutral fat through the capillary walls.<sup>13</sup> It has been further shown, as a result of animal experiments and a study of human autopsy material, that subjects with marked atherosclerosis have significantly reduced mast-cell counts in the cardiac muscle and other tissues.<sup>14</sup> The autopsy reports so far published on patients dying from malignant mastocytosis have made no special comment on the presence or absence of atherosclerosis, even in aged persons. It might be of value if in future special attention was paid to this aspect.<sup>15</sup>

##### 2. Hyaluronic-acid Production

The opinion that hyaluronic acid is secreted by mast cells is based on a good deal of experimental evidence. Any increase in water content of the ground substance of connective tissue seems to cause an increase in the number of mast cells, which then undergo disruption. The hyaluronic acid liberated converts the free water into a hydrated gel and a perivascular oedema is changed into a mucinous material. Thus the physicochemical integrity of the ground substance is preserved.

##### 3. Histamine Production

Although histamine has well-known and powerful pharmacological actions, its place in normal physiology is not clear.

Its release from mast cells in response to trauma or other damage to the tissues might flood the areas with protein-rich oedema fluid as a result of increased vascular permeability. This might then mobilize the fixed tissue cells before the process of repair.

The urticaria which may occur on rubbing the lesions of urticaria pigmentosa is most easily explained on the basis of the local liberation of a histamine-like substance. There have also been reports of more generalized disturbances in this disease attributed to release of histamine. These include attacks of generalized flushing, either spontaneously or as a result of irritation of the lesions. More severe disturbances resembling 'histamine-shock', sometimes with loss of consciousness, have also been described. In some cases such attacks ceased after excision of a large, active, mast-cell tumour.<sup>16</sup> More attention has been paid to this peculiar, but rare, associated phenomenon in recent years, and some cases have been described in South Africa.<sup>17</sup> In some of the cases the histamine content of the lesions, the blood, and the urine was much increased.

#### 4. Serotonin Production

It is less certain whether serotonin (5-hydroxy-tryptamine, 5-HT) is contained in human mast cells, although it seems to be present in the mast cells of rats. This substance is present in the enterochromaffin cells of the intestinal tract and in carcinoid tumours of these cells. It is also found in blood platelets and in some cells of the nervous system. The symptoms of the release of serotonin include, among others, such vasomotor disturbances as generalized flushing. It also causes intestinal hypermotility, and in this respect it is of interest to note that abdominal pain and diarrhoea have often been found in association with urticaria pigmentosa.

However, there is no clear evidence of raised serotonin levels in either the lesions or the blood of patients with this disease, nor has there been an increase of its metabolic end-product in the urine of these patients. Further investigation is therefore necessary to decide whether serotonin, either alone or combined with histamine, plays any part in the many-faceted symptomatology of mastocytosis.

#### Summary of Functions

So far as present knowledge goes, mast cells may be considered as unicellular endocrine glands. They apparently secrete a number of very powerful agents—heparin, hyaluronic acid, histamine, and possibly serotonin—mainly as part of the mesenchymal reaction in time of stress. The cells respond both to local tissue changes and to alterations in the general balance of the body hormones.

#### URTICARIA PIGMENTOSA OR MASTOCYTOSIS

This disease, like the mast cell itself, has emerged from relative obscurity only in the last decade. In spite of earlier reports of occasional enlargement of lymph glands and rather vaguely defined blood disturbances, we were all taught that this disease was a mere dermatological curiosity with no real significance as regards the general health of the patient. Most cases still do seem to be confined to the skin and to be entirely benign, but each year further cases are reported in which systemic involvement has been detected. This systemic involvement may also be benign, but it occasionally takes a malignant course and may prove fatal. At least 12 fatal cases have been described.

The systemic involvement takes the form of mast-cell infiltrations in the lymph nodes, liver, spleen, bones, haemopoietic system, and sometimes other organs.<sup>18</sup> Lupus erythematosus was once also considered a purely dermatological condition; then it was found not only to have possible systemic associations, but also to exist in a purely systemic form without skin lesions. By analogy it was prophesied that one day a purely systemic form of urticaria pigmentosa would be detected. Such cases without any cutaneous involvement have now been described, e.g. a purely 'splenic mastocytosis',<sup>19</sup> and a condition of 'mast-cell leukaemia'.<sup>20,21</sup> Therefore, the use of the general term 'mastocytosis' instead of urticaria pigmentosa seems fully justified.

Recent literature contains a number of excellent short surveys on urticaria pigmentosa, and among the best of these is certainly that of Marshall *et al.*<sup>17</sup> These authors proposed an interesting system of classification of the mastocytoses. We, too, had been thinking on somewhat similar lines and the following is the result of such an attempt at classification:

#### 1. Cutaneous mastocytoses

- (a) Localized
  - (i) Solitary mastocytoma
  - (ii) Grouped lesions
- (b) Disseminated (benign urticaria pigmentosa)
  - (i) Juvenile type
  - (ii) Adult type
- (c) Diffuse (mastocytose diffuse cutanée)

#### 2. Cutaneo-systemic mastocytosis

Any of the forms listed under cutaneous mastocytosis, with associated mast-cell invasion of lymph nodes, liver, spleen, bones, haemopoietic system, etc.

- (a) Benign
- (b) Malignant

#### 3. Systemic mastocytosis

Involvement of the above-mentioned structures, together with the viscera, but without lesions of the skin.

It is now clear that the complete and accurate diagnosis of a case of urticaria pigmentosa or mastocytosis must be based, in addition to the dermatological examination, upon a thorough general clinical examination; a full haematologic study, including that of the coagulation mechanism; an examination of the bone marrow or histologic study of a bone biopsy specimen; and a complete radiological study of the entire skeleton.

Although there were earlier hints and suggestions that urticaria pigmentosa might in some way be a systemic disease, these have only recently been substantiated. In 1949 Ellis<sup>22</sup> reported on an autopsy performed on a one-year-old child who died in the active stage of the disease. During life there had been no suspicion of systemic involvement, but the postmortem examination revealed numerous mast-cell infiltrations in the bone marrow, thymus gland, liver, spleen, pancreas, and lymph nodes.

Tissue mast cells in the blood were first described by Hissard and co-workers<sup>23</sup> in 1950, in a case with the diffuse type of skin involvement. Although the usual number of mast cells in the circulating blood was only 1-2%, they rose to 45% following splenic puncture, which presumably induced contraction of the spleen. The patient eventually died.



### Bone Changes

The existence of widespread bone changes in a patient with urticaria pigmentosa was first demonstrated by X-ray examination in 1950 in Israel.<sup>24</sup>

The patient was a 53-year-old man whose widespread skin lesions had appeared 4 years earlier. He was admitted to hospital for thorough general examination. An X-ray picture of the chest showed that the ribs were involved by a cystic osteoporotic process, with punched-out areas and thickening of the trabeculae. The changes resembled those seen in multiple myeloma or metastatic carcinoma.

Since the pattern of the X-ray shadows was reminiscent of that produced on the skin by the pigmented lesions, it was thought that they might be due to the same process. Sclerotic bone changes were found in the skull, the pelvis and the lumbar vertebrae. The bones of the extremities seemed unaffected. No mast cells were detected in the bone marrow and the patient refused to allow diagnostic costotomy. Follow-up X-ray studies performed over a period of 7 years revealed progression of the sclerotic process in the bones, even though the patient remained in relatively good general health.

The late Dr. Charles C. Rein of New York visited our clinic and saw this patient. On his return to the USA he re-examined all his patients with urticaria pigmentosa, and together with Dr. Clyman<sup>25</sup> reported a case of this disease with localized bone changes. They suggested that a central registry should be set up in Jerusalem to which reports on skeletal studies in urticaria pigmentosa might be forwarded.

As a result of cases reported to this registry,<sup>26</sup> and of others described in the literature, it seems that a total of well over 30 cases of this disease with osseous changes have been detected since 1952. It is not possible to be certain how many cases there have been in which X-ray studies were performed, but showed no changes, since many of these will have gone unreported. Two out of 20 cases examined in our clinic had bone changes.

The second of these 2 patients is of especial interest.<sup>27,28</sup> She was a 55-year-old woman with urticaria pigmentosa of the maculopapular type, of 5 years' duration. Her general health, at first, was good. Skeletal X-ray examination, which was a routine procedure since the finding of bone changes in the first patient, showed that she, too, had generalized bone changes. This patient was under observation for 2½ years. Then, her general health suddenly deteriorated and she developed a high fever and died with a clinical picture of monocytic leukaemia.

A comparison of the first X-ray pictures with those taken shortly before her death, showed that there had meanwhile been a marked progression of the sclerotic changes, both in the areas originally affected and in bones which had previously appeared normal. Thus, in the earlier pictures the margins of the inner and outer tables of the skull were distinct, and islets of increased density could be seen scattered throughout the bones. In the later X-ray pictures islets could not be seen, for the outer and inner tables now formed one continuous undifferentiated sclerotic mass. In the later pictures the previously

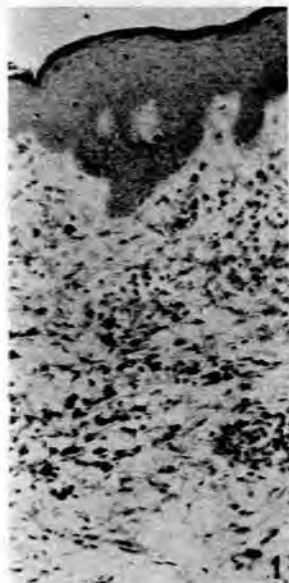


Fig. 1. Cutaneous lesion from a patient with mastocytosis. Mast cells are dispersed throughout the middle and upper dermis. One month later the patient died from monocytic leukaemia (toluidine blue  $\times 470$ ).

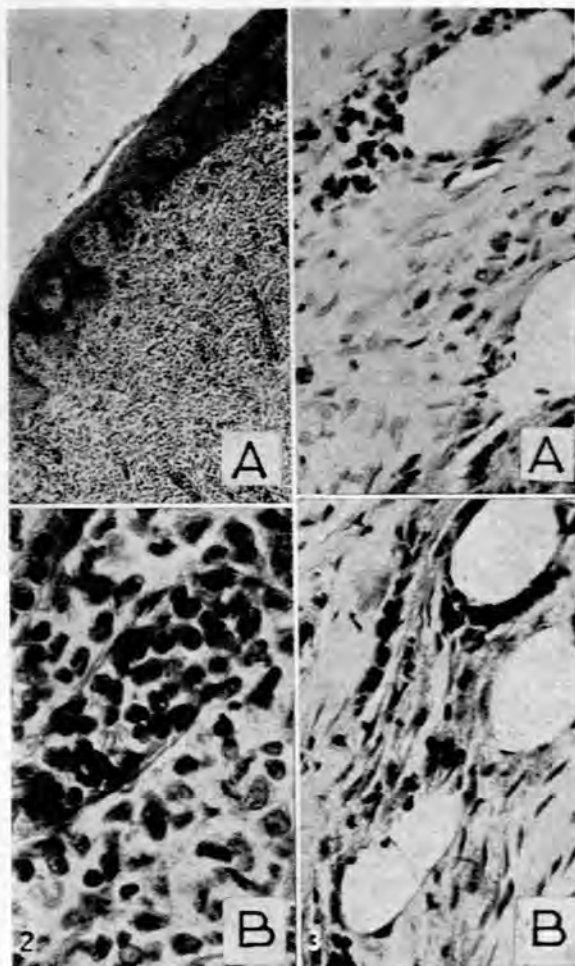


Fig. 2. Same patient as Fig. 1. Cutaneous lesion removed at autopsy. A. Low power. There is a dense cellular infiltration of the entire dermis (toluidine blue  $\times 125$ ). B. High dry power. The infiltrate consists of monocytes, with intermingled mast cells.

Fig. 3. Same patient as Fig. 1. Lumbar vertebra. A and B. Aggregations of tissue mast cells in the bone marrow. Mast cells are also seen lining large, empty, vascular spaces (toluidine blue  $\times 400$ ).

normal-looking distal portions of the radius and ulna, and the carpal and metacarpal bones, were seen to have become involved by the same sclerotic process.

Shortly before death the patient developed a leukocytosis, rising to 248,000 white blood cells per c. mm. Seventy-eight % of the cells were monocytes, some of which were classed as 'atypical'. Autopsy studies confirmed the clinical diagnosis, and proved that the changes in the bones seen at X-ray were indeed due to mast-cell infiltrations. Many of the marrow spaces were either completely fibrosed or were filled with accumulations of mast cells. These cells were also present within large, empty, vascular spaces (Figs. 1—5).

The bone changes so far described in mastocytosis may be classified in two groups: Generalized or diffuse involvement, and localized involvement.<sup>29</sup>

In *generalized or diffuse involvement*, exemplified by the cases I have described, the lesions seen in the X-ray pictures are diffusely scattered throughout the affected bones. The bones most frequently affected are those of the central column of the body—i.e. the skull, vertebrae, ribs and pelvis. Nearly all the patients in which this type of involvement has been described were over 30 years of age.

In *localized involvement*, the changes are seen as localized areas, sometimes with a sharply 'punched-out' appearance,

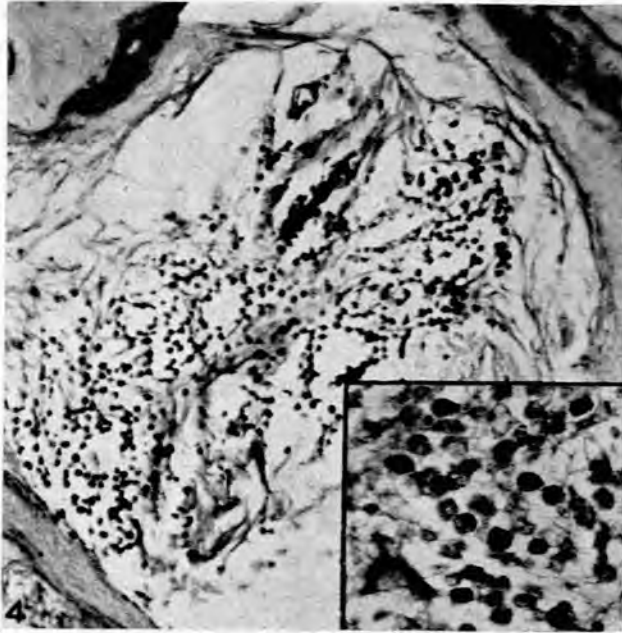


Fig. 4. Same patient as Fig. 1. Lumbar vertebra. Accumulation of mast cells in marrow space, which also shows early fibrosis (toluidine blue  $\times 105$ ). Inset: Typical mast cells in the marrow space ( $\times 370$ ).

confined to one part of the affected bone. The skull and the bones of the extremities have shown such lesions, but the ribs and vertebrae are usually not involved. This type of bone lesion has been described in children as well as in adults.

#### Treatment

On the subject of the treatment of mastocytosis I will say little. Much has been tried, but, in general, with far from satisfactory results. Antagonists of heparin, histamine, hyaluronic acid, and serotonin have been tried, in addition to steroids, radiation therapy, and many less specifically directed procedures. The chief importance of treatment once seemed to be only cosmetic, but now that possible systemic and fatal developments must be considered, the search for effective treatment takes on a new urgency.

It seems likely that the solution will be linked to a greater understanding of the 'riddle of the mast cell'.

#### SUMMARY

1. The possible functions of the mast cells are discussed.
2. Their association with urticaria pigmentosa is described.
3. The disease urticaria pigmentosa, or mastocytosis, is described in detail and a tentative classification of the mastocytoses is given. The widespread nature of mastocytosis is stressed, with special reference to the bone changes and the possibility of malignancy.
4. The unsatisfactory nature of the available treatment of mastocytosis is mentioned, and the urgency of finding effective treatment is stressed.

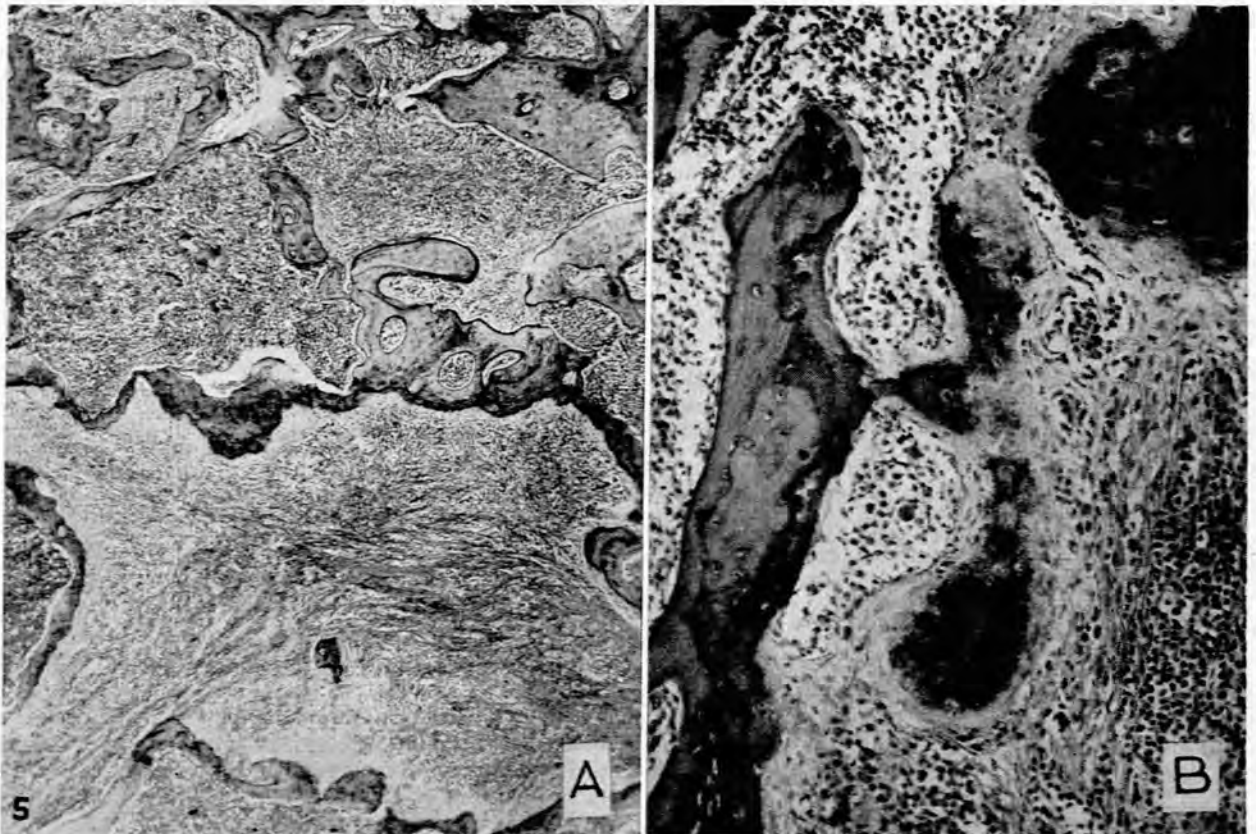


Fig. 5. Same patient as Fig. 1. Lumbar vertebra. A. The marrow spaces show fibrosis and contain an accumulation of mast cells (haematoxylin and eosin  $\times 33$ ). B. Higher magnification. The irregularly thickened trabeculae consist of a deposition of immature markedly basophilic, fibrillary bone upon the mature bone ( $\times 160$ ).

## REFERENCES

1. Ehrlich, P. (1877): Arch. mikr. Anat., **13**, 263.
2. *Idem* (1879): Arch. Anat. Phys. (Physiol. Abt.), 166.
3. Unna, P. G. (1887): Mh. prakt. Derm., **6**, 1.
4. Nettleship, E. (1869): Brit. Med. J., **2**, 323.
5. Jorpes, J. E., Holmgren, H. and Wilander, O. (1937): Z. mikr. anat. Forsch., **42**, 279.
6. Asboe-Hansen, G. (1950): Acta dermat.-venereol. (Stockh.), **30**, 221.
7. Riley, J. F. and West, G. B. (1952): J. Physiol. (Lond.), **117**, 728.
8. Benditt, E. P., Wong, R. L., Arase, M. and Roeper, E. (1955): Proc. Soc. Exp. Biol. (N.Y.), **90**, 303.
9. Waters, W. J. and Lacson, P. S. (1957): Pediatrics, **19**, 1033.
10. Smith, D. E., Lewis, Y. S. and Svihla, G. (1954): Proc. Soc. Exp. Biol. (N.Y.), **86**, 473.
11. Higginbotham, R. D., Dougherty, T. F. and Jee, W. S. S. (1956): *Ibid.*, **92**, 256.
12. Morrione, T. G. (1952): J. Exp. Med., **96**, 107.
13. Lindgren, F. T., Nichols, A. V. and Freeman, N. K. (1955): J. Phys. Chem., **59**, 930.
14. Cairns, A. and Constantinides, A. (1954): Science, **120**, 31.
15. Sagher, F. and Even-Paz, Z.: In *Mast Cells and Mast Cell Disorders*. Basel S. Karger (to be published).
16. Bloom, G., Dunér, H., Pernow, B., Winberg, J. and Zetterström, R. (1958): Acta Paediat., **47**, 152.
17. Marshall, J., Walker, J., Lurie, H. I., Hansen, J. D. L. and Mackenzie, D. (1957): S. Afr. Med. J., **31**, 867.
18. Berlin, Ch. (1955): A. M. A. Arch. Derm., **71**, 703.
19. Ende, N. and Cherniss, E. I. (1958): Blood, **13**, 631.
20. Efrati, P., Klajman, A. and Spitz, H. (1957): *Ibid.*, **12**, 869.
21. Friedman, B. I., Will, J. J., Frieman, D. G. and Braunstein, H. (1958): *Ibid.*, **13**, 70.
22. Ellis, J. M. (1949): A. M. A. Arch. Path., **48**, 426.
23. Hissard, R., Moncourier, L. and Jacquet, J. (1950): C. R. Acad. Sci. (Paris), **231**, 253.
24. Sagher, F., Cohen, C. and Schorr, S. (1952): J. Invest. Derm., **18**, 425.
25. Clyman, S. G. and Rein, C. R. (1952): *Ibid.*, **19**, 179.
26. Sagher, F. and Schorr, S. (1956): *Ibid.*, **26**, 431.
27. Sagher, F., Liban, E., Unger, H. and Schorr, S. (1956): *Ibid.*, **27**, 355.
28. Schorr, S., Sagher, F. and Liban, E. (1956): Acta radiol. (Stockh.), **46**, 575.
29. Sagher, F. (1957): Acta dermat.-venereol. (Stockh.), Proc. 11th. Internat. Congr. Dermat. II, 115.