

# DIVERTICULAR DISEASE OF THE COLON

J. A. MYBURGH. M.B., CH.B. (CAPE TOWN), F.R.C.S. (ENG.), *Department of Surgery, University of the Witwatersrand, and the Johannesburg General Hospital, Johannesburg*

## PART III

### THE RADIOLOGICAL DIAGNOSIS OF DIVERTICULITIS

As was expected, the literature on the radiological diagnosis of diverticulitis is replete with confusing and contradictory statements. Demonstration of diverticula of the colon is reasonably simple either on barium-enema or barium-meal examination, but contradictory statements are rife when it comes to the criteria for diagnosing the presence of complicating inflammation. This is one of the main reasons why estimates of the incidence of this complication are so divergent.

Some of the pioneer work on the radiology of this condition

was done by Spriggs and Marxer<sup>10-12</sup> from 1925 to 1929, and the stages in the development of the condition as postulated by them are still widely accepted: (1) The prediverticular stage, (2) established diverticulosis, and (3) diverticulitis.

The prediverticular stage is said to be recognized by 'fine spastic notches either grouped on the summits of the haustral bulges, or replacing these bulges'. Fig. 7 is a diagrammatic representation of this stage after Spriggs and Marxer, and the transverse colon in Fig. 8 could be considered to show the features of 'prediverticulosis'. The notches are claimed to be

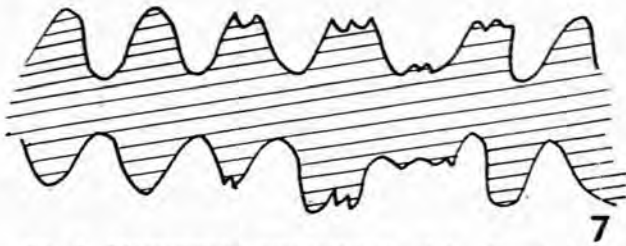


Fig. 7. Diagrammatic representation of 'prediverticulosis' (after Spriggs and Marxer).

incipient hernial pouches of colonic mucosa through the muscularis, and it is alleged that follow-up of these cases will

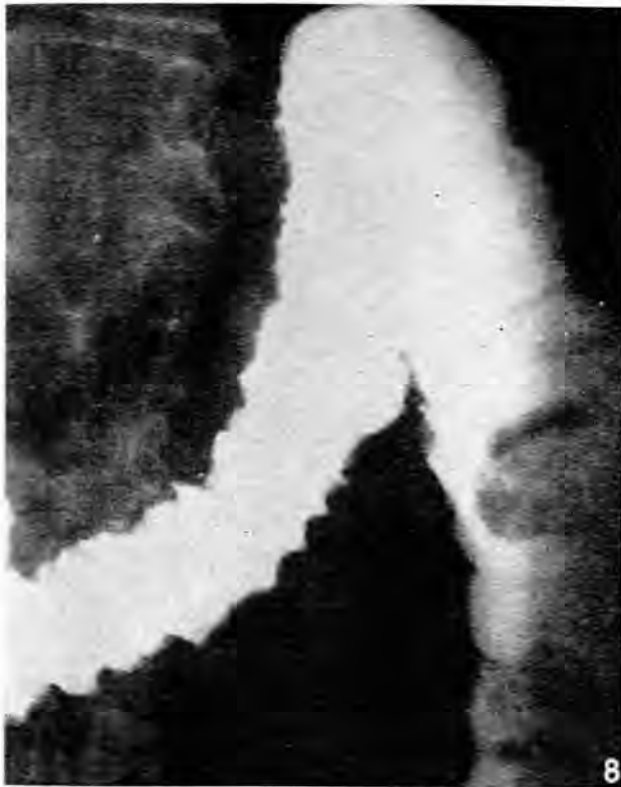

Fig. 8. Rippling of the transverse colon. Prediverticulosis?

reveal the development of true diverticula at these sites. This concept has been supported by Lockhart-Mummery and Hodgson,<sup>43</sup> and more recently Henderson,<sup>17</sup> writing from St. Mark's Hospital, has also accepted and even elaborated it.

It is significant that Spriggs and Marxer, and also Henderson, considered the aetiology of diverticulosis to be inflammation, in that antecedent inflammatory episodes cause the weak areas in the bowel wall. This view commands little if any support today. Todd,<sup>3</sup> also writing from St. Mark's, in 1955, ascribed the rippling to spasm of the muscularis mucosae from the irritation of inflammation complicating established diverticulosis. He also described a smooth waviness of the mucosa from mucosal oedema. Evidence that Todd's view may be nearer the truth is found in the observation that this appearance is most common in the

sigmoid area and that it is frequently found in association with established diverticula situated more proximally.

It is well known that diverticulosis almost invariably starts in the sigmoid area. It is in fact the sole area affected in 47% of cases.<sup>19</sup> To call this appearance in the sigmoid area 'prediverticulosis', while the proximal colon, which is almost invariably involved at a later stage chronologically, is the seat of established diverticulosis, does not fit in with the facts observed. The sigmoid is also almost invariably the site of complicating diverticulitis, so that it may be reasonable to ascribe these radiological appearances to inflammation. It will be shown later that the acceptance of this explanation may be too facile, since these features may also merely be the manifestation of the normal irritability of the colon during barium-enema examination. The concept of Spriggs and Marxer of a radiological prediverticular stage does therefore not appear to be a correct one.

With regard to *diverticulitis*, the 'saw-tooth' deformity, as depicted diagrammatically in Fig. 9, is widely held to be the

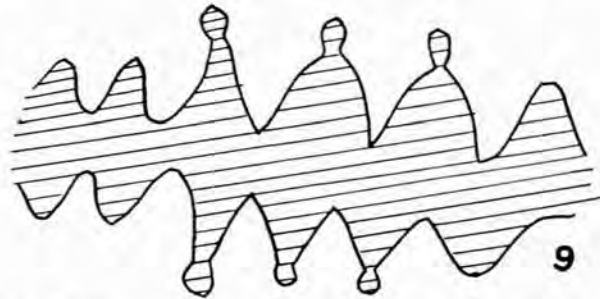


Fig. 9. Diagrammatic representation of 'saw-toothing'.

most important radiological feature. Fig. 10 is a good example and occurred in a woman with unequivocal diverticulitis. There is a difference of opinion concerning the cause of this appearance. The usual view<sup>3</sup> is that it is caused by spasm of the circular muscle of the bowel associated with oedema of the haustral folds. Goulard and Hampton,<sup>44</sup> however, felt that it is caused by a fibrotic shortening of the bowel and thickening of the folds. The deformity, they say, is permanent and indicative of previous inflammation. As evidence of this statement they found that 10 of their patients had no change in the deformity when observed at intervals of 3 months - 3 years. Furthermore, of 45 patients with a demonstrable saw-tooth deformity, only 20 had clinical acute diverticulitis, and conversely, 15 patients (43%) with clinical acute diverticulitis had no saw-tooth deformity. In the present series there is evidence that both views may be correct.

Fig. 11 is another film of the patient depicted in Fig. 10, and was taken at the same examination. The saw-tooth appearance has clearly been transient and cannot result from fibrotic deformity. Figs. 12, 13, and 14 are films of another patient taken at monthly intervals after the establishment of a transverse colostomy for a perforated diverticulum. At the time the X-rays were taken there was no residual evidence, locally or generally, of acute inflammation, so that it appears to be more reasonable to ascribe the radiological features in this case to a fixed deformity than to spasm.

With regard to spasm, a major difficulty is the differentiation between pathological spasm from inflammatory irritability, and the transitory irregular contractions

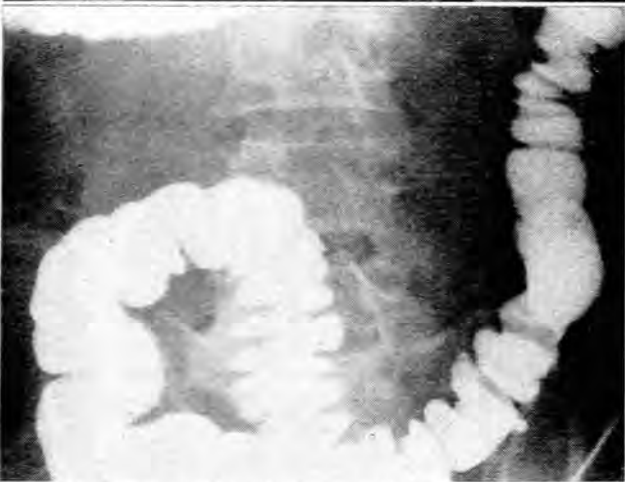
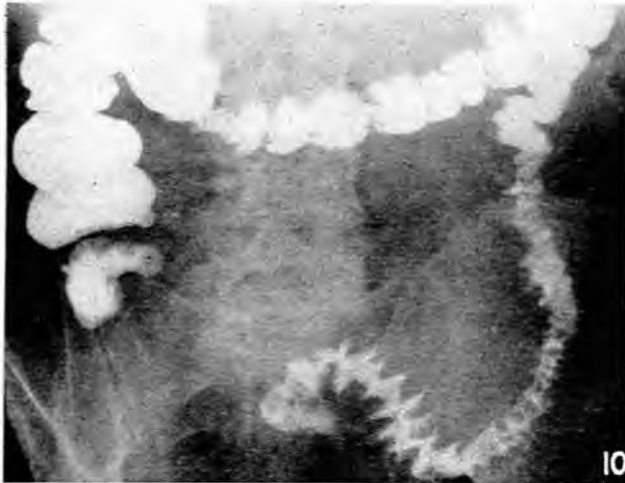


Fig. 10. 'Saw-toothed' of the sigmoid colon. This patient had unequivocal clinical diverticulitis.

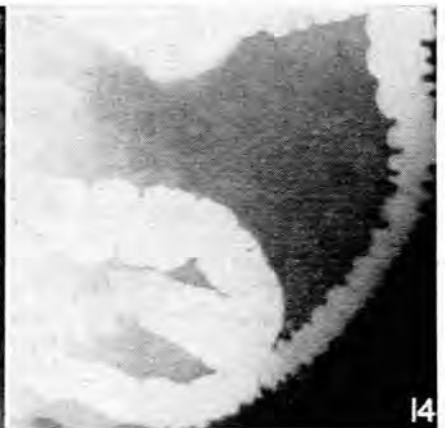
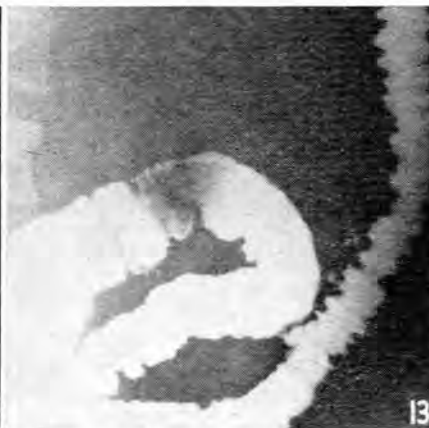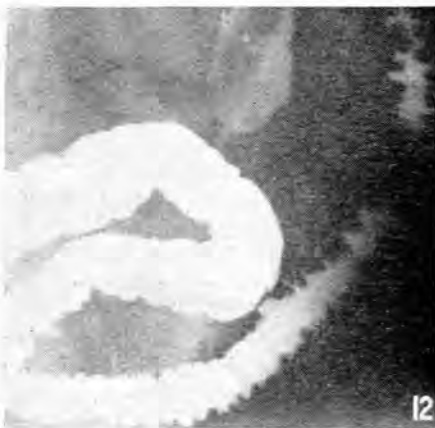Fig. 11. Barium enema of the same patient as in Fig. 10 taken at same examination. The saw-toothed has disappeared.

of the colon so frequently seen during filling. Goulard and Hampton<sup>44</sup> have defined spasm, as opposed to this normal irritability, as a state of contraction persisting throughout any one examination, and that it is best assessed with the

remainder of the colon filled and the patient lying prone. It is significant, however, that of 45 of their patients with demonstrable 'pathological' spasm, only 20 had clinical acute diverticulitis, and conversely, 15 patients with clinical acute diverticulitis, often with demonstrable abscesses, did not manifest any spasm at all. The experience of this series provides many examples to support them. For instance, Figs. 10 and 11 demonstrate spasm ('saw-toothed') which was not persistent during the examination, and yet the patient had undoubted diverticulitis (it must be pointed out, however, that the barium-enema examination was not performed during the course of the acute illness). Conversely, Fig. 15 shows the filling of a pericolic abscess and yet there is no spasm at all in the adjacent colon, and were it not for the filling of the cavity, the radiological diagnosis would certainly have been diverticulosis only. Figs. 16 and 17 were obtained during a single examination of a patient in whom there was no clinical suspicion of past or present diverticulitis. (It was a routine barium enema in a case of haemorrhoids.) Fig. 16 may be held to show the features of prediverticulosis, diverticulosis and diverticulitis, but Fig. 17, which is another film during the same examination, and the clinical picture, are evidence that the appearances are merely caused by 'normal irritability'. The correlation between spasm and the clinical picture is thus very poor.

It is possible that this irritability, while not necessarily present in or caused by inflammation, and which is more commonly seen in the sigmoid area than elsewhere in the large bowel, may be a manifestation of some disorder of the motor activity of the colon, and that it may be important in the pathogenesis of diverticulum formation. Further research is being done on this aspect. Superficially this view seems to be a return to the prediverticulosis concept of Spriggs and Marxer, but the fundamental difference should be quite apparent.

Attention should also be paid to the observation of Wolf, Khilnani and Marshak<sup>45</sup> that an appearance similar to 'saw-toothed', namely, marked haustral asymmetry, is in fact an established part of established *diverticulosis* (Fig. 18). As a diverticulum extends laterally, there is frequently saccululation of an involved haustrum. The damaged muscular fibres bunch, 'as when an elastic band is cut or weakened in one place' producing thick interhaustral plicae. The important feature is the unusual distensibility of the bowel.



Figs. 12, 13 and 14. Barium enemata of the same patient taken at monthly intervals.

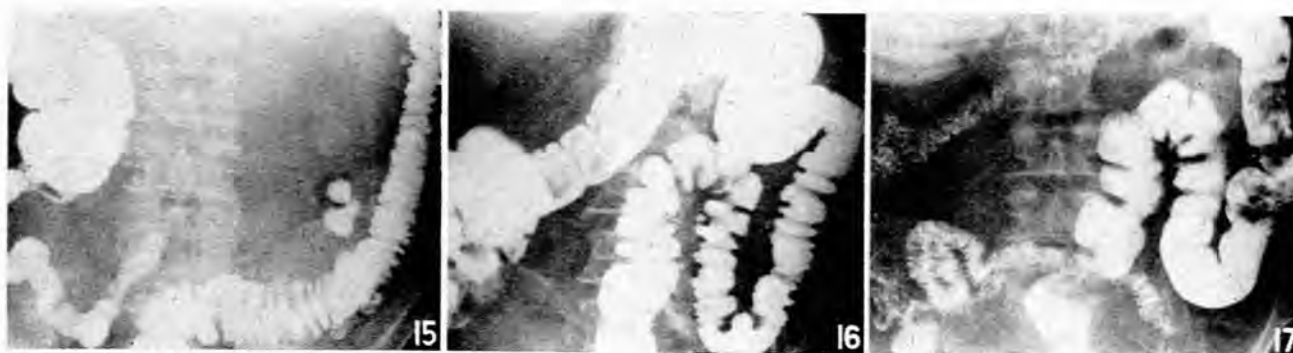

Fig. 15. Peri-colic abscess filled. No spasm in adjacent colon.

Fig. 16. Rippling of 'prediverticulosis'? Saw-toothing of diverticulitis?

Fig. 17. Same patient and same examination as depicted in Fig. 16. The spasm producing the rippling has been transient. Clinically there was no past or present evidence of diverticulitis.

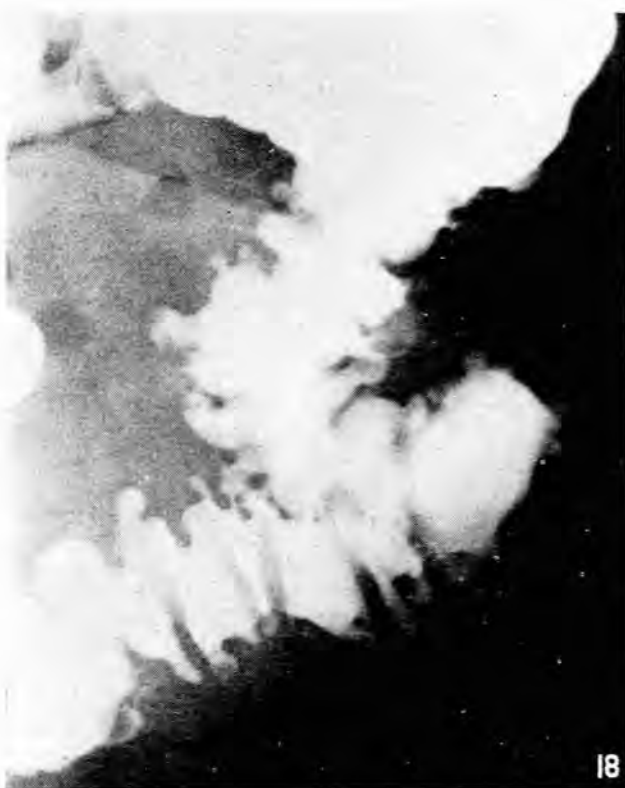

Fig. 18. Marked asymmetry and sacculation of haustra. Established diverticulosis.

A fact not widely appreciated is that the barium-enema examination may be quite normal in acute diverticulitis, since the diverticulum may fail to fill owing to obstruction of its neck. Six of Goulard and Hampton's<sup>44</sup> cases showed no demonstrable diverticula at all. Four of these had demonstrable abscesses, and in one case a barium enema immediately before operation was perfectly normal.

The presence of fixed anatomical changes, owing to the presence of the intramural but extramucosal inflammatory mass, provides reliable radiological confirmation of the diagnosis of diverticulitis. There may be a well-defined filling defect (Fig. 5 and 6), a poorly demarcated area of induration

(Fig. 19), or an abscess cavity (Figs. 15 and 20), but, clearly, the absence of these features by no means excludes the diagnosis.

We may then conclude that:

1. The barium enema may be quite normal in diverticulitis.
2. The barium enema may show only the classical features of diverticulosis in a proved case of diverticulitis.
3. The interpretation of spasm is difficult and requires further research. Diverticulitis may occur in the absence of any radiological evidence of spasm, and *vice versa*.
4. Fixed anatomical defects provide reliable radiological confirmation of the diagnosis of diverticulitis, but their absence does not exclude the diagnosis.
5. The clinical aspect of the diagnosis is the most reliable in the present state of our knowledge.

There is a paucity of radiological observations made during the acute phase of the disease. The hazards of this procedure have probably been overstated,<sup>44</sup> and pursuance of this line of investigation may fill a gap in our knowledge.

#### MANAGEMENT

The immediate management of the complications of diverticulitis has been discussed under the relevant sections. It remains only to discuss the rôle of elective surgery in this condition.

The orthodox view<sup>6</sup> has been that the only surgery of diverticulitis is the surgery of its complications, and such surgery as was necessary was usually staged. In recent years 2 trends are discernible. Firstly, there has been an increasing tendency to employ single-stage procedures,<sup>13,24,25,29</sup> even in the presence of severe complications. Secondly, many authorities have recommended earlier surgery in an attempt to forestall complications.<sup>24,29</sup>

A word of warning should be sounded with regard to this more aggressive attitude, and a plea is made for judgement on the merits of each case individually. This view obtains support from Friesen and Schmidt<sup>35</sup> who state that no condition in general surgery requires more seasoned judgement if prolonged morbidity and even mortality are to be kept at a minimum.

It is apparent from our series that 2 very serious complications, namely, massive haemorrhage and rupture of a diverticulum, tend to occur quite unheralded. In fact, they are



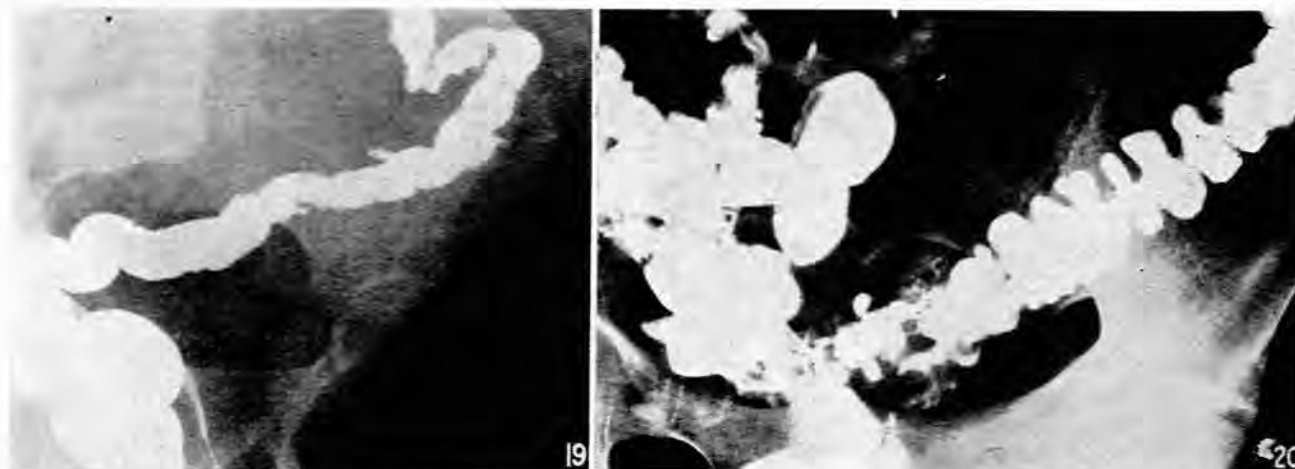


Fig. 19. Poorly demarcated area of induration and rigidity caused by diverticulitis. Confirmed by histological examination after resection.

Fig. 20. Barium filling a pericolic abscess cavity.

essentially complications of diverticulosis, and a past history to suggest episodes of diverticulitis is usually not forthcoming. A programme of prophylactic surgery to forestall such complications is patently ludicrous, in view of the great incidence of diverticula, especially in the older age groups. As we have stated earlier, a very reasonable case can even be made out for not subjecting patients who have merely ruptured a diverticulum to any excisional surgery at all, and in the case of massive haemorrhage the good results from a conservative approach, combined with the difficulty of localizing the bleeding point at operation, make this conservative approach a reasonable one.

With regard to the place of surgery in patients with recurrent episodes of acute diverticulitis, a reasonable attitude is to consider resection after the second attack has settled, but a plea is likewise made to suit therapy to the needs of the individual patients. Excisional surgery for diverticulitis coli is difficult at the best of times, and obesity, to which a fair proportion of these people are prone, adds considerably to the hazards of colonic surgery. We would agree with Welch and Rodkey,<sup>46</sup> from the Massachusetts General Hospital, who, while acknowledging the place of 1-stage resections in this condition, emphasize the necessity for judgement and conservatism in selecting the type of surgery. They point out that the surgeon is not operating for carcinoma, that most complications after surgery are referable to the anastomotic line, and that a temporary colostomy is a small price to pay for the added safety. 'Rigid standardization should be avoided, and cognizance should be taken of a multiplicity of local and general factors'.

Lloyd-Davies<sup>1</sup> has also stated as recently as 1955 that there will always be a group of irresectable cases, either because of age or poor risk, or because colostomy has failed to control the local infection. He cites a case where a vesico-colic fistula appeared 7 months after the performance of a colostomy. One patient in this series had a transverse colostomy only because of cardiac contraindications to a major resection, and in a further patient who also has a colostomy, resection has been repeatedly put off for several years because

she was unwilling to reduce her enormous obesity. Difficulty in excluding carcinoma (there were 4 such cases in this series), certainly warrants the more aggressive attitude.

#### SUMMARY

1. Ninety patients with symptomatic diverticular disease of the colon from the Johannesburg General Hospital are reviewed.

2. The anatomy and pathogenesis of diverticula are discussed. The rôle of the anatomical relations of the blood vessels to the bowel in causing potential weaknesses in the wall at the sites of their penetration is well established, but the precipitating factors determining the appearance of diverticula in the individual person are still obscure.

3. Massive haemorrhage is almost invariably a complication of diverticulosis and not diverticulitis. A conservative attitude to this complication is justified by the results obtained with it, and by the considerable difficulties facing the surgeon if he has to operate. Diverticulitis seldom bleeds massively, and the definitive treatment in these cases is determined by other considerations.

4. A spreading or generalized peritonitis may result from the rupture of a diverticulum with little or no evidence of diverticulitis, rupture of a pericolic abscess, or extension of the acute inflammatory process without evidence of free perforation or rupture of an abscess. The mortality is very high. Consideration of the fatal cases produces evidence that vigorous and adequate restoration of blood volume in these patients is the most important single factor to be considered if the mortality rate is to be decreased. Prevention of continued re-infection of the peritoneal cavity must also be achieved. There is much difference of opinion regarding the surgical measures which may best accomplish this.

5. In cases presenting an abdominal or pelvic mass, the differentiation from carcinoma is important and may be difficult. The criteria available for differential diagnosis are evaluated.

6. Fistula formation has become a rare complication of diverticulitis. The more efficient management of the acute

attack made possible by the advent of antibiotics is probably the most important reason for this.

7. It is important to appreciate that there are at least 3 possible mechanisms whereby intestinal obstruction can complicate diverticulitis. A case illustrating each is presented.

8. The radiological criteria for the differential diagnosis between diverticulosis and diverticulitis are discussed. Attention is drawn to several widespread misconceptions, and the importance of considering the clinical manifestations in conjunction with the radiological features is emphasized. The effect of an accurate differentiation on the assessment of the natural history of the condition, and therefore on a reasonable therapeutic attitude to the condition, is discussed.

9. While cognizance is taken of the possible advantages of a more aggressive attitude to this condition, a plea is made for avoiding a rigidly standardized therapeutic approach to the indications for surgery and the type of surgery employed.

I am indebted to Prof. D. J. du Plessis for invaluable help and criticism; to Dr. J. S. Enslin, Deputy Superintendent of the Johannesburg General Hospital, for permission to publish these cases; to surgeons on the staff of the Johannesburg General Hospital for access to their case records; to Dr. M. Berk of the Department of Radiology for helpful advice; and to Mr. D. Smith of the Department of Surgery for preparation of the photographs.

#### REFERENCES

- Lloyd-Davies, O. V. (1953): *Proc. Roy. Soc. Med.*, **46**, 407.
- Welch, C. F., Allen, A. W. and Donaldson, G. A. (1953): *Ann. Surg.*, **138**, 332.
- Todd, I. P. (1955): *Ann. Roy. Coll. Surg. Engl.*, **16**, 118.
- Morton, J. J. (1946): *Ann. Surg.*, **124**, 725.
- Ochsner, H. C. and Bergen, J. A. (1935): *Ann. Intern. Med.*, **9**, 282.
- Pemberton, J. de J., Black, B. M. and Maino, C. R. (1947): *Surg. Gynec. Obstet.*, **85**, 523.
- Grout, J. L. A. (1949): *Brit. J. Radiol.*, **22**, 442.
- Smithwick, R. H. (1942): *Ann. Surg.*, **115**, 669.
- Bacon, H. E. and Sherman, L. F. (1950): *Amer. J. Surg.*, **80**, 3.
- Edwards, H. C. (1954): *Ann. Roy. Coll. Surg. Engl.*, **14**, 371.
- Lockhart-Mummery, J. P. (1938): *Lancet*, **2**, 1401.
- Ford, H. S. (1953): *Canad. Med. Assoc. J.*, **69**, 506.
- Boydell, A. M. (1950): *Ann. Surg.*, **122**, 94.
- McGowan, F. J. and Wolf, W. I. (1952): *Gastroenterology*, **21**, 119.
- Drummond, H. (1916-17): *Brit. J. Surg.*, **4**, 407.
- Fausler, W. A. (1940): *Trans. Amer. Proctol. Soc.*, **41**, 231.
- Henderson, H. P. (1944): *Brit. J. Radiol.*, **17**, 197.
- Rankin, F. W. and Graham, A. S. (1939): *Carcinoma of the Colon and Rectum*, p. 117. London: Baillière, Tindall and Cox.
- Horner, J. L. (1958): *Amer. J. Dig. Dis.*, **3**, 343.
- Fraenkel, G. J. (1954): *Brit. J. Surg.*, **41**, 643.
- Hoar, C. S. and Bernhard, W. F. (1954): *Surg. Gynec. Obstet.*, **99**, 101.
- MacLaren, I. F. (1957): *J. Roy. Coll. Surg. Edin.*, **3**, 129.
- Maingot, R. (1955): *Abdominal Operations*, 3rd ed. London: Lewis.
- Bacon, H. E. and Valiente, M. A. (1956): *Amer. J. Surg.*, **91**, 178.
- Ryan, P. (1958): *Brit. J. Surg.*, **45**, 611.
- Guy, C. C. and Werelius, C. Y. (1952): *Surg. Clin. N. Amer.*, **32**, 91.
- Rankin, F. W. and Brown, P. W. (1930): *Surg. Gynec. Obstet.*, **50**, 836.
- Colcock, B. P. and Sass, R. E. (1954): *Ibid.*, **99**, 627.
- Waugh, L. J. M. and Walt, A. J. (1957): *Ibid.*, **104**, 690.
- Laufman, H. (1941): *Int. Abstr. Surg.*, **73**, 222.
- Arnheim, E. E. (1940): *Ann. Surg.*, **112**, 352.
- Baile, L. A. and Jackman, R. J. (1943): *J. Amer. Med. Assoc.*, **121**, 1144.
- Smith, N. D. (1951): *Amer. J. Surg.*, **82**, 583.
- Schatzki, R. (1940): *Radiology*, **34**, 651.
- Friesen, L. and Schmidt, E. R. (1955): *Surg. Clin. N. Amer.*, **35**, 1385.
- Telling, W. H. M. and Gruner, O. C. (1917): *Brit. J. Surg.*, **4**, 468.
- Mayo, C. W. and Blunt, C. B. (1950): *Surg. Gynec. Obstet.*, **91**, 612.
- Reid, S. E. and Workman, C. M. (1955): *Quart. Bull. Northw. Univ. Med. Sch.*, **29**, 190.
- Ormond, J. K. (1949): *J. Urol. (Baltimore)*, **61**, 554.
- Spriggs, E. L. and Marver, O. A. (1927): *Lancet*, **1**, 1067.
- Idem* (1925): *Quart. J. Med.*, **19**, 1.
- Spriggs, E. L. (1929): *Brit. Med. J.*, **2**, 566.
- Lockhart-Mummery, J. P. and Hodgson, H. G. (1931): *Ibid.*, **1**, 525.
- Goulard, A. and Hampton, A. O. (1954): *Amer. J. Roentgenol.*, **72**, 213.
- Wolf, B. S., Khilnani, M. and Marshak, R. H. (1958): *Ibid.*, **77**, 726.
- Welch, C. F. and Rodkey, G. V. (1956): *Surgery*, **39**, 712.
- Stone, H. B. (1946): *Ann. Surg.*, **124**, 743.
- Idem* (1944): *Ibid.*, **120**, 582.
- Jensen, G. L. (1958): *Amer. J. Surg.*, **95**, 813.
- Foster, R. L. and Fisher, R. F. (1954): *Amer. Surg.*, **20**, 734.
- Kunath, G. A. (1956): *Amer. J. Surg.*, **91**, 911.
- du Plessis, D. J. (1960): Personal communication.
- Gouverneur, R., Soupault, R. and Latif, M. (1938): *J. Chir. (Paris)*, **51**, 215.
- Lynn, T. E., Farrell, J. I. and Grier, J. P. (1958): *Surgery*, **76**, 956.
- Ewell, G. H. (1951): *Amer. J. Surg.*, **82**, 597.
- Edwards, H. C. (1954): *Recent Advances in Surgery*, 4th ed., p. 213. London: J. and A. Churchill.