

SARCOMA BOTRYOIDES OF THE VAGINA

A REPORT OF TWO CASES

S. CYWES, M.B., CH.B., M.MED. (SURG.) (CAPE TOWN), and J. H. LOUW, CH.M. (CAPE TOWN), F.R.C.S. (ENG.)

Department of Surgery, University of Cape Town and Red Cross War Memorial Childrens' Hospital, Cape Town

Sarcoma botryoides is a rare tumour, but nevertheless the most frequently seen malignant tumour of the uterus or vagina in children. The name 'botryoid', derived from Greek and meaning 'a bunch of grapes', vividly describes the characteristic polypoid oedematous masses which distend the vagina and project externally like a cluster of white grapes. Ober and Edgcomb²³ have provided the following comprehensive description of the condition: 'A tumour that occurs predominantly in infants and children in almost any part of the urogenital apparatus, that grows in the form of a single complex polypoid mass, that is derived from mesenchymal cells, that may exhibit any or all of the transformations displayed by multipotent mesenchymal cells, and that is characterized by a tendency to recur locally following attempts at extirpation, to extend to adjacent pelvic viscera and somewhat less frequently to metastasize to distant organs'.

Sarcoma botryoides was first described by Guersant²¹ in 1854. Pfannenstiel,¹⁹ in 1892, commented on the 'grape-like' appearance (*traubige sarcom*) and since then the term sarcoma botryoides has persisted. However, through the years the tumour has been given no less than 119 different names.²² Descriptive terms such as 'rhabdomyosarcoma', 'carcinosarcoma', 'myxoma enchondromatodes arborescens colli uteri' and 'mixed mesodermal tumour' have been used, depending upon the predominant histological pattern. Many workers regard the tumour as an embryonal rhabdomyosarcoma, but McFarland¹² made a plea for the name 'dysontogenetic mixed tumour'.

Although sarcoma botryoides is rare, the literature on the subject is large and includes excellent reviews of the histological and developmental features of the tumour,^{12,19} as well as detailed historical accounts of its behaviour and treatment.^{2,3} In little girls the tumour occurs chiefly in the vagina, and despite its rarity must always be borne in mind in the differential diagnosis of any protuberant mass occurring in this region (benign lesions with tumefaction are even rarer). In small boys a similar type of tumour occurs in the bladder neck and prostatic urethra ('sarcoma of the prostate'). With rare exceptions these tumours occur before the age of 5 years and about half the reported cases have been in children under the age of 2 years. Sarcoma botryoides has been reported in newborn infants,^{9,14} and also in adolescents⁵ and adult women.³ It is of interest that the older the patient the higher in the genital tract is the site of origin of the tumour.

VAGINAL SARCOMA BOTRYOIDES

Clinical Features

The condition commonly presents as a polypoid or fleshy mass in the vagina, or more classically projecting from the introitus. Recurrent episodes of vaginal bleeding usually occur, either spontaneously or from irritation by

clothing. Urinary symptoms may be present, especially if the tumour is anteriorly situated. Dysuria and frequency are common complaints with or without intermittent haematuria. Tenesmus may be present where posterior extension occurs. A purulent vaginal discharge, as a result of tumour necrosis and infection, may be a presenting symptom.

On examination, the typical grape-like polypoid tumour projecting from the vagina is usually easily recognized. However, some cases present with a more compact, fleshy mass, as was seen in our case 1. Except for enlargement of the vagina and uterus, detectable on rectal examination, the rest of the physical examination is usually negative. Cystoscopy and intravenous pyelography may be of value in determining whether the bladder is involved.

The tumour is highly malignant, with a marked tendency to recur locally after excision and to invade adjacent organs. Involvement of the bladder or rectum may result in fistula formation. Ureteral obstruction will lead to hydronephrosis, uraemia and death. Distant blood-borne metastases are uncommon, but have been reported.^{7,8,21} Lymphatic spread to the inguinal glands has also been reported.³ In children and infants the tumours very rarely metastasize, but in adults this is not so unusual.

The diagnosis must be confirmed by biopsy of the tumour. Duncan and Fahmy⁶ stressed the extreme rarity of benign cervico-vaginal polypi in childhood, and suggested that any polypoid mass must be regarded as sarcoma botryoides until disproved. However, initial biopsy may be misleading. This was so in our case 1, and similar cases have been recorded in the literature.³

Pathology

Characteristically there is great variation in the histological pattern. Almost any variant in cell size and shape may be found — round cells, stellate cells and spindle cells. There is also considerable variation in the density of the stroma, which may be loose and myxomatous or fairly dense and fibrous. Striated muscle cells are usually present, but may be few and unobtrusive. Other heterologous components, such as bone, cartilage or epithelial glands may be present. The basic constituent of the tumour is the neoplastic mesenchymal cell which has the ability to differentiate into any of these components.

Histogenesis

Most authorities have accepted McFarland's¹² suggestion that lesions classified as sarcoma botryoides, as well as the mixed tumours of the urogenital ridge, should be called 'dysontogenetic' tumours. (The term 'dysontogenesis' was suggested by Schwalbe to describe malformations and tumours arising from errors of development.) Characteristically the tumour starts in the subepithelial tissue of the vagina, lifting and heaping up the squamous epithelium

into oedematous fronds. This produces the typical grape-like appearance.

Prognosis

The prognosis is extremely grave. The literature contains reports of only a few patients who have survived without recurrence for 5 or more years. This poor prognosis may be ascribed to delay in diagnosis coupled with inadequate resection of the primary growth and over-reliance on radiation therapy.

In all the cases that have terminated fatally the disease recurred within less than a year. It would appear, therefore, that survival for 1 year without evidence of recurrence after treatment may indicate a favourable outcome.

Treatment

The literature on the treatment of sarcoma botryoides has been reviewed in detail by Daniel, Koss and Brunschwig.³

Between 1885 and 1909 several patients were treated by local excision, partial or total vaginectomy or total hysterectomy. Of these, only 1 patient survived 10 years, viz. a patient treated by Volkmann²⁵ in 1885 by local excision, and further excision of a recurrence 6 months later.

Between 1909 and 1947 it was fashionable to treat the condition by local excision, with or without cauterization, and some form of radiotherapy. During this period only 2 cures were reported. Reisach,²⁶ in 1927, treated a tumour in a 2-year-old infant by local excision followed by 2 applications of radium. This patient was alive 13 years later. Döderlein,⁴ in 1930, treated a similar growth in an infant by local excision and 2 applications of radium, with long-term survival.

No cure has been reported after treatment with radiotherapy alone, and it is now generally agreed that these tumours are not radiosensitive.

Since 1947 the treatment of choice has again become surgical with the emphasis on radical extirpation.

In 1947 Ulfelder and Quan²⁴ reported a case of sarcoma botryoides in an infant, treated by Wertheim hysterectomy with total vaginectomy. The child was alive and well after 14 years. In the same year Shackman²⁰ treated a child of 4 years by preliminary bilateral uretero-sigmoidostomy, followed at a second stage by wide resection of the vulva, vagina, uterus, bladder and a portion of the pubic ramus. This patient was alive and well 11 years after operation. Other long-term survivals following radical surgery have been reported by various authors, e.g. Richmond¹⁹ (by total hysterectomy and partial vaginectomy); Gross²⁰ (2 cases, one by total hysterectomy and vaginectomy, and the other by simultaneous ureterosigmoidostomy); Ober, Smith and Rouillard¹⁴ (2 patients treated by total hysterectomy and vaginectomy, at the ages of 7 days and 8 days respectively); and Daniel, Koss and Brunschwig³ (2 patients, one aged 21 years treated by total pelvic exenteration and a wet colostomy, and the other, an infant of 6 months, treated by an anterior exenteration and ureterosigmoidostomy).

These few successes represent only a very small fraction of all the hundreds of cases reported, and this dismal picture accounts for the attitude of hopelessness adopted by so many authors, e.g. Okmian and Livaditis,¹⁶ who

wrote in 1959: 'Regardless of the treatment employed, this tumour almost uniformly progresses to a fatal termination'.

Practically all authorities now urge more and more radical surgery on the grounds that extensive surgery holds the only hope of cure. Okmian and Livaditis¹⁶ recommended that 'radical resection of all pelvic organs, with diversion of the urinary and intestinal tracts, should be considered'. Ulfelder and Hendren²³ wrote: 'We believe that an aggressive surgical attack on this tumour is the treatment of choice, and do not hesitate to remove the entire vagina, uterus and bladder if the primary lesion is of sufficient size or extent to justify such a radical approach. A child in whom insufficient radical surgery is performed with the hope of sparing these structures, will usually be dead within two years if tumour be left behind'. Swenson²² recommended total pelvic exenteration, because in his hands preservation of the anal canal has been unsuccessful.

In spite of these opinions and recommendations, there are only 2 cases reported in the literature where total pelvic exenteration has been performed. Sternberg, Clark and Smith²¹ reported a case of an advanced sarcoma botryoides with involvement of the pelvic nodes, bladder and rectum, treated by total pelvic exenteration. This patient died of recurrence 7 months after operation. In 1959, Daniel, Koss and Brunschwig³ reported a case of a woman of 21 years, alive and well 5 years after total pelvic exenteration with a wet colostomy.

In this paper we report 2 cases of sarcoma botryoides treated by radical surgery, one by total pelvic exenteration with urinary diversion, using a segment of sigmoid colon as a conduit, and the second by anterior pelvic exenteration, sigmoid colostomy and implantation of the ureters into the rectal stump.

CASE 1

A White girl, R.D., aged 2 years 7 months, was admitted to the Red Cross War Memorial Children's Hospital on 2 February 1961.

Three months before admission, the mother had noticed a small pinkish 'growth' around the urethral orifice, which protruded from the vagina. During this time the child had repeated episodes of dysuria, frequency, and intermittent, yellow vaginal discharge which stained her underclothes. No vaginal or urethral bleeding was noted.

The child was referred to a gynaecologist because of a suspected urethral caruncle. Cystoscopy proved negative. A biopsy of the tumour showed no obvious malignancy, but a second biopsy contained tissue indistinguishable from sarcoma botryoides. The patient was then referred to us.

Clinical examination on admission revealed a child in good general condition. Examination of the cardiovascular, respiratory and central nervous systems proved negative, and there was no significant lymphadenopathy. A mass could be felt in the hypogastrium extending into the pelvis. A small, lobulated, pink, fleshy tumour protruded from the vagina when the labia were separated. On rectal examination, a large mass could be felt extending towards the left and adherent to the anterior rectal wall.

Laboratory Investigations

Haemoglobin 12 G. per 100 ml.; WBCs 6,000 per c.mm.; urinalysis—no protein, pus cells 10-12 per high-power field, RBCs 3-4 per high-power field; blood urea 28 mg. per 100 ml.; serum electrolytes within normal limits.

Radiological Investigation

The chest was normal. An intravenous pyelogram showed

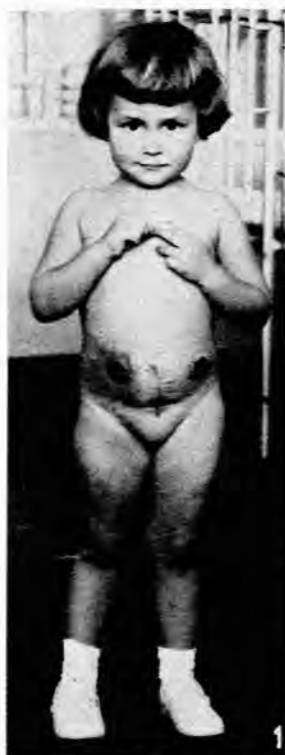

Fig. 1. Note the colostomy and the urinary conduit — case 1.



Fig. 2. The belt and disposable plastic bags in position — case 1.

piece. The vaginal wall is thickened and glistening, with grape-like clusters projecting into the vaginal cavity. The uterine wall is also thickened and glistening, but there are no projections into the lumen. Projecting from the posterior wall of the vagina, in the region of the fornix, there is a mass of glistening tissue 4.5 cm. \times 2.5 cm. \times 3 cm., which is filling the recto-vaginal fossa.

(2) Lymph node with some fat attached, about 0.5 cm. in diameter. Shows no obvious abnormality on naked-eye examination.' (This was an obturator gland.)

Histology

'Histology shows a rhabdomyosarcoma involving vagina and uterus with a bridge into the recto-vaginal fossa, which does not appear to have penetrated the peritoneum. The bladder

lateral displacement of the lower third of the ureters and indentation of the bladder wall.

Biopsy of the vaginal tumour (27 January) revealed the presence of myxomatous tissue, angiomatous tissue and striped-muscle fibres. The histological pattern was that of a myxorhabdomyosarcoma or sarcoma botryoides.

Treatment

In view of the degree of malignancy of the tumour and the extent of local involvement in this case, a total pelvic exenteration was performed. The urethra and bladder, vulva, vagina and uterus, and anus and rectum were excised *en bloc* by an abdomino-perineal approach. The ovaries were conserved. The ureters were implanted into the terminal segment of sigmoid colon which was isolated on its mesentery and used as a conduit. This was brought out on the right side of the abdominal wall. The end of the proximal sigmoid colon was brought out as a permanent colostomy on the left side of the abdominal wall (Fig. 1).

Nitrogen mustard was given intravenously during the operation and for the following 3 days. Radiotherapy was not given because of the risk of destroying the ovaries.

Seven days after the operation the child developed intestinal obstruction because of a knuckle of small bowel which had become kinked at the colostomy site. Thereafter, the post-operative course was uneventful and a special belt with 2 collecting bags was fitted to the child (Fig. 2) to prevent soiling. In the early postoperative period there was a slight rise of the serum chlorides to 103 m.Eq/l., and she was therefore given sodium bicarbonate by mouth.

Pathological Report

'The specimen (Fig. 3) consists of:

(1) Uterus, vagina, bladder and rectum removed in one

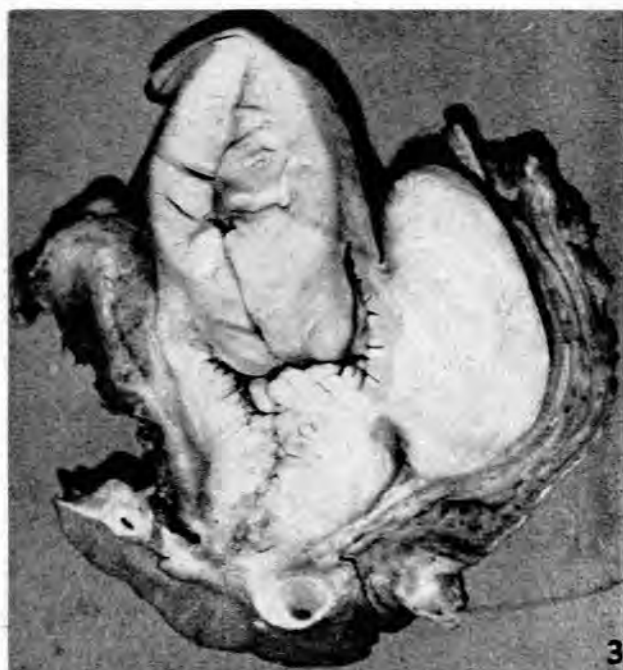


Fig. 3. The anus, rectum, vulva, vagina, uterus, urethra, and bladder in one piece. The tumour projects into the vagina. Infiltration of the uterus and extension of the tumour into the recto-vaginal fossa are clearly shown — case 1.

wall does not appear to be involved, but the tumour extends very close to the urethral mucosa in sections taken. The rectum does not appear to be infiltrated. The lymph node shows no evidence of tumour involvement.'

Progress

She was discharged from hospital 4 weeks after admission (Fig. 4). She returned 6 months later for a follow-up, and was found to be in perfect health with no evidence of recurrence. Electrolyte and urinary investigations were all within normal limits. An X-ray of the chest proved normal. An intravenous pyelogram showed both kidneys to be functioning well, with no significant ureteric dilatation (Fig. 5). The skin around the sigmoid bladder was in perfect condition with no excoriation (Fig. 6). Eight months after the operation she was still in excellent health, well adjusted and happy.

CASE 2

S.-A. V., a Coloured girl aged 2 years 6 months, was admitted to the Red Cross War Memorial Children's Hospital on 12 April 1961.

In June 1960 the patient was admitted to the gynaecological department of another hospital with a diagnosis of sarcoma botryoides of the vagina. An excision biopsy was performed

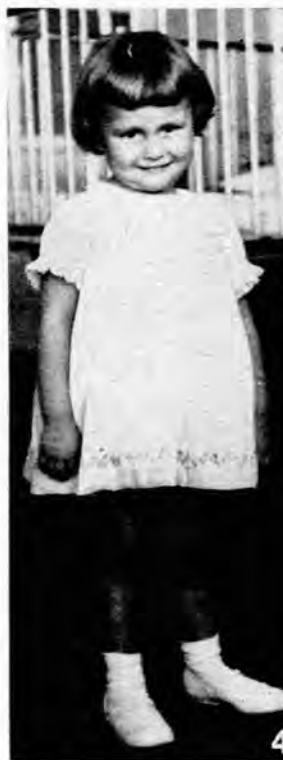

Fig. 4. R.D. on discharge — case 1.

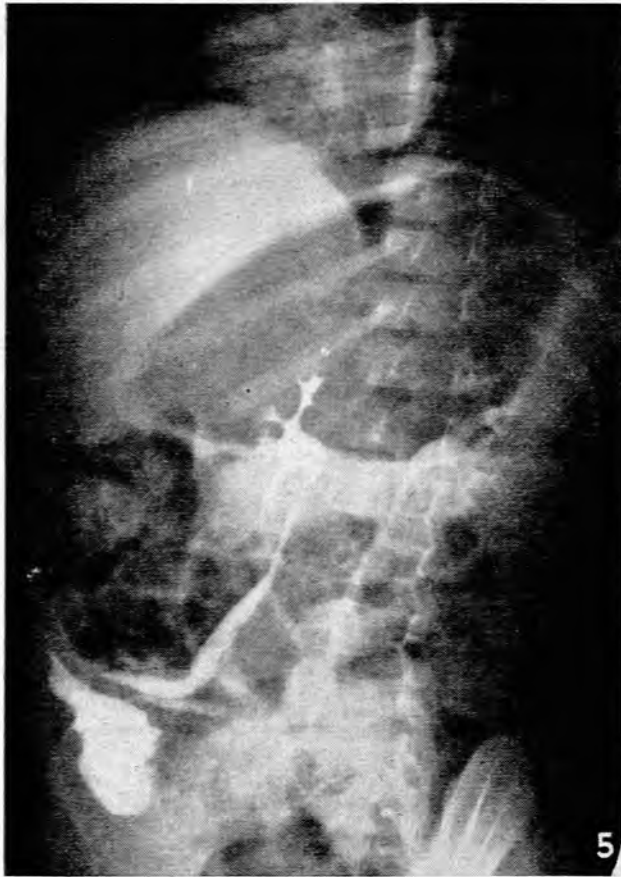

Fig. 5. Intravenous pyelogram in case 1, 6 months after operation, shows good function of both kidneys with no significant ureteric dilatation.

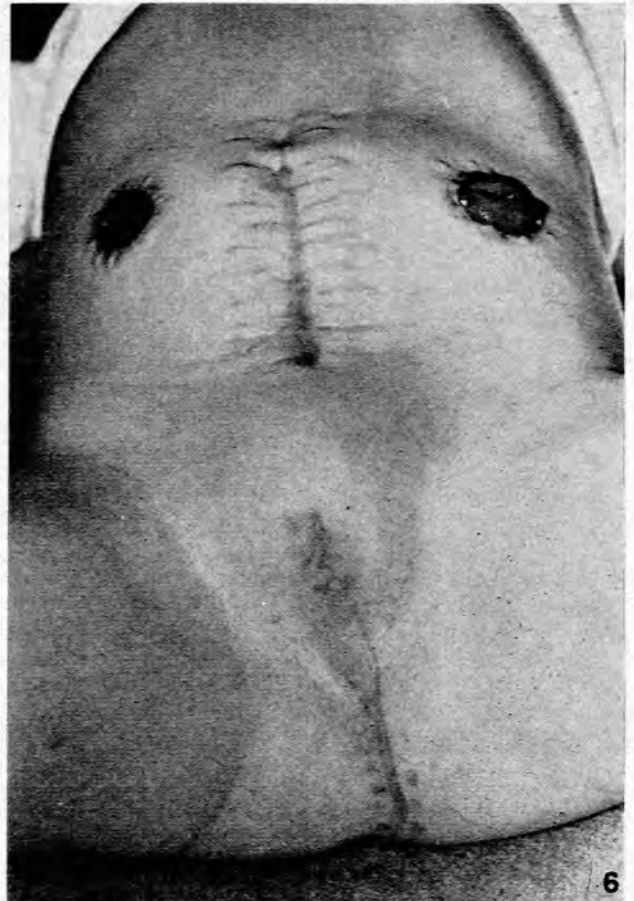


Fig. 6. The perineal and abdominal scars 6 months after operation. Note that the skin around the sigmoid bladder shows no evidence of excoriation — case 1.

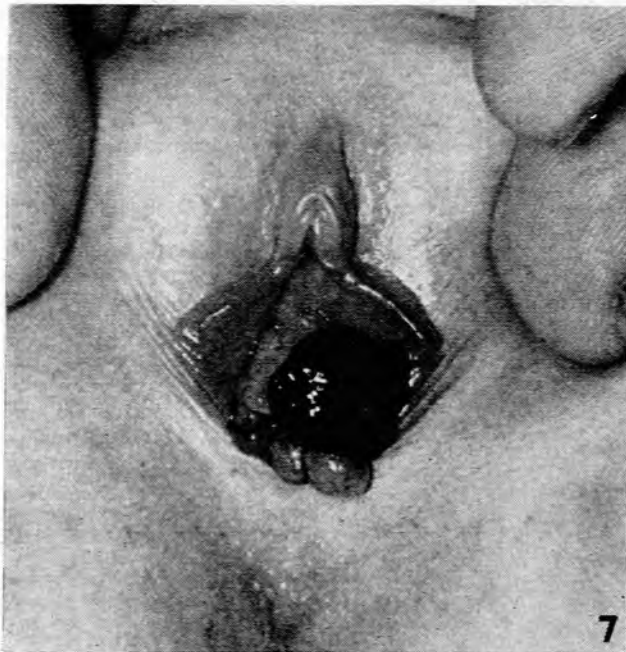


Fig. 7. The typical lobulated grape-like tumour can be seen projecting from the vagina — case 2.

and the diagnosis confirmed histologically. The patient was discharged without further therapy.

Two months later the mother noticed a recurrence of the tumour, which now protruded from the vagina, with intermittent vaginal bleeding. The child complained of pain on micturition, and the urine on occasion appeared to be blood-stained.

Clinical examination on admission showed that the child was in good general condition. Examination of the respiratory, cardiovascular and central nervous systems proved negative, and there was no significant lymphadenopathy. No abnormal masses could be felt on abdominal palpation. A typical lobulated grape-like tumour projected from the vagina (Fig. 7). The growth appeared to involve the anterior vaginal wall. On rectal examination no pelvic extension or rectal infiltration could be detected.

Laboratory Investigations

Urinalysis was negative, except for 3-4 pus cells per high-power field; haemoglobin 10.5 G. per 100 ml.; WBCs 11,550 per c.mm.; blood urea 19.3 mg. per 100 ml.; electrolytes normal.

Radiological Investigation

Radiological investigation of the chest was normal.

An intravenous pyelogram (Fig. 8) showed involvement of the left side of the bladder with dilatation of the left ureter, suggesting infiltration or external pressure.

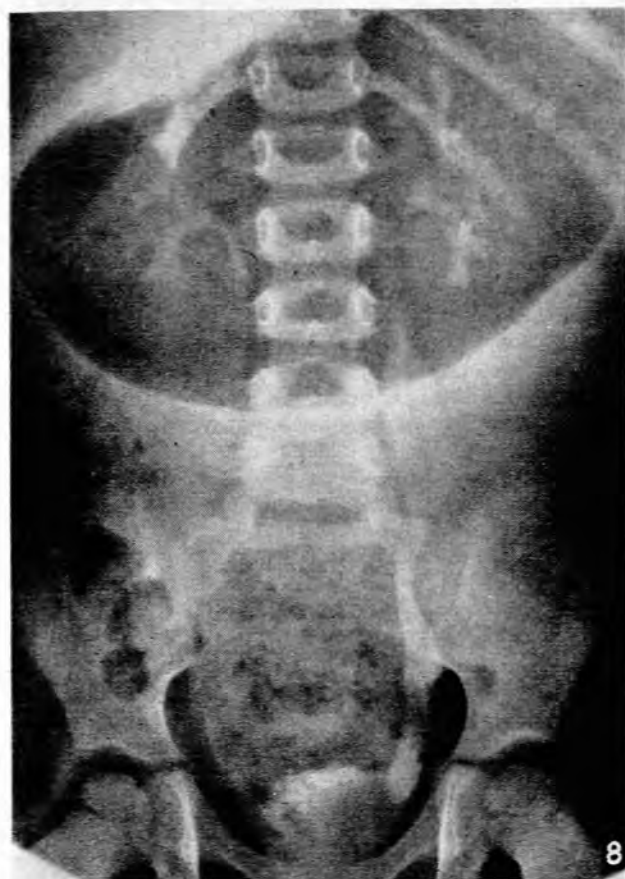

Fig. 8. Intravenous pyelogram shows involvement of the bladder with dilatation of the left ureter — case 2.

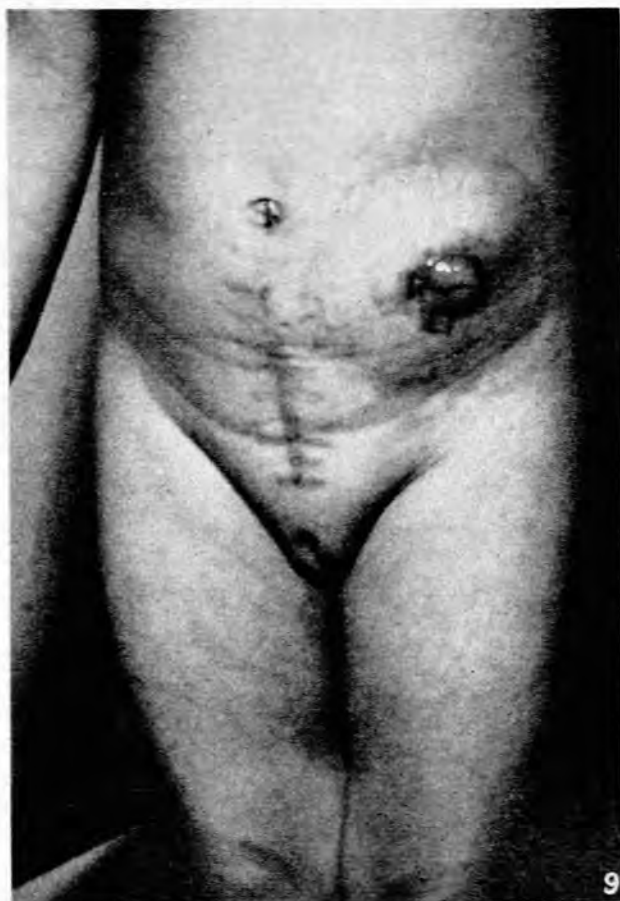

Fig. 9. Terminal left iliac colostomy — case 2.

Treatment

A laparotomy was performed through a lower midline incision. The growth was found to involve the anterior vaginal wall and to infiltrate the posterior bladder wall. No other evidence of extension could be found. An anterior pelvic exenteration was performed, removing *en bloc* the uterus, vagina and vulva, and the bladder and urethra, by an abdomino-perineal approach. Both ovaries were spared. The rectum was divided at the pelvic peritoneal reflection and the distal end closed in 2 layers. Both ureters were then implanted into the rectum, thus producing a rectal bladder. The proximal sigmoid colon was brought out as a permanent terminal colostomy in the left iliac fossa (Fig. 9).

Nitrogen mustard was given intravenously during the operation and for the following 3 days.

The postoperative course was uneventful and the child made an excellent recovery. She was ambulant from the 7th postoperative day and was placed on a chamber every hour to pass urine. Follow-up electrolytes showed only a slight rise in the serum chloride to 104 m.Eq/l.

She was discharged on the 16th postoperative day with the colostomy functioning well into a disposable colostomy bag (Figs. 10* and 11). Although not completely continent of urine, she asked for the chamber to urinate and passed up to 130 ml. of urine at a time.

Pathological Report

*The specimen consists of:

(1) The vulva, vagina, uterus, bladder and urethra in one

*See p. 916.



Fig. 11. Patient on discharge from hospital — case 2.

piece (Fig. 12). The bladder wall is thickened and oedematous; extending into the bladder and involving the urethra is a white polypoid mass. This appears to extend through, and there are polypoid grape-like structures mainly in the anterior wall of the vagina in its lower third. The body of the uterus appears to be free of tumour.

(2) Lymph node measuring about 0.3 cm. in diameter.'

Histology

'Histology shows:

(1) There is a sarcoma botryoides of the vagina in its anterior wall and this is also present in the wall of the bladder. The uterus and posterior portion of vagina appear to be free of tumour.

(2) Lymph node in which there is no evidence of infiltration.'

Progress

A progress report from the patient's family doctor on 20 July (3 months after operation) stated that she was very well,

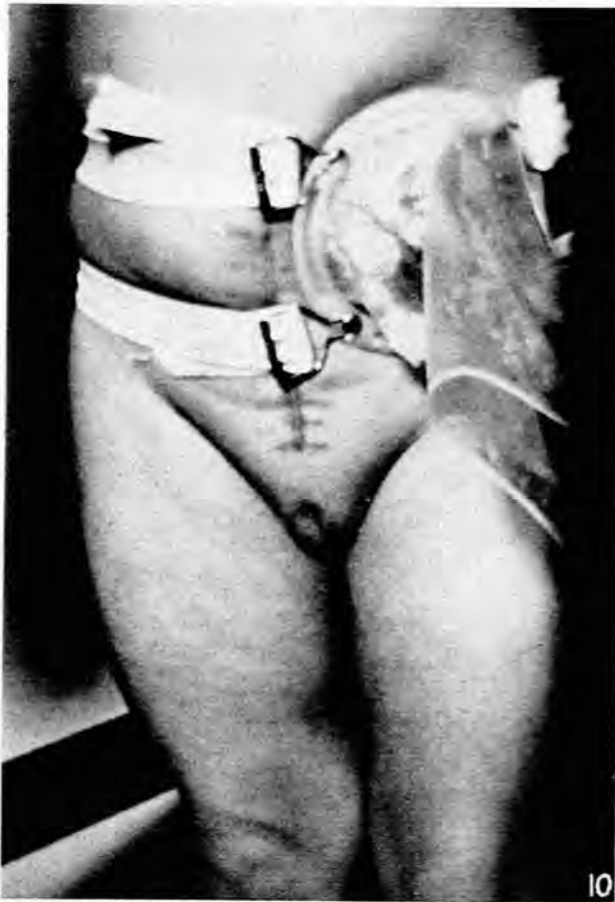

Fig. 10. Belt and disposable colostomy bag in position — case 2.

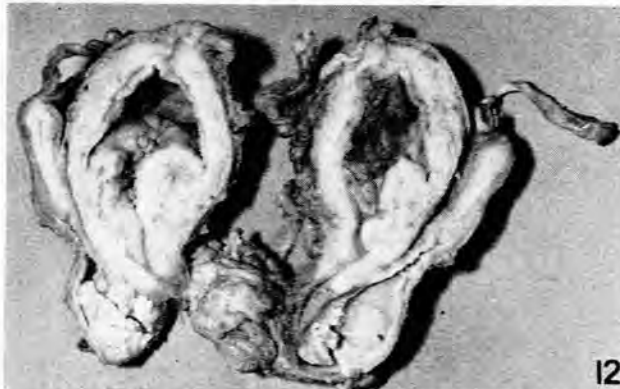

Fig. 12. The bladder, urethra, vulva, vagina and uterus *en bloc*. Polypoid grape-like structures are seen in the anterior wall of the vagina. The tumour extends into the bladder and involves the urethra. The uterus is not infiltrated — case 2.

continent of urine, and showed no signs of recurrence. Six months after the operation she was still in excellent health, well adjusted and happy.

COMMENT

The radical treatment employed in these 2 little girls may be criticized by some on the grounds that such 'mutilation'

is not justifiable. To such critics Daniel, Koss and Brunshwig⁸ have retaliated by stating: 'It is unfortunate that advice proffered to parents of children with these tumours may be from physicians who are not aware that this can be a curable disease or from those who believe it "better to be dead than alive with some organs missing"'.

In his book 'The Surgeon and the Child', Willis Potts¹⁷ devoted a whole chapter to the problem of the treatment of the deformed child. His wise observations are equally applicable to the problem of pelvic exenteration for sarcoma botryoides and are therefore freely quoted in the following paragraphs.

The late Cardinal Samuel Stritch stated that 'one may, but need not, use extraordinary means to preserve life'. The problem is to distinguish what is extraordinary and what is ordinary, and an infallible answer to the question of performing or withholding a 'mutilating' operation is not always available. Suffice it to say that in the case of sarcoma botryoides the 'ordinary' methods of treatment have proved a hopeless failure. In the circumstances is it reasonable to regard pelvic exenteration as 'extraordinary'? If not so, is it justifiable to withhold such treatment?

It is well to remember that life is the most precious thing in the world. It might be argued that life is not worth while when burdened with deformities that make social seclusion necessary and marital love impossible. On the other hand it may be; and, besides, is the child without pelvic viscera indeed a social menace and a hopeless creature?

Hundreds of children born with deformities of the anus have in the past grown up with colostomies without suffering any physical or psychological ill effects. Thus far no complications have followed the urinary diversion in either of our patients and experience with children suffering from ectopia vesicae has proved that a child with an artificial bladder can grow up normally. Neither of our patients has as yet suffered any serious psychological setback, and provided the hearts of these little children are sunned by love, security and understanding, they are perfectly capable of overcoming the physical insult inflicted upon them. The absence of a vagina may prove an obstacle, but with modern plastic surgery this is not insurmountable. Moreover, even those who advocate conservative surgery must sacrifice the vagina, or offer the terrible alternative of a slow and painful death from local recurrence, infiltration of the bladder with urinary retention, and rectal invasion with haemorrhage, ulceration and intestinal obstruction.

Finally, what about the parents? It is difficult to measure devotion or to sound the depths of love for a living thing. Those who have been fortunate enough to have been spared the tragedy of a seriously deformed child are incapable of guiding or advising the unfortunate. We believe that the surgeon must honour the parents' choice; if that is in favour of operation, everything possible must be done to save the unfortunate child. Our duty as doctors is crystal-clear — to preserve life and make it as tolerable as possible.

SUMMARY

Sarcoma botryoides, a rare tumour, but the most commonly seen malignant tumour of the uterus and vagina in children, is discussed. Its grave prognosis is stressed.

The case histories of two patients, treated recently at the Red Cross War Memorial Children's Hospital, Rondebosch, are given.

A girl, aged 2 years 7 months, was treated by total pelvic exenteration with urinary diversion, the ovaries being spared. The other patient, a girl aged 2 years 6 months, was treated by anterior pelvic exenteration, sigmoid colostomy and implantation of the ureters into the rectal stump. The ovaries were also spared.

The moral and ethical considerations in 'mutilating' operations of this nature are discussed.

We wish to thank Dr. J. F. W. Mostert, Medical Superintendent of the Red Cross War Memorial Children's Hospital, for permission to use the case records. We are greatly indebted to Dr. D. McKenzie, Senior Pathologist, and his staff for the morbid anatomical and histological data. We would also like to thank all other colleagues on the staff of the hospital for their cooperation and assistance.

REFERENCES

1. Amolsch, A. L. (1939): *Amer. J. Cancer*, **37**, 435.
2. Creardick, R. N. (1954): *Amer. J. Obstet. Gynec.*, **68**, 567.
3. Daniel, W. W., Koss, L. G. and Brunschwig, A. (1959): *Cancer*, **12**, 74.
4. Döderlein, G. (1939): *Beitr. path. Anat.*, **103**, 226. (Quoted in *op. cit.*¹)
5. Dügge, M. (1930): *Virchows Arch. path. Anat.*, **277**, 1.
6. Duncan, A. S. and Fahmy, E. C. (1953): *J. Obstet. Gynaec. Brit. Emp.*, **60**, 86.
7. Dwyer, W. A. (1944): *Amer. J. Obstet. Gynec.*, **48**, 119.
8. Friedland, L. M. (1951): *A.M.A. Arch. Neurol. Psychiat.*, **66**, 491.
9. Grünicher, E. (1888): *Inaugural Dissertation*, Munich, Germany. (Quoted in *op. cit.*¹)
10. Gross, R. (1953): *The Surgery of Infancy and Childhood*. Philadelphia and London: W. B. Saunders.
11. Guersant, M. P. (1854): *Moniteur hôpitaux*, **2**, 187. (Quoted in *op. cit.*¹)
12. McFarland, J. (1935): *Surg. Gynec. Obstet.*, **61**, 42.
13. Ober, W. B. and Edgecomb, J. H. (1954): *Cancer*, **7**, 75.
14. Ober, W. B., Smith, J. A. and Rouillard, F. C. (1958): *Ibid.*, **11**, 620.
15. Okmian, L. and Livaditis, A. (1959): *Acta paediat. (Uppsala)*, **48**, 614.
16. Pfannenstiel, J. (1892): *Virchows Arch. path. Anat.* **127**, 305. (Quoted in *op. cit.*¹)
17. Potts, W. J. (1959): *The Surgeon and the Child*. Philadelphia and London: W. B. Saunders.
18. Reisach, A. (1920): *Strahlentherapie*, **37**, 341. (Quoted in *op. cit.*¹)
19. Richmond, E. L. (1953): *Amer. J. Obstet. Gynec.*, **65**, 201.
20. Shackman, R. (1950): *Brit. J. Surg.*, **38**, 26.
21. Sternberg, W. H., Clark, W. H. and Smith, R. C. (1954): *Cancer*, **7**, 704.
22. Swenson, O. (1958): *Pediatric Surgery*. New York: Appleton-Century-Crofts, Inc.
23. Ulfelder, H. and Hendren, W. H. III (1960): *Clin. Obstet. Gynec.*, **3**, 175.
24. Ulfelder, H. and Quan, S. H. (1947): *Surg. Clin. N. Amer.*, **27**, 1240.
25. Volkmann, R. (1885): Quoted in *op. cit.*¹