

## PHAECHROMOCYTOMA IN A CHILD: A CASE WITH SOME UNUSUAL FEATURES

C. R. RAINIER-POPE, M.B., CH.B., D.C.H., *Department of Child Health, University of Cape Town, and Red Cross War Memorial Children's Hospital, Rondebosch, Cape*

The diagnosis of phaeochromocytoma in children is becoming increasingly frequent and 42 cases have been reported in children under the age of 14 years. Daeschner *et al.*,<sup>1</sup> in 1954, reviewed 17 cases, and 2 years later a review of 24 cases by Moore and Shumacker<sup>2</sup> appeared and 2 further cases with successful operative removal were reported by Robinson and Williams.<sup>3</sup>

A number of comprehensive reviews of phaeochromocytoma in childhood have appeared in the literature.<sup>4,2,5</sup> Of the 24 cases in Moore and Shumacker's list,<sup>2</sup> 6 are not recorded among the 32 reported by Smid and Du Shane.<sup>4</sup> To these are to be added the case reported by Higgins,<sup>6</sup> and 3 familial cases reported by Cone *et al.*<sup>5</sup> One of the last-mentioned 3 patients, a boy, required a further operation 29 months after the first, for the removal of a second tumour occurring in the neck.<sup>7</sup> Popper and Theron,<sup>8</sup> in 1954, reported a case of a phaeochromocytoma in a Bantu child in Johannesburg. It appears that the case presented here is thus the second one under the age of 14 years described in South Africa.

In dealing with a case of hypertension, any medical student will include a phaeochromocytoma in his differential diagnosis, though the incidence of this tumour is very small. In the majority of reports on the condition in childhood, persistent hypertension has been the prominent sign. The paroxysmal hypertension so characteristic of the disease in the adult is seldom seen. In the 24 cases in children reviewed by Moore *et al.*<sup>2</sup> only one showed paroxysmal hypertension. Symptoms produced by the tumour are usually related to the excessive production of adrenaline or noradrenaline. Apart from the hypertension, prominent symptoms are headaches, abdominal pain, sweating with cold extremities, palpitations, and polydipsia. Raised basal metabolic rate, hypertensive retinopathy, loss of weight and albuminuria are also common features.<sup>1</sup>

The tumour itself may produce manifestations that are sometimes misleading. In Cone's case<sup>5,7</sup> the second tumour presented as a swelling in the neck, with Horner's syndrome. In the following case report the patient presented with an unexplained pyrexia.

### CASE REPORT

E.N., a 10-year-old Indian boy, was admitted to the Red Cross War Memorial Children's Hospital for the first time in June 1958. He complained of headache, fever and abdominal pain for 1 month, and there was loss of weight, dizziness and sweating attacks.

He was a thin boy weighing 48 lb. The respiratory, nervous and cardiovascular systems were normal. Temperature 102°F. No abnormal blood pressure noted. Hb. 7.2 g.%; w.b.c. 14,600 per c.mm. (polymorphs. 92%, lymphocytes 6%, mononuclears 2%); ESR 160 mm. in first hour, Westergren. Mantoux positive 1/1000. X-ray of chest and abdomen, intravenous pyelography, agglutination reactions, Wasserman reaction, ECG, and bacteriology of stools and urine, were all normal. Serum protein—total 7.76 g.%, (albumin 2.5, globulin 5.2).

Because of the positive Mantoux reaction, fever, and raised erythrocyte sedimentation rate a diagnosis of tuberculosis was made, though the site of the lesion was not apparent. The boy was given

isoniazid and para-aminosalicylate and the temperature and sedimentation rate fell to normal. He was kept on this therapy for 6 months, when it was discontinued. He then became ill again with a recurrence of all his previous symptoms.

In February 1959 he was readmitted. This time his weight was 54 lb., his temperature 100.2°F and he was sweating profusely. The urine showed a trace of albumin. Serum albumin 3.21 g.%, globulin 5.17. All the previous tests were repeated and confirmed. In addition, X-ray of the spine and skull, and air encephalograms, were normal. The ESR was 136 mm. Westergren.

He was treated with streptomycin and isoniazid once more and, because of his severe headache, a lumbar puncture and air encephalograms were done. The cerebrospinal fluid showed a protein of 200 mg.%, (globulin ++), but was otherwise normal. Following this investigation he complained of headache and sweated profusely. Six hours later he developed right-sided convulsions (B.P. 130/90 mm. Hg), from which he completely recovered in 24 hours. The CSF was normal 2 weeks later and the temperature had by then returned to normal. He continued to have symptoms, however, but was discharged, to be followed up as an out-patient. The elevated blood pressure was not investigated further.

In August 1959 he was admitted again for reappraisal. The same examination was made as before. The temperature was 99°F but it settled after 24 hours and remained normal without specific treatment. The ESR was 145 mm. Westergren and the blood pressure 135/90 mm. Hg. [The urine on occasion showed a trace of albumin. Serum albumin 2.77 g.%, globulin 5.15, gamma globulin 1.03. Muscle biopsy was done and L.E. cells looked for in the peripheral blood because disseminated lupus erythematosus or polyarteritis nodosa was suspected. There was no evidence of a collagenosis, however.

The patient always perspired excessively, but this was attributed to a tuberculous infection. Because of the raised blood-pressure reading and albuminuria, the blood pressure was measured daily and the urine tested. It was thus found that on occasion the blood pressure would be 150/130 mm. Hg (see below), and sweating was possibly more marked at such times, though the correlation was not at all dramatic. At other times the blood pressure was 130/90. Because of the paroxysmal hypertension a diagnosis of phaeochromocytoma was suspected. No significant association between the raised blood pressure and the hyperhidrosis was considered until that suspicion arose. Urine specimens were therefore tested for catecholamines. The positive results of the test and the method

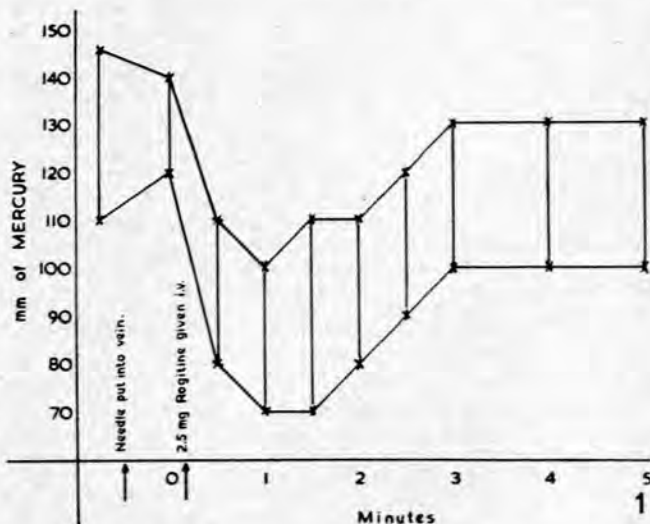


Fig. 1. Case E.N. Showing reaction of blood pressure to phentolamine

employed are fully discussed elsewhere\* by Professor Sapeika.<sup>9</sup> Because of his findings a phentolamine (rogitine) test was performed as described by Gifford *et al.*<sup>10</sup> The result was positive. An immediate drop in blood pressure followed an intravenous injection of 2.5 mg. of phentolamine (Fig. 1). On these grounds a laparotomy was performed under general anaesthesia, the surgeon electing to dispense with any attempt at localization. No specific pre-operation therapy was given.

#### Operation

Before the operation was begun the right brachial artery was cannalized through a small incision and a polythene catheter inserted into the artery. The patient was then connected to a 2-channel electrocardiograph and pressure-recording apparatus. Throughout the operation continuous blood-pressure and ECG monitoring was thus possible. An intravenous drip infusion of 5% dextrose was started in the other arm. A 2-way tap on this circuit enabled immediate intravenous injections to be given as required. A transverse upper abdominal incision was used. At the commencement of the operation the blood pressure was 150/110 mm. Hg. The left adrenal area was explored and a large tumour found and removed. With the handling of the tumour there was a sharp rise in blood pressure to 220/170 which was well controlled by 2.5 mg. of phentolamine, the pressure falling to 140/90 in 1½ minutes. Later there was a slow rise again to 215/197. The other side was explored and another tumour found. This was then also removed. The whole of the left adrenal was removed, but only a piece of the right adrenal. With the removal of the second tumour there was a sharp fall in blood pressure to 60/50. A noradrenaline drip was commenced, 4 mg. of 'levophed', dissolved in 200 c.c. of 5% dextrose, being given intravenously as well as 100 mg. of 'solucortef' (hydrocortisone sodium succinate). The blood pressure returned to 90/80 and 15 minutes later was 110/75. Post-operatively, hydrocortisone was given intramuscularly in decreasing amounts for the next 7 days. Initially 100 mg. of hydrocortisone was given 8-hourly for the first 16 hours after the operation. Thereafter 50 mg. was given 8-hourly for 24 hours, gradually reducing the dose by 25 mg. a day.

During the immediate post-operative period a continuous noradrenaline drip was maintained. For the first 10 hours 4 mg. of 'levophed' (noradrenaline bitartrate) dissolved in 200 c.c. of 5% dextrose was given. The systolic blood pressure was maintained at between 110 and 120 mm. Hg. For the next 10 hours, 3 mg. was given in 200 c.c. of 5% dextrose and then 2 mg. in 200 c.c. of 5% dextrose over 5 hours. As the blood pressure remained constant the 'levophed' was decreased to 1 mg. in 200 c.c. of Darrow's solution over the next 9 hours, and then to 0.5 mg. for the next 7 hours. The systolic blood pressure remained at 120 mm. Hg. and so the drip was discontinued 41 hours after the operation. No further fall occurred. During this time no fluids were given by mouth.

#### Pathology Report (Dr. L. Anstey)

Specimens consist of two circular tumours. The left weighed 79.6 g. and measured 7 × 5 × 4½ cm. The adrenal gland capped the tumour. On cut section the periphery of the tumour was fleshy and pink in colour, while in the centre there was a yellowish area of necrosis 3 cm. in diameter. In this was an area of haemorrhage 1 cm. in diameter.

The right tumour weighed 38.4 g. and measured 4½ × 2½ × 5 cm. On cut section the tumour was uniformly fleshy, with one small area of haemorrhagic discoloration. There was a small tag of tissue at one pole, but this did not appear to be adrenal.

**Histology.** Both tumours consisted of groups of large cells surrounded by narrow trabeculae of connective tissue within which thin-walled blood vessels were discernible. There were large areas of haemorrhage and necrosis in both tumours.

**Comment.** The features of both tumours are those of pheochromocytoma. There was no evidence of malignancy in the sections examined.

#### Follow-up

The patient has subsequently been seen 5 months after operation. The blood pressure remains normal and he has gained 9 lb. in weight. There was a recurrence of his pyrexia and the raised blood sedimentation rate, but this has now returned to normal. The reversal of the albumin-globulin ratio is still present. Post-operative urine examination revealed no catecholamines.

\* See page 257 of this issue.

#### DISCUSSION

Some of the features presented in this boy were quite typical of the disease in children described by previous authors and now well documented. The majority of cases, however, have shown persistent hypertension and their symptoms were usually related to this. Bilateral tumours are not common and this is the first case reported from this country in which multiple tumours have occurred in a child under the age of 14 years.

This patient presented some interesting features that were not fully elucidated. These were the raised sedimentation rate, fever, and reversal of albumin-globulin ratio. Considering, however, that both tumours had areas of haemorrhagic necrosis in them, it is possible that this was responsible for the fever and increased ESR. These are certainly well-recognized features of necrosis occurring in tumours in adults. There was, however, in the strongly positive Mantoux, evidence of an infective aetiology, and initially the expected response to anti-tuberculous therapy gave no reason to suspect any other pathology. It was only later, when investigation of a suspected intracranial tuberculoma produced collapse, that attention was drawn to the blood pressure. It was then realized that an earlier recording of the blood pressure had been overlooked. From this point onwards the investigations were diverted into an entirely different channel and it quickly became apparent that a pheochromocytoma was probably present.

It was intended to try to obtain further evidence, by pyelograms and retroperitoneal air studies, of suprarenal abnormality but, in view of the upset which had followed encephalography and the inconclusiveness of these procedures, the surgeon decided to explore the abdomen without further delay.

The episode associated with the air encephalogram was probably due to hypertensive encephalopathy. The reversal of the albumin-globulin ratio remains unexplained. As there was persistence of this reversal 5 months after operation, it is postulated that the patient must still have some illness that has not been elucidated.

#### Management

It is advised by Daeschner *et al.*,<sup>1</sup> Robinson *et al.*,<sup>3</sup> and others, that pre-operative phentolamine should be used to control the hypertension. This is probably not necessary when the hypertension is paroxysmal and was not done in this case.

Once the diagnosis has been made, it is unnecessary to delay operation. Localization of the tumour by presacral insufflation has been recorded on a number of occasions. It is not very reliable and is also unnecessary. Wide laparotomy should be the rule, especially as 20% are cases with multiple tumours<sup>11</sup> and the abdomen will always have to be explored. An approach to the kidney through the loin has often proved unsatisfactory for this reason.

Constant blood-pressure monitoring with a 2 channel recording apparatus was extremely helpful during the operation. Changes in cardiac rhythm and blood pressure could be detected immediately and remedied by appropriate measures. The readings are accurate and instantaneous and the continuous record is incomparably superior to the use of a sphygmomanometer. The mortality rate from the condition has been high: Moore *et al.*<sup>2</sup> recorded 13 deaths out of the 24 cases which they reviewed. It is probable that more careful

management of blood pressure during the operation may help to prevent this in the future.

The diagnosis of a functionally active phaeochromocytoma depends on two physiological approaches. These are (1) the use of adrenergic agents such as phentolamine or benzodioxane, and (2) the determination of catecholamines in the blood or urine. The value of testing for catecholamines in the urine of the patient was well demonstrated. Neither the phentolamine<sup>10</sup> nor the benzodioxane<sup>12</sup> test is infallible and both sometimes give false negative results. In this patient the response to phentolamine as a test and also during operation was very good. Provocative tests with histamine are only of value in a patient with paroxysmal hypertension, but are dangerous. The demonstration of urinary catecholamines remains a most satisfactory investigation in the diagnosis of phaeochromocytoma.

#### SUMMARY

1. The increasing number of cases of phaeochromocytoma reported in childhood is indicated. With this present one, 43 cases have been recorded in the literature.

2. A detailed history of an unusual case of phaeochromocytoma is given.

3. Continuous direct blood-pressure and electrocardiographic monitoring is advised as a satisfactory means of keeping a check on the patient's condition during operation.

4. The value of testing the urine for catecholamines in the presence of unexplained hypertension is reaffirmed.

I should like to thank Dr. J. W. F. Mostert, Superintendent of the Red Cross War Memorial Children's Hospital, for his permission to publish this case, Prof. F. Ford for his help, Prof. J. H. Louw, who performed the operation, and Dr. L. Anstey for the pathology report.

#### REFERENCES

1. Daeschner, C. W., Moyer, J. H. and Able, L. W. (1954): *J. Pediat.*, **45**, 141.
2. Moore, T. C. and Shumacker, H. B. (1956): *Ann. Surg.*, **143**, 256.
3. Robinson, M. F. and Williams, A. (1956): *Arch. Dis. Childh.*, **31**, 69.
4. Smid, A. C. and Du Shane, J. W. (1955): *Amer. J. Dis. Childh.*, **90**, 81.
5. Cone, T. E., Allen, M. S., Pearson, H. A. (1957): *Pediatrics*, **19**, 44.
6. Higgins, F. E. (1957): *Arch. Dis. Childh.*, **32**, 240.
7. Cone, T. E. (1958): *Pediatrics*, **21**, 994.
8. Popper, E. N. and Theron, P. (1954): *S. Afr. Med. J.*, **28**, 286.
9. Sapeika, N. (1960): *Ibid.*, **34**, 257.
10. Gifford, R. W., Roth, G. M. and Kvale, W. F. (1952): *J. Amer. Med. Assoc.*, **149**, 1628.
11. Wilkins L. (1957): *The Diagnosis and Treatment of Endocrine Disorders in Childhood and Adolescence*, 2nd. ed. Oxford: Blackwell Scientific Publications.
12. Goldenberg, M. and Aranow, H. (1950): *J. Amer. Med. Assoc.*, **143**, 1139.