

FEMALE URETHRA USED FOR INTERCOURSE

G. P. CHARLEWOOD, F.R.C.S. (EDIN.), F.R.C.O.G., *Coronation Hospital, Johannesburg*

A Bantu patient, aged 29, was admitted to the Bridgman Hospital, Johannesburg, in March 1958, where she had what was thought to be a normal confinement. During labour it was found to be very difficult to assess the dilatation of the cervix, presumably because the examining finger was in the urethra and not in the vagina.

Two weeks later it was found that faeces was leaking *per vaginam* from a rectovaginal fistula just behind the perineal body. The urethra admitted 2 fingers easily and the patient stated that this was the orifice which she used for coitus. The vagina was found to be a very narrow orifice which would not admit a little finger. The rectovaginal fistula was repaired successfully at Coronation Hospital.

The patient gave a history of being unable to hold her urine for about half an hour after intercourse.

COMMENT

It is surprising that a normal female urethra can be dilated sufficiently for intercourse and yet remain continent. I found only 1 previous reference to a urethra having been used for intercourse.¹ This patient remained sterile, which is to be expected. My patient must be considered fortunate to have become pregnant at all, and it is surprising that labour should have been comparatively uneventful through her narrow vagina. Since the patient was perfectly happy as she was, no attempt was made to dilate the narrow vagina.

1. Lick, M. (1948): *Urological Oddities*, p 142. Los Angeles: Bradley Dakin.

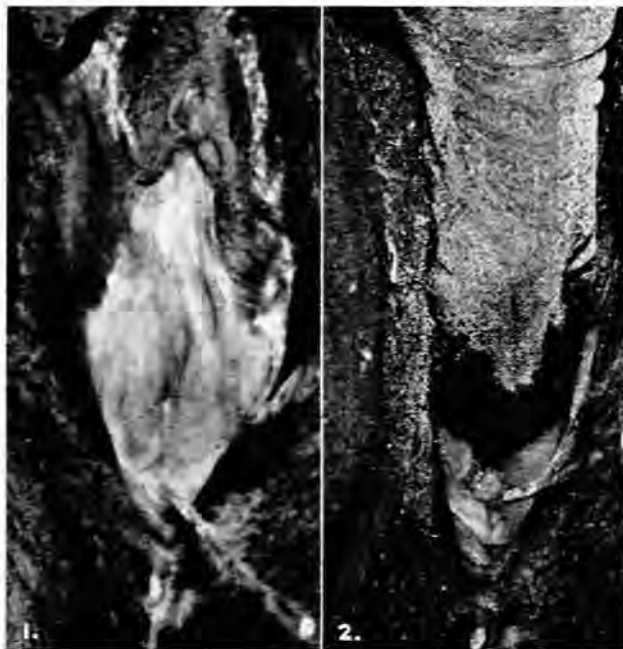


Fig. 1. Appearance of patulous urethra. A probe is seen in the vagina.

Fig. 2. A gloved finger shown in the urethra with a probe in the vagina.