

# RUPTURE OF THE STOMACH IN THE NEWBORN

ROY O. WISE, F.R.C.S., *Department of Surgery, University of Natal*

This condition was first reported by Siebold<sup>1</sup> in 1825, since when 68 cases have been reported. The first case treated successfully by surgery was reported by Legar *et al.*<sup>2</sup> in 1950. Vargas *et al.*<sup>3</sup> reported 11 cases in 1955, 8 of which had been operated upon, with 2 survivals. At that time a total of 55 cases had been reported. In 1959 Linkner and Benson<sup>4</sup> reported 13 cases operated upon, with 6 survivals.

Following is a report, one of 2 cases which have presented at the King Edward VIII Hospital, Durban, within the last 5 years.

The other one is to be published shortly.<sup>5</sup>

## CASE REPORT

B.S., an African female infant, was born in April 1959. The pregnancy was normal and she was delivered at term by a pupil-midwife without any difficulty. At birth the infant weighed 6 lb. 6 oz. and no abnormalities were found on examination at this time.

It was noticed 48 hours after birth that the infant had a markedly distended abdomen, and up to that time had passed no meconium. There had been no vomiting. The infant was found to be listless, apathetic and rather ill. The abdomen was grossly distended and the subcutaneous veins coursing over its surface gave it an unhealthy marbled appearance. The flanks were markedly distended. On palpation the abdomen was soft although the infant obviously resented this procedure. A fluid thrill was elicited from flank to flank. On rectal examination a finger could not be introduced more than 3-4 cm., nor could a lubricated catheter be

advanced beyond this point. A diagnosis was made of intestinal obstruction with perforation of bowel secondary to ano-rectal atresia.

A straight X-ray of the abdomen revealed some free gas beneath the diaphragm, but this was small in amount compared to the large amount of fluid, which gave the rest of the abdomen a typical ground-glass appearance. There was no visible gas bubble in the stomach. A film in the inverted position showed free gas in the pelvis (Fig. 1).

A blood drip was set-up and shortly afterwards laparotomy was carried out under general anaesthesia.

A right paramedian muscle-splitting incision was made. When the peritoneal cavity was opened, gas and a large amount of turbid fluid escaped. The free fluid was aspirated and the abdominal contents examined. The rectum was not atretic, but it was very narrow and collapsed. A catheter could be passed *per rectum* and guided into the sigmoid, but only with difficulty. The rest of the bowel was narrow and collapsed. There was an incomplete rotation of the bowel but no volvulus. The small bowel, and most of the large bowel, were suspended from the posterior abdominal wall by a very short mesentery. A thickened band of tissue crossed the 2nd part of the duodenum but otherwise the duodenum was patent. The small and flimsy greater omentum had milk curds and pieces of fibrin adherent to it.

The stomach, which was about 2½ inches long, was almost completely everted through a linear rupture 1½ inches long, which extended parallel and adjacent to the greater curvature from the fundus down to the pyloric antrum. The edges of the tear were thin and transparent and did not bleed, and the surrounding stomach showed no evidence of induration, ulceration or necrosis.

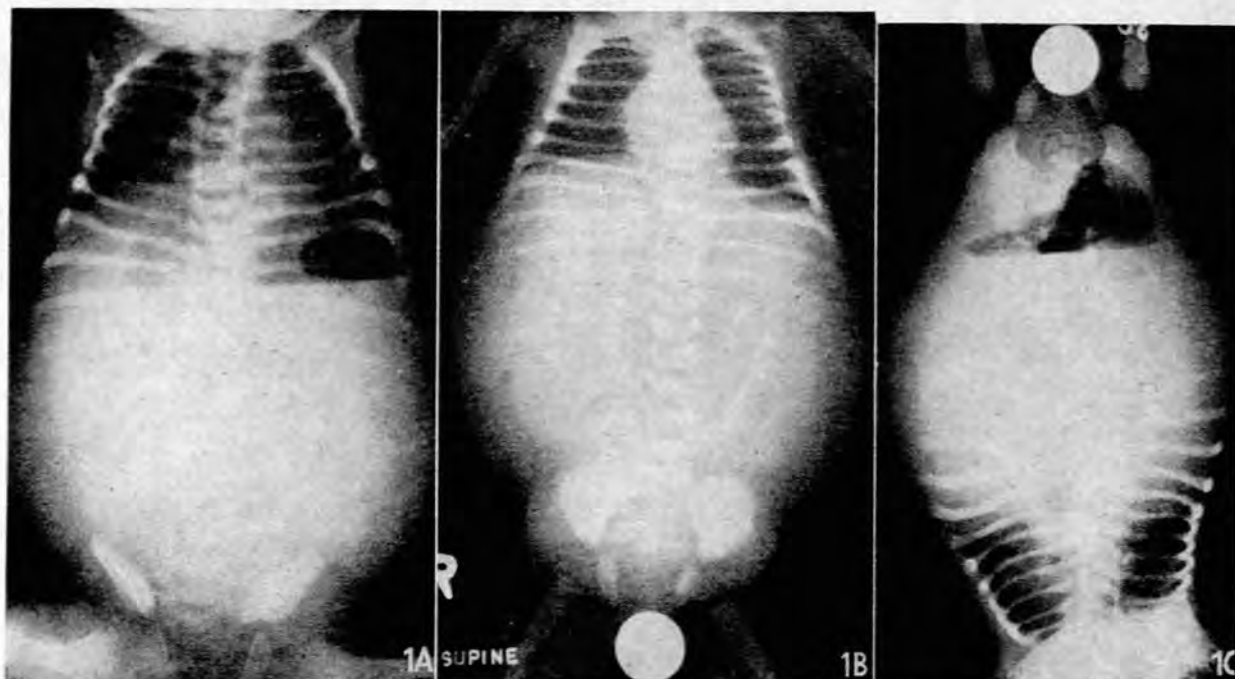


Fig. 1A. Erect film, showing free gas beneath the diaphragm. Fig. 1B. Recumbent film, showing a small amount of free gas, distended flanks, and the ground-glass appearance due to free fluid. Fig. 1C. Inverted film, showing free gas in the pelvis and fluid level.

The band crossing the duodenum was divided. The stomach was closed in two layers with an all-coats suture of continuous catgut and an outer layer of continuous silk. The abdomen was closed without drainage.

Post-operatively the infant was kept on intermittent gastric suction and intravenous fluid therapy. Penicillin and streptomycin were given. She died, however, 36 hours later. A necropsy could not be obtained.

#### DISCUSSION

The clinical picture is fairly constant and the presentation of this case is similar to the other reported cases. Pregnancy is uncomplicated as a rule and delivery is usually normal. Prematurity does not appear to be a factor of any great significance. The sex incidence varies in the reported series. The infant feeds normally at first and, unless there is an associated obstruction, stools will be passed normally.

The perforation occurs most commonly on the 2nd, 3rd or 4th day of life and almost always within the first 2 weeks. The onset is sudden. The abdomen distends rapidly and the child becomes apathetic, with a feeble cry. The abdomen is distended but soft. Vomiting is infrequent and when it occurs usually amounts to regurgitation or, less commonly, frank haematemesis. The abdominal distension may eventually lead to respiratory difficulty with cyanosis, and ultimately dehydration and shock will ensue.

The straight X-ray of the abdomen is typical. It shows (1) free gas and free fluid, and (2) absence of the gastric air bubble. Free gas is easily missed in a recumbent film (Fig. 1). In most cases the amount of free gas is so great as to outline the liver quite clearly. In the present case the free gas was less than usual.

The evidence presented by this case suggests that the rupture was due to a congenital deficiency of the gastric musculature. The site was typical and the absence of changes in the neighbouring mucosa excludes acute peptic ulceration and septi-

caemic pathology. Furthermore, there were other congenital abnormalities in the intestinal tract. These most probably contributed towards the rupture by acting as distal obstruction.

#### Aetiology

Until 1943 it was believed that this condition was due to perforation of a gastric ulcer. In that year, however, Herbut<sup>6</sup> clearly showed that in his case a congenital deficiency of the gastric musculature, resulting in a weakness of the stomach wall, was the cause. This has been confirmed subsequently in many cases. In one case described by Vargas *et al.*<sup>3</sup> there existed a diverticulum as a result of muscle deficiency which had subsequently perforated (Fig. 2). Perforation, however,



Fig. 2. Congenital gastric muscle deficiency causing (left) perforation of gastric diverticulum, (right) rupture of stomach.

may occur as a complication of acute gastric ulceration. The cause of this ulceration in the newborn is not always clear. In some cases it is a manifestation of septicaemia. In others it is associated with neonatal asphyxia and shock or with intracranial haemorrhage.

Perforation of the stomach has been reported secondary to more distal obstruction of the intestinal tract. Brody<sup>7</sup> described a case with obstruction and a proved muscle defect and the features of other cases have suggested a similar pathology.

Trauma has also been implicated. The stomach of the newborn is free of air and it is unlikely that trauma during delivery could rupture the stomach. In no case has birth trauma ever been proved to be responsible. On the other hand, perforation caused by intubation with polythene tubing is well documented.

Perforation may also occur in mucormycosis. A 6-day-old infant, with gastric perforation and peritonitis due to mucormycosis, is to be reported from this hospital shortly.<sup>5</sup>

In some cases no aetiological factor could be established at the time although the features have suggested a congenital muscle deficiency.

Thus the known causes of neonatal rupture of the stomach may be classified as (1) congenital muscle deficiency, (2) acute gastric ulceration, (3) distal obstruction, (4) trauma (gastro-intestinal intubation), (5) fungal infection (mucormycosis).

#### Pathology

1. *Congenital muscle deficiency.* Although Herbut's case<sup>6</sup> showed deficiency of muscle in several areas of the stomach wall, most recorded cases of rupture have occurred near the greater curvature of the stomach, more so in the fundal half. Three cases of perforated gastric diverticulum have also been reported in this site.

2. *Acute gastric ulceration.* The perforation associated with acute peptic ulceration does not resemble the perforated ulcer of the adult. In septicaemia there may be intramural abscesses with necrosis and a large perforation, or else a perforation may be surrounded by an indurated stomach, the seat of acute ulcers.

3. *Traumatic.* The perforation here is punctate and surrounded by minimal inflammatory change.

4. *Mucormycosis.* This is a disease caused by invasion of tissues by true fungi (Mucoraceae). Visceral mucormycosis involves the central nervous, pulmonary and digestive systems or may occur in a disseminated form. The spores are ingested

or inhaled and the fungus may invade the stomach wall, causing local infarction and ulceration. Histologically the most prominent features are the presence of pleomorphic non-septate hyphae invading haemorrhagic and necrotic tissue and thrombotic vessel walls and lumina. The diagnosis can only be made where invasion of tissues by the fungus is seen.

#### Prognosis

In the 11 cases reported by Vargas *et al.*<sup>3</sup> the survival rate was 18.1%. In the 13 cases reported by Linkner and Benson<sup>4</sup> the survival was 46.1%. The mortality is of necessity high because of the severity of associated conditions. These may include prematurity, associated congenital abnormalities, cerebral haemorrhage, and septicaemia. Prompt surgery offers the only hope for survival. The commonest cause of death in reported cases is generalized peritonitis.

#### SUMMARY

A case of rupture of the stomach in a newborn infant is presented. The clinical features and X-ray findings are described. The aetiology and pathology are discussed. The prognosis and treatment are indicated and the importance of early surgery stressed.

I should like to thank Dr. S. Disler, Medical Superintendent of King Edward VIII Hospital, for permission to publish details of the case; and Prof. A. E. Kark, in whose care the case was, for advice.

#### REFERENCES

1. Thiele, P. (1919): *Ergebn. inn. Med. Kinderheilk.*, 16, 302. Quoted by Vargas *et al.*, *loc. cit.*<sup>3</sup>
2. Legar, J. L., Richard, P. M., Leonard, C. and Piette, J. (1950): *Un. méd. Can.*, 79, 1277.
3. Vargas, L. L., Levin, S. M. and Santulli, T. V. (1955): *Surg. Gynec. Obstet.*, 101, 417.
4. Linkner, L. M. and Benson, C. D. (1959): *Ann. Surg.*, 149, 525.
5. Neame, P. B. Personal communication.
6. Herbut, P. A. (1943): *Arch. Path. (Chicago)*, 36, 91.
7. Brody, H. (1940): *Ibid.*, 29, 125.