

# South African Medical Journal

## Suid-Afrikaanse Tydskrif vir Geneeskunde

P.O. Box 643, Cape Town

Posbus 643, Kaapstad

Cape Town, 29 September 1956  
Weekly 2s. 6d.

Vol. 30 No. 39

Kaapstad, 29 September 1956  
Weekliks 2s. 6d.

### AN UNUSUAL AORTOGRAPHIC APPEARANCE

M.A. LAUTRÉ, F.R.C.S.

*Johannesburg*

Visualization of blood vessels in the human body by means of X-ray photographs taken after the injection of opaque solutions into the blood stream has made rapid progress since the procedure began to be generally employed, and what was originally considered a dramatic if somewhat hazardous manoeuvre has within the last few years come to be considered a safe routine measure. The field has become gradually widened until it includes blood vessels throughout the body; with this has come a narrowing-down of the objective so that localized areas of the vascular tree can now be brought into particular observation and studied in greater detail.

This has been made possible by the technique popularized by Seldinger, of percutaneously introducing a polythene catheter into a distal vessel and sliding it proximally so that its eye can be made to discharge the contrast medium with exactness at whatever point is to be studied. Further refinements are in progress, such as the use of magnetically controlled metal-pointed catheters or catheters with special curves, whereby the dye can be injected actually into the lumen of branches of the aorta, such as the renal or coeliac axis.

These methods have the advantage of enabling a localized region of the body to be studied at leisure with the use of only small quantities of dye—thus avoiding the risk of accidentally introducing a large volume of dye into a small vessel with possible disastrous results. Nevertheless the wisdom of indiscriminately puncturing a vessel so subject to disease as the femoral artery with a large-bore needle, must be open to question, and my limited experience in this field leads me to believe that the risks are not as negligible as current literature indicates.

Trans-lumbar aortography is still probably the safest method of visualizing the vessels of the lower limbs. The risk of causing damage by the detachment of plaques, intimal stripping, or secondary thrombosis, must obviously be smaller when puncturing the aorta

than with vessels of smaller calibre. Moreover it is a quicker and easier technique, and requires no elaborate apparatus. Care, however, must be constantly exercised in placing the injection needle so as to avoid the chance of introducing a large volume of dye into a

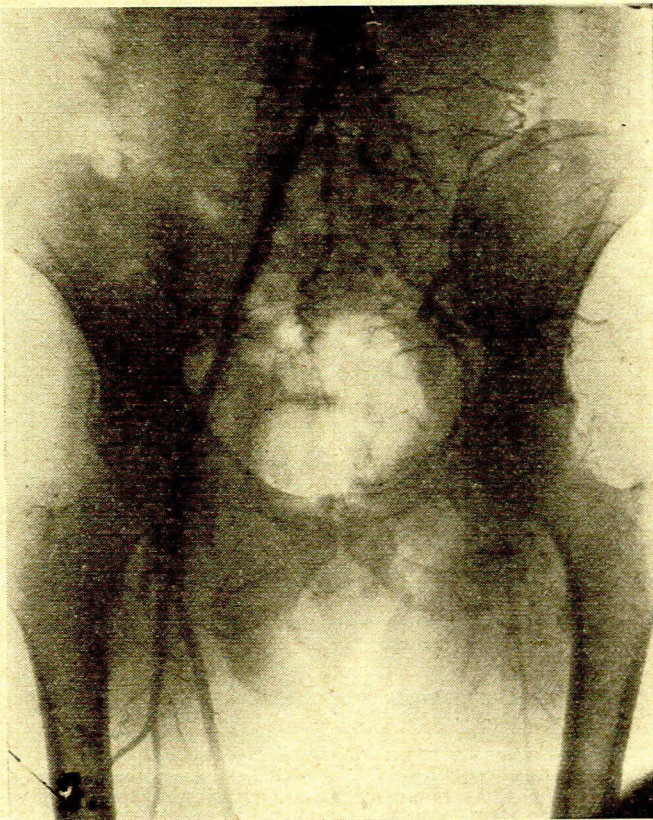


Fig. 1. Aortogram showing obstruction of left common and external iliac artery.

visceral branch. All manner of odd distributions of dye have been known to occur, depending upon the puncture site and the inclination of the bevel of the needle. This applies more particularly to diseased arteries, where a raised plaque or sharp kink may produce bizarre and misleading pictures. The following case is quoted to illustrate this point:

#### CASE REPORT

A.D., a European male aged 45, presented with a 2-year history of intermittent claudication in the left leg. The symptom had been increasing in severity over the previous 4 months and was a hindrance to him in his occupation. Physical examination showed absence of pulsation in all the arteries of the left leg, with reduced oscillometry and all other signs of arterial occlusion.

Trans-lumbar aortography showed obliteration of the left common and external iliac arteries, the common femoral being reconstituted, with some delay, by the collaterals (Fig. 1). In view of his age and general fitness and the increasing severity

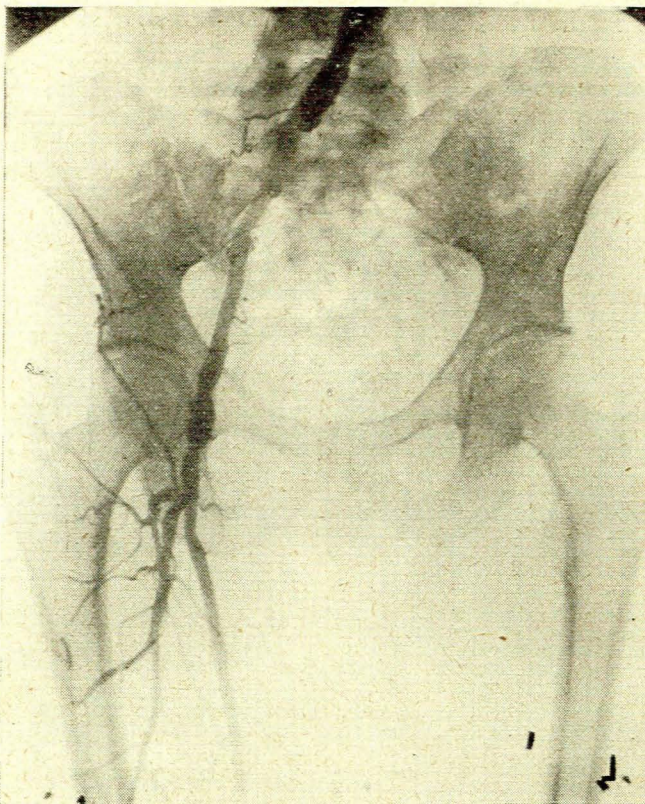


Fig. 2. Aortogram 3 months after grafting, giving fallacious impression of no patency.

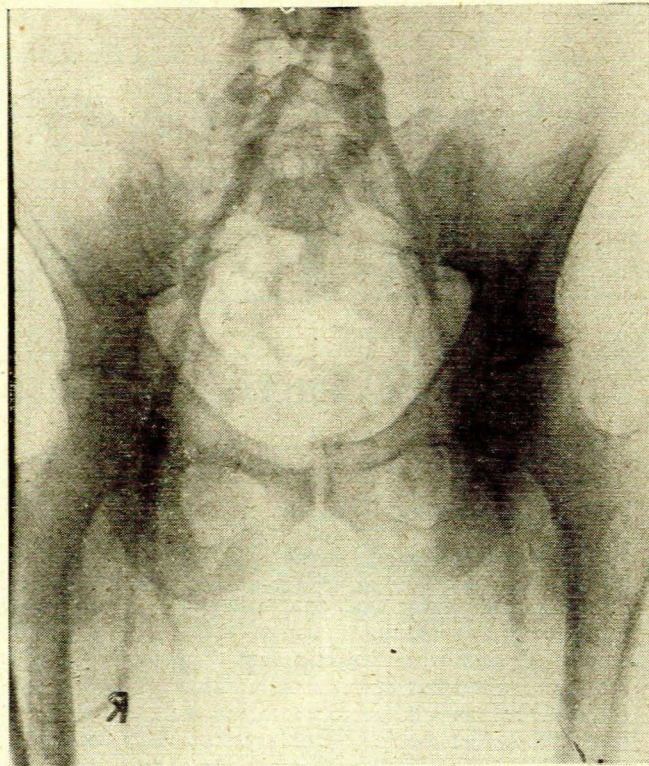


Fig. 3. Aortogram taken 24 hours after that in Fig. 2, showing graft well filled.

of his symptoms it was decided to offer him an arterial graft. This was carried out on 16 October 1955.

On exposure of the obstructed vessel it was found that the only graft available (common carotid) was not quite long enough to bridge the gap. Thrombendarterectomy of the common iliac artery was therefore carried out for a distance of about an inch, and the graft implanted end-to-side into the common iliac and end-to-end into the common femoral. The patient was heparinized during, and for the first week after the operation, and subsequently maintained on Dindevan.

When seen 3 months later he showed considerable improvement; there was a strong femoral pulsation and an appreciable pulsation in the popliteal and dorsalis pedis. He was able to walk a mile slowly.

A trans-lumbar aortogram made on 21 February 1956 showed a totally inexplicable state of affairs (Fig. 2)—a complete obliteration of all the arteries of the left leg. After accusing the radiologist of duplicity, sabotage or using a new unilateral dye, I repeated the procedure the following day, with the result shown in Fig. 3. The probable explanation of the aortogram taken on 21 February is that the needle, which was introduced just above the aortic bifurcation, had its bevel facing a protruding plaque, and that the dye was deflected to the right and swept down by the blood stream.