

ADRENAL VIRILIZING TUMOUR AND PREGNANCY

ISAAC COHEN, M.B., B.CH. (RAND), M.R.C.P. (EDIN.), *Metabolic and Endocrine Unit, Department of Medicine*, and
R. GLYN THOMAS, M.B., B.CH. (RAND), D.M.R.D. (R.C.P. & S. ENG.), *Department of Radiology*,
Johannesburg Hospital and University of the Witwatersrand

Many cases of adrenal virilism have been described, but the occurrence of a successful pregnancy and the birth of a normal female child in this condition has not been reported.

CASE HISTORY

First Admission

The patient, a White female at that time 32 years old, presented in 1953 at another hospital with a history that during the previous 2 years she had noticed progressive growth of facial hair as well as temporal recession of her scalp hair. Her voice had become 'deeper and masculine'. The menstrual cycle remained regular and normal. She had 2 children (5 and 3 years) both of whom had been breast fed.

The available relevant details of this admission (Table I) show a persistently high 17-ketosteroid excretion. No abnormality was seen on intravenous pyelogram. At laparotomy a wedge of the right ovary was removed, which on histological section showed a normal corpus luteum. Unfortunately there is no record of the adrenal gland having been examined. Post-operatively there was no improvement in the hirsuties; the estimation of the excreted 17-ketosteroids gave a high normal figure.

During the next few years the hirsuties extended to the chest, abdomen and extremities. The menstrual cycle remained normal.

Although there was difficulty in becoming pregnant, she gave birth in 1956 to a live premature child, which she breast fed. This pregnancy was complicated by threatened miscarriages.

Second Admission

The patient was referred to the Johannesburg Hospital in 1958 because of a change in her symptoms. She stated that for the previous 7 months she had developed amenorrhoea, severe acne of her body and face, progressive hirsuties, increasing strength and libido, and a gain in weight.

Examination showed a slightly 'moon-faced' young woman with extensive acne of face and body. The scalp hair was thin and dry with marked temporal recession. The facial hair was profuse and dark. The trunk and extremities were hirsute and the pubic hair was of male distribution. The blood pressure was 120/70 mm. Hg. Gynaecological examination showed a markedly enlarged clitoris. The vagina, cervix and uterus were normal. The left ovary was palpable, but not the right. The patient's 2-year-old child was examined and found to have normal external female genitalia.

Special investigations. The results of the steroid investigations are incorporated in Table I. The following laboratory data were also obtained: Haemoglobin, 16 g./100 ml. Leucocytes, 8,600/c.mm (neutrophils 61%, monocytes 6%, lymphocytes 33%,

TABLE I. EXCRETION OF 17-KETOSTEROID AND 17-HYDROXYCORTICOSTEROIDS

Date	Treatment	17-KS* (N 6-14)	17-OH-CS* (30) (N 4.9 - 12.3)	Total 17-OH-CS* (31) (N 6-17)
24 Jan. 1953		49.3		
7 Feb.		25.2		
8 Feb.		23.5		
20 Apr.		33.0		
21 Apr.		33.0		
29 May	1st operation			
13 Sep.		20.0		
14 Sep. 1958		19.9		
	ACTH gel 40 mg./day × 3 days	51.0	8.8	36.0
	Ditto	50.0	8.8	38.4
	Ditto	51.0	14.6	46.5
	Ditto	51.0	17.5	46.0
	Triamcinolone 40 mg./day × 3 days	73.0	13.3	51.0
14 Aug.	2nd operation			
16 Aug.	ACTH gel 40 mg./day	28.0	32.4	74.0
12 Sep.		9.7	14.7	23.4
12 Dec.		11.0	5.4	16.7

*Expressed as mg. per 24 hours. N=normal.

eosinophils 0%, basophils 0%). Blood sugar—fasting, 70 mg./100 ml.; after 50 g. of glucose by mouth, 72 mg. in 90 min. Serum protein-bound iodine, 3 gamma/100 ml. Blood urea, 32 mg./100 ml. Serum potassium, 4.4 mEq./litre. Serum sodium, 135 mEq./litre. Plasma chlorides, 93 mEq./litre, serum CO₂, 27.3 mEq./litre.

On X-ray examination the bony skeleton did not show any abnormality.

On retroperitoneal air insufflation the left kidney was found to be depressed by a large rounded suprarenal mass (Figs. 1 and 2). The upper portion of the stomach was displaced forward by the mass, which on tomography was seen to be contiguous with the upper border of the left kidney. No calcification was seen within the mass. Adequate filling of the right retroperitoneal space was not obtained, but tomography showed an undisplaced right kidney without any apparent mass above it.

The clinical diagnosis of an adrenal virilizing tumour was thus confirmed radiologically and biochemically.

Operation (Prof. D. J. du Plessis). Under 'steroid cover' the adrenal tumour was removed through a translumbar incision. The mass was hemispherical and about 10 cm. in diameter. It was well encapsulated and was easily mobilized, with no evidence of infiltration into surrounding tissues. A transient episode of hypertension (200/150 mm. Hg) occurred during the manipulation of the tumour. Post-operatively there were several episodes of weakness and hypotension, which responded to intravenous cortisol. During this period the patient also received oral cortisone and intramuscular ACTH, from which she was gradually weaned.

Histological examination revealed an adenocarcinoma of the adrenal gland.

Progress. During the months after operation there was a sustained improvement; at the end of the 4th month the abnormal bodily and facial hair, the acne and the 'moon face', had completely disappeared. The menstrual cycle was re-established. Steroid excretion was now normal.

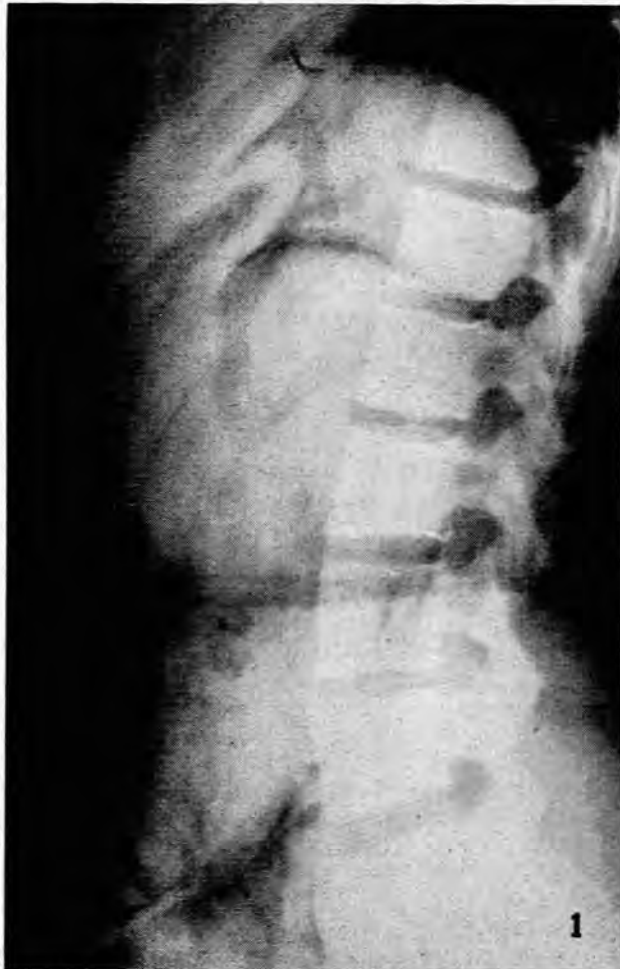

Fig. 1. Retroperitoneal gas insufflation. Lateral film demonstrating suprarenal tumour, which is depressing the kidney and pushing the stomach forwards.

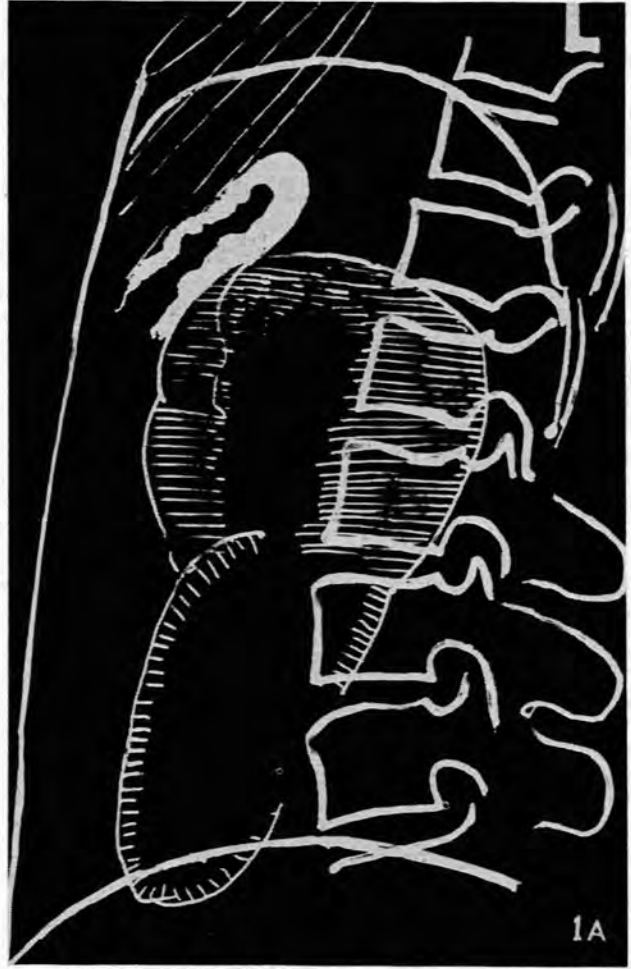


Fig. 1A. Line drawing of Fig. 1 showing the relative positions of tumour, left kidney and stomach.

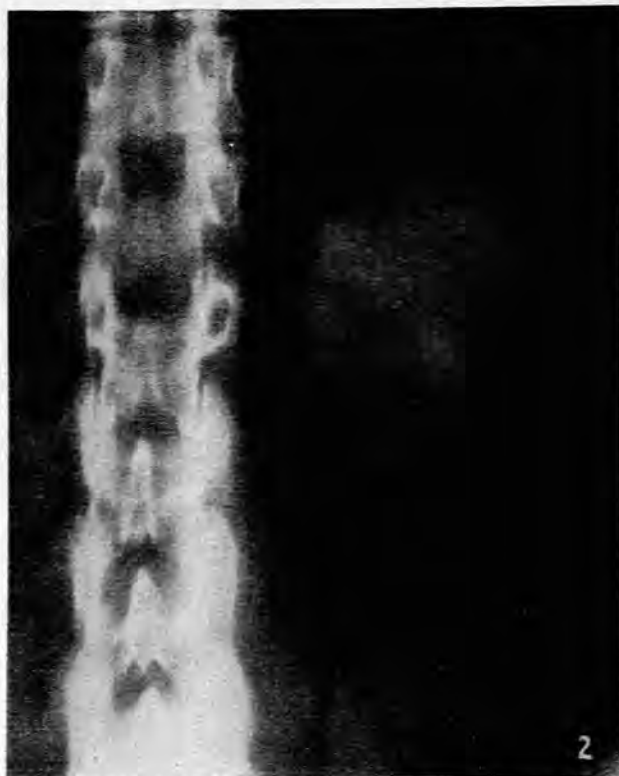

Fig. 2. Retroperitoneal gas insufflation. Supine tomographic cut showing the tumour and the kidney below it.

DISCUSSION

The literature indicates the rarity of tumours of the adrenal cortex. Steiner¹ reviewed all the necropsies at the Los Angeles County Hospital from 1918 to 1947 and found that they accounted for 0.2% of all tumours, a total of 15 cases. Heinbecker *et al.*² reported 10 of his own cases and added 83 cases from the literature. Rapaport *et al.*³ reviewed 238 hormonal and 34 non-hormonal tumours reported from 1930 to 1949; of these 72 were androgenic. In Macfarlane's series⁴ of 55 cases of adrenal tumours collected from the London teaching hospitals 35 were hormonal.

Only a few reports are to be found of a virilizing tumour of long duration. Macfarlane⁴ mentions 2 cases of 13 and 20 years' duration. Escamilla⁵ removed an adenoma in a patient who had symptoms for 30 years. In our case there was clinical evidence of virilization for 7 years and biochemical evidence of androgenic activity for 5 years. The sudden exacerbation in symptoms probably heralded the onset of malignant change.

Accurate diagnosis of the aetiology of adrenal malfunction is made possible by the study of adrenal biochemistry and radiology.

Numerous investigators⁶⁻⁹ have shown that by comparing the response of the adrenal to the administration of ACTH and to 'steroids' one can often differentiate hyperplasia from neoplasm, especially if the latter is malignant.

In our case the high levels of the resting 17-ketosteroids (17-KS) and the normal 17-hydroxycorticoids (17-OH-CS), with no change on stimulation of the adrenal cortex by ACTH nor on depression by triamcinolone, suggested an

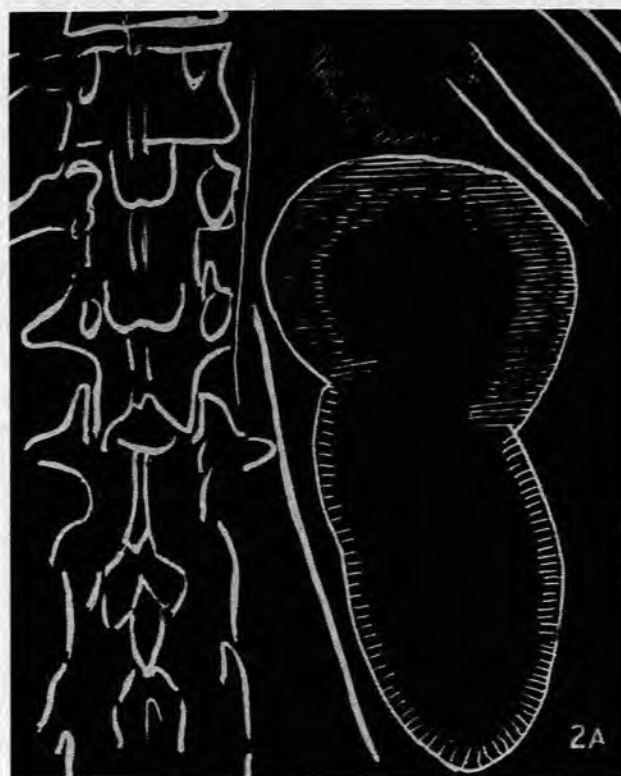


Fig. 2A. Line drawing of Fig. 2.

autonomous androgenic carcinoma. The high level of total 17-OH-CS is a measure of adrenocortical substances that are not derived from hydrocortisone, but are steroids with 17-20-diol and de-oxyketol side-chains, and are commonly found in adrenal virilism.¹⁰

In the radiological diagnosis of adrenal masses, 3 factors are concerned, namely the direct demonstration of the adrenal, the effect on neighbouring structures and, indirectly, the hormonal influence on bone metabolism and growth.

Many adrenal tumours are visible on abdominal films, especially if calcification is present, which occurs in a large proportion of carcinomata.¹¹ Presacral gas insufflation, often combined with tomography and intravenous pyelography, is being more frequently used for the investigation of retroperitoneal masses. Anderson¹² showed that this technique had a diagnostic accuracy of approximately 70%. Adequate demonstration of the adrenal may not be obtained owing to abdominal adhesions or infiltration by neoplasm, and occasionally even in the absence of abnormality. The hypertrophied gland, unlike tumours, retains its usual shape but, although criteria of the normal size have been evolved,^{13,14} moderate enlargement is difficult to discern. Aortography is useful in demonstrating vascular tumours, but is dangerous if the suspected mass is a pheochromocytoma.¹⁵ Pyelography may show forward rotation or distortion of the upper calyces of the kidney.

Excessive androgenic excretion causes accelerated development of epiphyses and their early closure, whereas increased glucocorticoid production may cause radiological osteoporosis.

Although menstruation in the presence of an androgenic adrenal carcinoma has been described,¹⁶ there has been no previous report of a successful pregnancy occurring in the presence of an adrenal virilizing tumour. The difficulty in conception and in maintenance of the pregnancy may have been a manifestation of the excessive androgenic activity. In spite of the virilization of the mother the female child showed no similar tendency. It has been shown that foetal intersex of various types can be experimentally produced in animals by the administration of androgens to the mother during pregnancy.¹⁷ Similar effects may inadvertently be produced in the human female by the administration of androgens¹⁸⁻²² and progesterone,²³⁻²⁵ although masculinization of the child is not invariable.²⁶ This latter observation has been confirmed by the birth of a normal female in a case of maternal arrhenoblastoma,²⁷ as well as in our case of adrenal tumour. However, the presence of maternal arrhenoblastoma has resulted in masculinized infants in 2 recorded instances.^{28,29}

SUMMARY

A case of adrenal virilizing tumour of many years' duration is described in a young woman. Late in the course of the disease she became pregnant and gave birth to a normal female infant. Subsequently the tumour underwent malignant change and was removed, with dramatic regression of symptoms and signs.

We wish to thank Prof. G. A. Elliott and Dr. S. Lopus for their advice and criticism and Dr. W. M. Politzer for his help with the steroid estimations.

REFERENCES

- Steiner, P. E. (1954): *Cancer, Race and Geography*. Baltimore: Williams and Williams.
- Heinbecker, P., O'Neal, L. W. and Ackerman, L. V. (1957): *Surg. Gynec. Obstet.*, **105**, 21.
- Rapaport, E., Goldberg, M. B., Gordon, G. S. and Hinman, F. (1952): *Postgrad. Med.*, **11**, 325.
- MacFarlane, D. A. (1958): *Ann. Roy. Coll. Surg. Engl.*, **23**, 155.
- Escamilla, R. F. and Johnson, S. G. (1952): *Postgrad. Med.*, **11**, 272.
- Christy, N. P., Wallace, E. Z. and Jailer, J. W. (1955): *J. Clin. Invest.*, **34**, 899.
- Lindsay, A. E., Migeon, C. J., Nugent, C. A. and Brown, H. (1956): *Amer. J. Med.*, **20**, 15.
- Laidlow, J. C., Reddy, W. J., Jenkins, D., Abu Haydar, N., Reynold, A. E. and Thorn, G. W. (1955): *New Engl. J. Med.*, **253**, 747.
- Nabarro, J. D. N., Moxham, A. and Walker, G. (1958): *J. Clin. Endocr.*, **18**, 586.
- Appleby, J. I., Gibson, G., Norymberski, J. K. and Stubbs, R. D. (1955): *Biochem. J.*, **60**, 453.
- Boyce, C. L. and Sears, W. N. (1951): *Radiology*, **56**, 731.
- Anderson, P. E. (1955): *Acta radiol.*, **43**, 289.
- Harrison, R. H. and Doubleday, L. C. (1956): *J. Urol.*, **76**, 16.
- Steinbach, H. L. and Smith, D. L. (1955): *A.M.A. Arch. Surg.*, **70**, 161.
- Saltz, N. J., Luttwak, E. M., Schwartz, A. and Goldberg, G. M. (1956): *Ann. Surg.*, **144**, 118.
- Prunty, F. T. G., Brooks, R. V. and Mattingly, D. (1958): *Brit. Med. J.*, **2**, 1554.
- Greene, R. R., Burrill, M. W. and Ivy, A. C. (1939): *Amer. J. Anat.*, **65**, 415.
- Grundwalt, E. and Bates, T. (1957): *Pediatrics*, **20**, 503.
- Hayles, A. B. and Nolan, R. B. (1957): *Proc. Mayo Clin.*, **32**, 41.
- Gold, A. P. and Michael, A. F. (1958): *J. Pediat.*, **52**, 279.
- Black, J. A. and Bentley, J. F. R. (1959): *Lancet*, **1**, 21.
- Nellhaus, G. (1958): *New Engl. J. Med.*, **258**, 935.
- Reilly, W. A., Hinman, F. Jr., Pickering, D. E. and Crane, J. J. (1958): *Amer. J. Dis. Child.*, **95**, 9.
- Wilkins, L. and Jones, H. W. (1958): *Pediatrics*, **21**, 513.
- Moncrieff, A. A. (1958): *Lancet*, **2**, 267.
- Vandekerckhove, D. (1954): *Ann. Endocr. (Paris)*, **15**, 513.
- Alexander, W. S. and Beresford, O. D. (1953): *J. Obstet. Gynaec. Brit. Emp.*, **60**, 252.
- Felicissimo Paula Xavier, J. and de Abreu Junqueira, M. (1938): *Rev. Ginec. Obstet. (Rio de J.)*, **1**, 356. Quoted by Black, *op. cit.*²¹
- Brentnall, C. P. (1945): *J. Obstet. Gynaec. Brit. Emp.*, **52**, 235.
- Reddy, W. J., Jenkins, D. and Thorn, G. W. (1952): *Metabolism*, **1**, 511.
- Appleby, J. I. and Norymberski, J. K. (1955): *Biochem. J.*, **60**, 460.