

## THE ANATOMY AND PATHOLOGY OF PREMATURE SEPARATION OF THE PLACENTA\*

I. E. VAN DEN ENDE, M.B., CH.B.

*Registrar, Department of Obstetrics and Gynaecology, Grootte Schuur Hospital  
Cape Provincial Administration and University of Cape Town*

The voluminous literature on premature separation of the placenta indicates that, although much detailed histological work has been carried out on the separated placenta, there is little unanimity of opinion regarding the pathogenesis of accidental haemorrhage, placental infarction, and premature separation of the placenta in general. This is mainly due to the void which still exists in our knowledge of the anatomy and physiology of the placental circulation.

In this paper an attempt is made to review briefly some of the latest concepts regarding (1) the anatomy of the placental circulation, both foetal and maternal, with reference to its embryological development, and (2) some aspects of the pathology of premature separation of the placenta, particularly the lesions on the maternal side of the placental circulation.

## ANATOMY OF PLACENTAL CIRCULATION

*The Foetal Placental Circulation*

Hertig and Rock have shown that at about 5½ or 6 days after ovulation the fertilized ovum is implanted upon the prepared endometrium.<sup>1</sup> On the 9th day the ovum is entirely imbedded in the decidua except for the operculum deciduae.<sup>2</sup> The syncytiotrophoblast is seen extensively invading the surrounding decidua and forming lakes or lacunae in the substance of the trophoblast.<sup>1</sup> These lacunar spaces at first contain leucocytes.<sup>3</sup> The trophoblast, by its proteolytic and cytolytic action, erodes the spiral arterioles and venules of the endometrium and the first decidual-trophoblastic circulation is established by the gradual replacement of the leucocytes in the lacunar spaces by a slow-flowing maternal blood stream. These spaces are therefore lined by a layer of syncytiotrophoblast which, in its early trabeculated form, is called the primary villus system on account of its resemblance to the future or permanent villi.

At about the 13th or 15th day after ovulation, bud-like outgrowths of cytotrophoblast appear to invade the lacunar spaces, carrying with them an outer layer of syncytiotrophoblast covering and an inner core of extra-embryonic mesoderm. These are the secondary or permanent villi, which by the 16th day form branching villi, containing vascular primordia from which are formed capillary blood vessels that will ramify over the internal surface of the trophoblast to link up with the foetal circulation *via* the vitelline vessels and establish the foetal placental circulation at about the

21st or 23rd day. Until these vessels unite, the chorionic tissues are nourished entirely by the maternal blood stream—a point in favour of the theory that the placenta is entirely dependent upon the maternal circulation for its nourishment.

As the ovum grows it extends into the uterine cavity, with resultant atrophy of the decidua capsularis and chorion laeve, until at the 12th week these two layers loosely blend with the decidua vera to obliterate the uterine cavity, while the future placenta is formed by the chorion frondosum, intimately attached to the decidua basalis.<sup>4</sup>

The villi can now be seen to consist of a double layer of trophoblast covering a loose stroma containing capillary blood-vessels. Compared with a villus at term it is seen that the nuclei of the syncytiotrophoblast have become clumped together as syncytial knots. The Langhans layer has disappeared and the stroma has become more fibrous and the capillary vessels larger, resembling capillaries seen elsewhere in the body.

All these changes are so-called degenerative changes associated with normal aging of the placenta.<sup>4</sup>

The placenta at term consists of a layer of amnion and a double layer of chorion and the blood vessels with their related cotyledons. Between the two layers of chorion run branches of the umbilical vessels—placental arteries and veins—which divide and subdivide either on the foetal surface or in the substance of the placenta, each to terminate in a cotyledon, of which there are approximately 200 in number, according to Crawford.<sup>5</sup> By further dichotomy these vessels divide to form sub-cotyledons, and finally by their finest subdivision form capillaries, which are imbedded in a stroma and covered by trophoblast—in other words, the villi.

By using a retrograde injection and digestion method to study the placental vessels histologically, Crawford<sup>5</sup> has shown a complex villus to be a three-dimensional structure with finger-like projections. He also noted the absence of anastomoses between villi.

*The Maternal Placental Circulation*

The maternal aspect of the placental circulation was described by Spanner<sup>6</sup> in 1936. He showed, by injection and corrosion methods, that the placental bed consists of a network of arterial and venous sinusoids underlying the placenta, and demonstrated clearly how the spiral arterioles enter the decidual-placental space. They enter the space from the whole of the under surface of the placental site. He could not, however, with rare exceptions demonstrate any venous drainage from the central area of the placental site. According to his findings, the venous return was by way of the

\* Paper presented at the Eighth Interim Congress of the South African Society of Obstetricians and Gynaecologists (M.A.S.A.), Bloemfontein, 2-5 March 1959.

marginal sinus. Spanner showed clearly the existence of this sinus as the peripheral part of the intervillous space, bounded laterally by the chorio-decidual reflection, superiorly by the chorionic plate and inferiorly by the peripheral part of the decidua basalis. He furthermore demonstrated the existence of venous sphincters in the foetal placental vessels both on the surface and in the substance of the placenta.

Ramsey,<sup>7</sup> in 1954, demonstrated that in monkeys the venous drainage of the intervillous space does take place through the central part of the placental site as well as through the peripheral or marginal-sinus area. This was demonstrated by injecting Indian ink into the uterine veins. The problem then arose how adequately to explain why blood should enter the intervillous space through the spiral arterioles and bathe the cotyledons and should not be returned immediately *via* the adjacent venous exits. Many theories were formulated. The solution came from the Carnegie Institute in Washington,<sup>8</sup> where morphological studies have led to the conclusion that the circulation in the placenta of primates is effected by a *vis a tergo* of the maternal blood pressure. This conclusion is based on the proposition that a sharp fall in blood pressure takes place between the uterine arteries and the intervillous space, and an additional fall in pressure between the intervillous space and the uterine veins. It is further assumed that the Braxton Hicks contractions during pregnancy further enhance this pressure differential by intermittently compressing the uterine veins, thus producing a temporary rise of pressure in the intervillous space, with abruptly increased drainage from the intervillous space following relaxation of the myometrium. This hypothesis contradicts the traditional belief that the myometrial contractions 'squeeze' the placenta like a sponge, expressing its content of blood.

The studies of intra-uterine pressure carried out by Alvarez and Caldeyro<sup>9</sup> on human patients at Caesarean section confirm this hypothesis and supply actual values for some of the components of the system.

#### *Premature Separation of the Placenta*

In considering the mechanism involved in premature separation of the placenta it will be necessary to recall that the placenta normally separates through the spongy layer of the decidua. After the expulsion of the foetus the uterine contractions tear the placenta from the uterus through the large vascular spaces of the spongiosa.<sup>10</sup> The contracted uterus effectively prevents bleeding from this vascular layer by tamponading the arteries supplying the area. When the placenta separates prematurely this tamponading effect cannot take place and bleeding usually occurs.

*Placenta praevia.* In the partial types of placenta praevia the bleeding is always at the marginal area and would involve mainly the venous return from the marginal sinus, with a better prognosis for the foetus than is presented by separation of the central part of the placenta, such as occurs in concealed accidental haemorrhage involving mainly the arterial supply to the placenta. The bleeding of placenta praevia is in fact just as much due to a premature separation of the placenta as is that of abruptio placentae.

*Rupture of the marginal sinus.* Haemorrhage from rupture of the marginal sinus arises when the inferior or decidual border of the sinus ruptures and, according to the extent of medial spread, may involve a considerable portion of decidua in this detachment. Fortunately the haemorrhage is usually of a lesser degree, and thrombosis occurs which produces a

laminated clot in a distended area in the marginal sinus. The diagnosis of this condition depends on the finding of a macroscopic and microscopic thrombus in this sinus, which is continuous with the clot that usually adheres to the periphery of the placenta at the site of the rupture. These criteria must be satisfied in order to differentiate the condition from the rupture of the marginal area, which of necessity follows the normal separation of the placenta.

#### *Toxaemic States*

As premature separation of the placenta occurs so frequently in association with toxæmia of pregnancy, it will be necessary to correlate the pathological findings in these two conditions. Ever since 1914, when Young<sup>11</sup> drew attention to the occurrence of red infarcts in the placentae of eclamptic women, much interest has been taken in the vascular lesions of this organ. During the last 25 years Bartholomew<sup>12</sup> and his co-workers have repeatedly emphasized the importance of these infarcts as the characteristic lesions in eclampsia and pre-eclamptic toxæmia. These workers originally attributed their formation to obstruction of the placental vessels owing to excessive and injurious foetal movement. Later, in 1936, Bartholomew and Kracke<sup>13</sup> suggested that the hypercholesteræmia of pregnancy, associated with a subclinical maternal hypothyroid state, might account for the degenerative vascular placental changes that result in infarction, of which they recognize 8 macroscopic varieties, 5 of which are described as so-called toxic infarcts. Their latest theory is that spasm of the muscular sphincters of the placental vessels, as originally described by Spanner, leads to the placental infarcts, which they hold are responsible for toxæmia of pregnancy.<sup>12</sup>

Bartholomew emphasizes that failure to appreciate the consistency with which acute infarcts may be observed in the placentae of patients affected by acute toxæmia is due mainly to the examination of the placenta in the fresh state. He points out that specimens should be placed in 10% formal saline immediately and allowed to become fixed for 1-2 months.<sup>12</sup> He further believes that the extent and location, as well as the degree, of obstruction of the placental vessels, and the rapidity of autolysis, will determine whether the condition will be one of mild, moderate or severe pre-eclampsia or whether accidental haemorrhage will occur. It is, however, as well to remember that the so-called placental infarcts occur in 60% of placentae in normal cases. Other workers, such as Nesbitt,<sup>14</sup> failed to demonstrate an exact correlation between the pathological lesions and the clinical manifestations of toxæmia. Nesbitt simplifies the understanding of placental infarction by pointing out that the whole question depends upon the maternal nutrition to the villi and the aetiological factor of syncytial degeneration, the latter primarily consisting of premature aging of the placenta. A large laminated clot may form beneath the decidual plate and thus become not only an area of intervillous thrombosis but also one of premature separation. Such an area of placental separation may interrupt the maternal circulation, either arterial or venous, and lead to infarction or ischaemic necrosis of the placenta.

Javert and Reiss,<sup>15</sup> in 1952, attempted to differentiate between red infarcts and decidual haemorrhages, explaining the intervillous thrombosis on the basis of an escape of foetal blood through the damaged endothelial lining, and the

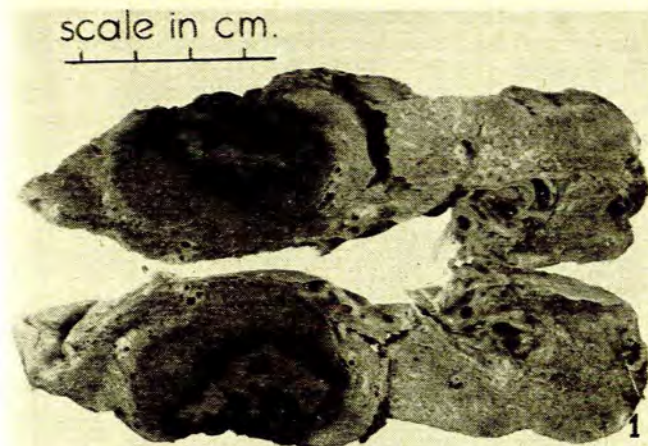


Fig. 1. See text.

absence of such thrombosis in premature separation of the placenta.

It is interesting to note that as far back as 1915 Williams<sup>16</sup> described degenerative lesions in the intima of the uterine arterioles in association with toxæmia. In 1950 Zeek and Assali<sup>17</sup> reported vascular changes in the decidua associated with eclamptogenic toxæmia, believing that these obstructive changes were due to acute atherosclerosis of the spiral arterioles and venous lakes.

In 1953 Hertig<sup>18</sup> stated that the pathological changes in accidental haemorrhage were decidual necrosis or degenera-

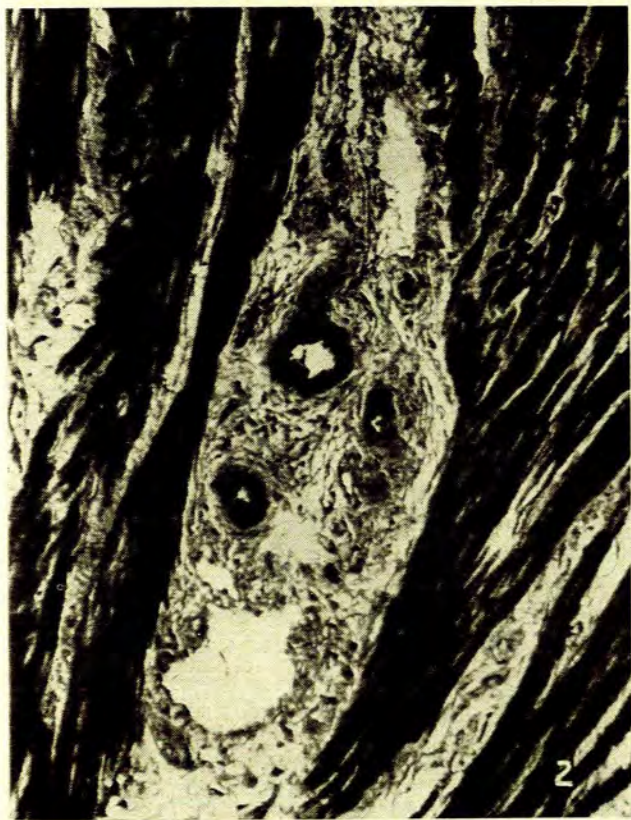

Fig. 2. See text.

tion, explained on a vascular basis in toxæmia and on a fortuitous basis when hypertension was not involved. Hertig demonstrated morphological evidence of acute atheromatous changes in the decidual arterioles, with macrophages and fibrinoid degeneration of the intima, resulting in encroachment on the lumen. These lesions were also demonstrable in essential hypertension and chronic nephritis.

Owing to the manifold difficulties in obtaining suitable material for study, Dixon and Robertson,<sup>19</sup> of Jamaica,

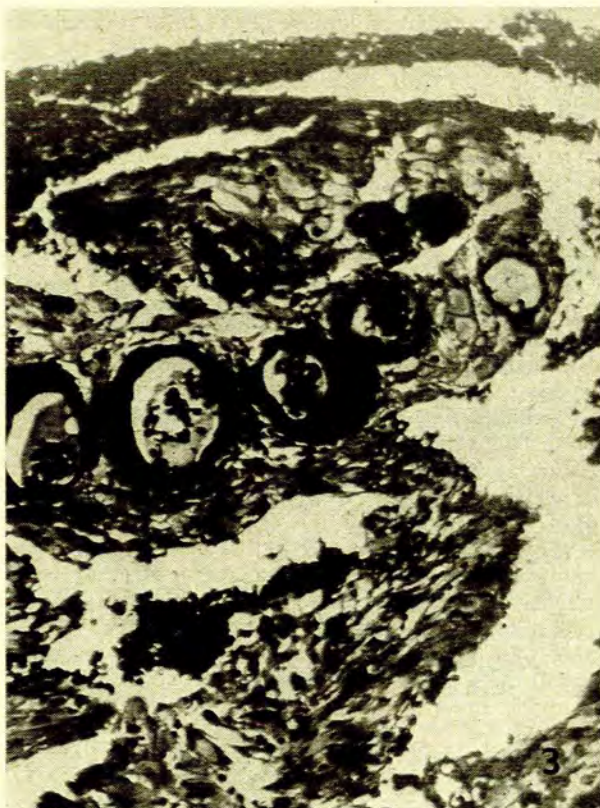

Fig. 3. See text.

have developed an ingenious method for obtaining material suitable for histological investigation of the vessels of the placental bed. To obtain representative specimens of decidual and underlying myometrial vessels they use a cervical punch-biopsy forceps, thrust through the placenta before separation at Caesarean section. With this technique they found vascular changes in the decidual and myometrial vessels from hypertensive and toxæmic patients similar to those generally acknowledged to occur in systemic hypertension. These changes were directly related to the clinical severity of the disease. Few such changes could be demonstrated in normal patients.

By using the above method of obtaining specimens we have started a study on similar lines, and Fig. 1 shows a placenta from a 19-year-old primiparous Coloured patient who was admitted as an emergency case suffering from fulminating toxæmia at 30 weeks. A Caesarean section was performed within an hour of admission but the foetus was dead and a retroplacental clot was found underlying the infarcted area of the placenta. Fig. 2 shows myometrial

arcuate vessels with microscopic changes generally associated with the changes that occur in the kidneys and suprarenal glands in systemic hypertension. Fig. 3 shows the arteriolar changes in the decidua of this case. The significance of these vascular changes is at present not clear. It is thought that the myometrial vascular changes may be found in normal multiparous uteri, possibly resulting from the enormous shrinkage which must of necessity take place after parturition. A study is in progress to determine the consistency with which such changes may be found in normal uteri.

The above anatomical findings lead one to postulate that, if they are significant, and if it is accepted that the foetal chorion is completely dependent upon its maternal blood supply, the changes in the delivered placentae in premature separation of the placenta and toxæmia of pregnancy must then be due to alterations on the maternal side of the placenta.

Clinical evidence of the reduced blood-flow in the intervillous space in eclampsia and essential hypertension was produced by Browne and Veall<sup>20</sup> in 1953 and by Morris Osborn and Wright<sup>21</sup> in 1955.

The problem whether the reduction in utero-placental blood-flow is the cause of hypertension or its effect is as yet unsolved.

The findings by Dixon and Robertson<sup>19</sup> that the spiral arterioles in a normotensive patient with renal impairment show medial degeneration and intimal proliferation, if valid, indicate that hypertension may not be the prime factor in decidual degeneration.

In conclusion I should like to mention a suggestion made by Prof. J. T. Louw that, as far as can be ascertained, toxæmia of pregnancy has not been recorded as a complicating factor in chorio-epithelioma, in which condition, as we know, the trophoblastic elements predominate. The absence of decidua in this condition provokes the thought that changes in the decidua may one day provide a clue towards the solution of the riddle of the toxæmia of pregnancy.

#### SUMMARY

1. Certain concepts regarding the anatomy of the placental circulation are discussed.

2. Pathological lesions are demonstrated in the decidua from a case of fulminating toxæmia of pregnancy complicated by accidental haemorrhage.

3. The possible aetiological role of these lesions in the causation of placental infarction and accidental haemorrhage is mentioned.

4. The absence of decidua in chorion epithelioma is mentioned as a clue in the aetiology of toxæmia of pregnancy.

#### SAMEVATTING

Sommige van die huidige opvattinge aangaande die anatomie en patologie van voortydige loslating van die plasenta word genoem met verwysing na die embriologiese ontwikkeling van die plasentale bloedsirkulasie.

As aanvaar word dat die plasenta geheel en al afhanklik is van die moederlike bloedstroom vir voeding, kan afgelei word dat infarske in voortydige loslating van die plasenta waarskynlik veroorsaak word deur vertraging van die intervilleuse sirkulasie, as gevolg van ateroomagtige veranderinge in die desiduale arteriole.

Die afwesigheid van desidua by gevalle van chorio-epitheliom stimuleer die gedagte dat degenerasie van die desidua 'n belangrike rol mag speel by die etiologie van toksemie van swangerskap.

I wish to express my thanks to Prof. James T. Louw for his encouragement. Special thanks are due to Mr. N. D. Constantine, of the Department of Obstetrics and Gynaecology, for his kind cooperation and assistance in preparing the histological sections and for the microphotography.

#### REFERENCES

- Hertig, A. T., Rock, J. and Adams, E. C. (1956): *Amer. J. Anat.*, **98**, 444.
- Hertig, A. T. and Rock, J. (1949): *Contr. Embryol. Carneg. Instn.*, **33**, 182.
- Hertig, A. T., Rock, J. and Adams, E. C. (1956): *Amer. J. Anat.*, **98**, 447.
- Novak, E. (1953): *Gynecologic and Obstetric Pathology*, 3rd ed., p. 538. Philadelphia and London: W. B. Saunders Co.
- Crawford, J. M. (1956): *J. Obstet. Gynaec. Brit. Emp.*, **63**, 543.
- Spanner, R. (1956): *Amer. J. Obstet. Gynec.*, **71**, 350.
- Ramsey, E. (1954): *Contr. Embryol. Carneg. Instn.*, **35**, 215.
- Year Book, Carnegie Inst. Washington (1957): **56**, 341.
- Greenhill, J. P. ed. (1958): *1958-59 Year Book of Obstetrics and Gynecology*, p. 17. Chicago: Year Book Publishers Inc.
- Novak, E.: *Op. cit.*,<sup>4</sup> p. 555.
- Young, J. (1914): *J. Obstet. Gynaec. Brit. Emp.*, **26**, 1.
- Bartholomew, R. A. (1957): *Amer. J. Obstet. Gynec.*, **74**, 64.
- Bartholomew, R. A. and Kracke, R. R. (1936): *Ibid.*, **31**, 549.
- Nesbitt, R. E. L. (1958): *Clin. Obstet. Gynec.*, **1**, 353.
- Javert, C. T. and Reiss, C. (1952): *Surg. Gynec. Obstet.*, **94**, 257.
- Williams, J. W. (1915): *Ibid.*, **21**, 541.
- Zeek, P. M. and Assali, N. S. (1950): *Amer. J. Clin. Path.*, **20**, 1099.
- Hertig, A. T. (1953): New York Association for the Aid of Crippled Children, pp. 202-215.
- Dixon, H. G. and Robertson, W. B. (1958): *J. Obstet. Gynaec. Brit. Emp.*, **65**, 803.
- Browne, J. C. E. and Veall, N. (1953): *Ibid.*, **60**, 141.
- Morris, N., Osborn, S. B. and Wright, H. P. (1955): *Lancet*, **1**, 323.