

TUBO-UTERINE SPASM

BRYAN C. MURLESS, B.A., M.B., B.CH. (CANTAB.), F.R.C.S. (EDIN.), F.R.C.O.G.

Senior Obstetrician and Gynaecologist, King Edward VIII Hospital, Durban, and Lecturer to the Department of Obstetrics and Gynaecology, Natal University. Assistant Gynaecologist, Addington Hospital, Durban

It is well known that spasm of the Fallopian tubes occurs frequently during tests for tubal patency and may be mistaken for organic tubal occlusion. It is not so well known that spasm may also occur in the uterus at this time, severe enough to cause a filling defect in the cavity, outlined by hystero-gram, and a mistaken diagnosis of submucous uterine tumour. A useful lesson may be learnt from the case outlined in this short article.

CASE HISTORY

A woman, age 26, complained of primary sterility of 2½ years' duration. Menstruation began at the age of 13; cycle of 28 days lasting 4 days; some dysmenorrhoea with backache. Clinical examination revealed no abnormality. After routine investigation of husband and satisfactory post-coital test, tubal patency was investigated.

Tubal insufflation under pentothal anaesthesia. Insufflation was performed with the kymograph about 4 days after the end of the last period. Gas passed at the pressure of 70 mm. Hg and flowed through easily. It was noted, however, that variations in pressure caused by uterine contraction were greater than normal, possibly indicating increased uterine irritability (Fig. 1).

It was decided to follow insufflation with utero-salpingography. It is interesting to note in retrospect that, had this investigation

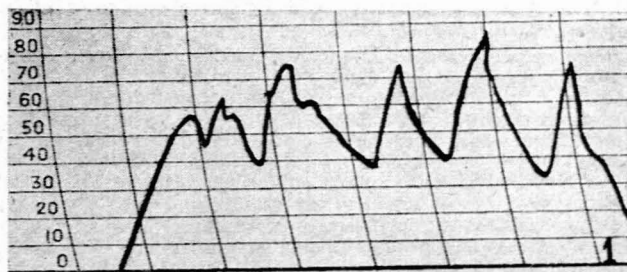

Fig. 1. Kymographic tracing showing gas passing at normal pressure but uterine contractions are rather excitable (pressure in mm. Hg).

been omitted, my patient would have been saved much inconvenience, anxiety and discomfort.

Utero-salpingography (Fig. 2). The canula was introduced easily without previous dilation of the cervix. Lipiodal was used as a contrast medium under screen control.

Radiologist's Report. A.P. and both obliques under screen control. A.P. view at 24 hours.

The uterine cavity is well filled and is considered to be normal in size. A well-defined filling defect is demonstrated posteriorly in the region of the right cornu. This defect is best demonstrated

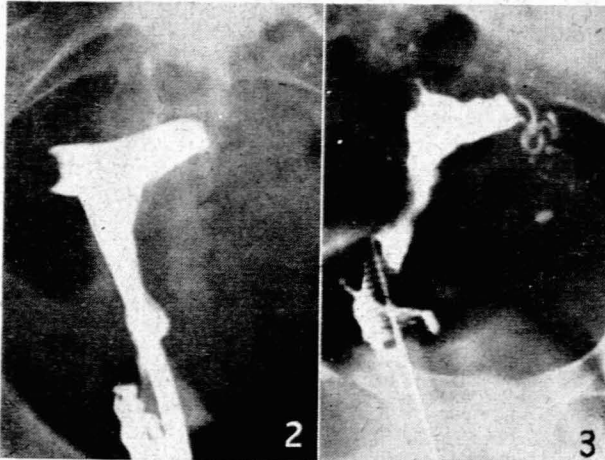


Fig. 2. Note filling defect at right cornu; both tubes apparently occluded.
Fig. 3. Note filling defect again present at right cornu. This time the left tube has filled completely.

on the oblique view with the right side raised. The appearance is highly suggestive of an endometrial polyp or submucous fibroid. The Fallopian tubes are not outlined, presumably owing to spasm.

Conclusions: A well-defined cut-out is demonstrated in the region of the right uterine cornu posteriorly, the appearance being suggestive of an endometrial polyp or submucous fibroid. The tubes have not filled, presumably the result of spasm, and there is no peritoneal smearing at 24 hours.

In view of this report it was decided to explore the uterus from below and this operation was performed 2 weeks later.

Operation under pentothal anaesthesia. Careful bimanual examination revealed a uterus normal in size and position. No irregularity could be distinguished in the right cornu. The cervix dilated easily and the uterus was explored with forceps and the curette. No polyp or irregularity of the cavity was found. Endometrial curettings appeared normal. Though somewhat surprised at finding the cavity empty, we felt that the radiological evidence before us could not be ignored. Moreover, it is common experience that a submucous fibroid may be difficult to 'feel' with the curette even when its presence is suspected.

We therefore decided that the clinical evidence was unreliable and a repeat uterogram was requested to confirm the previous findings. This time the patient was admitted to hospital and the screening was carried out by a different radiologist 2 weeks after the dilatation and curettage.

Utero-salpingography (Fig. 3) under Pentothal anaesthesia. The canula was introduced easily. Lipiodal was used as a contrast medium under screen control.

Radiologist's Report. Lipiodal was used and A.P. projections of the uterine region were made after the injection of 6 c.c., 8 c.c. and 10 c.c. of contrast media respectively. A lateral and 2 oblique exposures were then also made. The cervical canal and uterine cavity filled readily with contrast and after 6 c.c. were injected the left Fallopian tube filled up to or near its fimbrial end. At 8 c.c. a well-demarcated rounded filling defect is present in the right cornual region, and further filling of the left Fallopian tube is visualized with slight peritoneal spill at the fimbrial end. The lateral aspect of the left Fallopian tube appears somewhat dilated and a degree of hydrosalpinx is thought to be present. After 10 c.c. the filling defect mentioned above in the right cornual region can no longer be visualized on the A.P. projection. The lateral and oblique projections also confirm the presence of a filling defect in the right cornual region. This filling defect appears to be situated postero-laterally. At no stage was any filling of the right Fallopian tube present. The 24-hour film revealed slight peritoneal spill, which stays localized to the left and is thought to be outlining the ovary.

Conclusions: (1) A normal sized uterus tending to be bicornuate. (2) A filling defect in the postero-lateral aspect of the right cornu of the uterus, which is thought to be a submucous fibroid or a uterine polyp. The former diagnosis is favoured. (3) An obstructed right Fallopian tube at the right cornu of the

uterus. (4) A slight degree of hydrosalpinx in the fimbrial end of the left tube with possibility tube-ovarian adhesions, localizing the spill, as seen on the 24 hour film.

In view of these two radiological reports from different sources, the evidence of submucous tumour seemed irrefutable. Exploratory laparotomy seemed the only answer and was undertaken with some reluctance.

Laparotomy. The abdomen was opened by a low mid-line incision. Uterus, tubes and ovaries appeared quite normal. There were no adhesions. The uterus was palpated between thumb and fingers, but no fibroid could be detected. After this manipulation, the uterus appeared to contract, and scattered white areas were observed on its surface, similar to those seen after pituitrin is injected. The ovario-pelvic ligaments were clamped with rubber-covered forceps and Bonney's myomectomy clamp applied. The uterus was opened down the mid-line anteriorly and the cavity explored. No tumour, muscle thickening or congenital defect could be observed in the cavity. A fine probe was passed down the right tube, which appeared to be patent. The uterus was sutured with No. 1 chromic catgut interrupted sutures, and the suture line covered by bringing up the utero-vesical peritoneum. The abdomen was then closed.

DISCUSSION

When Stalworthy¹ referred to the female genital tract as the most hysterical portion of a woman's anatomy, it was well named, for it does indeed produce a diversity of functional abnormalities. In the case described, a diagnosis of right-sided tubo-uterine spasm was made after exploratory laparotomy. Before operation it was difficult to believe that a functional upset could account for the radiological findings.

Tubo-uterine spasm has long been recognized as a contributory cause of infertility. Sharman² has shown that this condition is common in patients attending infertility clinics. In his series, 26% showed apparent non-patency at a single insufflation test, and in 68.4% of these the non-patency was shown later to be due to cornual or tubal spasm. In a control series of insufflations on young unmarried women, spasm occurred in 1.69% only.

Most gynaecologists with experience of tubal patency tests will be able to confirm these findings, and I am convinced that uterine irritability is the commonest cause of tubal occlusion and delay in conception. Our knowledge of the mechanism of tubo-uterine function is incomplete. There is still doubt whether the oscillations shown on the kymograph at tubal insufflation are due to contractions of uterus or of the tube. I believe that any pressure changes demonstrated by this instrument are due to contractions of the uterus, and the work of Reynolds³ has shown that a slight increase of tension within the uterus will initiate contraction. Without doubt the tube is capable of contraction and probably reacts in unison with the uterus, the contraction wave flowing from isthmus to ampulla when the uterus is stimulated. Normally, peristaltic waves probably run in the opposite direction and, as Stalworthy¹ has suggested, it is when these waves are not synchronized and meet the contrast media, that a picture of unilateral blockage distal to the cornu is obtained.

Very little has been written of the part played by uterine spasm in infertility, although it is accepted that the functional blockage most often occurs in the region of the uterine cornu. That instrumentation sometimes induces uterine spasm is undoubted. According to Williams,⁴ painful contractions or spasm of the uterus may follow manipulations and may induce spasmodic tubal obstruction.

Inter-uterine tumours and polypi may cause uterine irritability, or may precipitate a spasm where the uterus is

already abnormally irritable. Cope⁵ describes 3 cases of dyspareunia due to uterine spasm, in 2 of which small inter-uterine tumours were present. Uterine spasm may be a commoner cause of dyspareunia than is generally realized, and it is possible that comparatively mild degrees of spasm may prevent conception. The degree of irritability, however, must vary from one individual to another as it does with involuntary muscle spasm in other sites, e.g. colon, ureter, pylorus, cardia etc.

Cases of extreme irritability with spasm sufficient to produce a filling defect on hystero-graphy are not common, but are familiar to every radiologist.

The interesting feature of the case reported is that extreme spasm occurred on two separate occasions in the same position in the right half of the uterus. It should also be noted that the left tube was occluded by spasm in the first examination, but was fully outlined in the second, showing that the spasm on this occasion was completely confined to the right side. Since each side of the genital tract develops from a separate muscular tube, it would seem fair to assume that the irritable condition may affect one side only. Furthermore, it is not uncommon to find apparent occlusion of a tube on one side only, which is later proved to be due to spasm.

In the pregnant uterus, Louw⁶ has pointed out that the constriction 'rings' or bands may affect one half of the uterus only, and such a condition may well go hand in hand with unilateral hyper-irritability of the non-pregnant uterus.

Also the structural changes noted by Palmer⁷ in the muscle of the fundus at Caesarean section, which consisted of localized areas of thinned-out muscle, might well result from physiological variations in uterine action in a uterus abnormally irritable before conception. It is interesting to note that nearly all Palmer's cases were associated with some degree of 'incoordinate' uterine action in labour.

Treatment

It seems that the cause of this uterine irritability is either an inherent defect in function of the automatic nervous system, or the result of mental conflict.

For the relief of spasm during tubal patency tests it is doubtful if any drugs are really effective. Anaesthesia and atropine are of no value. Pethidine and amyl nitrite may help in some cases. Nitroglycerine, 1/120th gr. taken as a tablet by mouth 5 minutes before the investigation, is probably the most useful drug, but in some cases is quite ineffectual.

The possibility of benefit from the tranquillizing drugs is fascinating to contemplate and might well be worth a trial. The frequency of conception following adoption and medical reassurance, which dispels mental anxiety, is well known. There is little doubt that in such cases infertility is due to tubo-uterine spasm and a course of tranquilizing drugs given over the first half of the menstrual cycle might well be effective treatment.

SUMMARY

1. A case of tubo-uterine spasm affecting mainly one side of the genital tract and giving rise to a radiological filling defect is described.
2. The difficulties of distinguishing the condition in diagnosis from an organic lesion are noted.
3. The causes of extreme spasm, its effect on fertility, and the peculiarities of unilateral spasm are discussed.
4. Suggestions for treatment are made.

REFERENCES

1. Stalworthy, J. (1948): *J. Obstet. Gynaec. Brit. Emp.*, **55**, 171.
2. Sharman, A. (1947): *Brit. Med. J.*, **2**, 83.
3. Reynolds, S. R. M. (1939): *Physiology of the Uterus*. New York: Harper.
4. Williams, W. W. (1953): *Sterility*. Springfield, Mass.: Williams, W. W.
5. Cope, E. (1950): *Proc. Roy. Soc. Med.*, **43**, 442.
6. Louw, J. T. (1957): *S. Afr. Med. J.*, **31**, 958.
7. Palmer, A. C. (1951): *Proc. Roy. Soc. Med.*, **44**, 867.