

OESOPHAGOPLASTY BY MODIFIED MES METHOD

CASE REPORT

P. C. W. MADDEN, CH.M.

Professorial Unit, Groote Schuur Hospital, Cape Town

Mrs. A.D., a European aged 21, was admitted to Groote Schuur Hospital on 18 February 1955 complaining of dysphagia. She had swallowed caustic soda—a teaspoonful in half a cup of water—on 8 November 1954. Two weeks later she began having difficulty with swallowing, and this had been progressive.

On admission she was able to swallow fluids but not solids. Examination showed her to be in good general condition, though she had lost a little weight. A barium

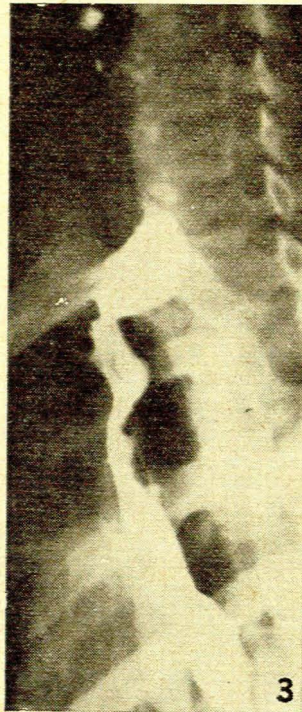
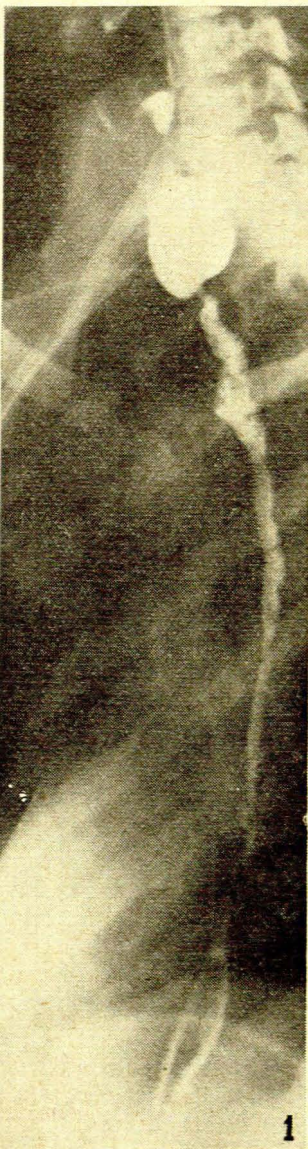swallow showed a long severe stricture of the oesophagus beginning at the upper thoracic inlet and extending to the diaphragm. She was then transferred to the Ear, Nose and Throat wards.

From 24 February to 29 June dilatations of the oesophagus were performed, with varying success. On at least two occasions she showed evidence of mediastinitis, which was controlled with antibiotics. It was agreed that dilatation offered no chance of permanent cure and it was decided to proceed with the Mes manoeuvre.

On 29 June the abdomen was opened through a left paramedian incision and the greater curvature of the stomach freed from the greater omentum in the manner described by Mes, with careful preservation of the gastro-epiploic artery. The stomach was then buttonholed through both surfaces about $1\frac{1}{2}$ inches proximal to the pylorus, and a pair of long clamps applied parallel to the greater curvature and about 2 inches from it. The stomach was then divided between the clamps, leaving the smaller inferior part attached at the pyloric end. The open surface of the stomach was then closed in two layers, while the lower portion was stretched to its fullest extent and converted into a tube with interrupted linen thread sutures in two layers. The stomach now presented the appearance of a Y and great care was taken not to narrow the lumen at the junction of the limbs of the Y.

Before the abdomen was closed, the (left) thorax was opened in the 5th interspace and the tube of stomach introduced into the thorax through a small opening in the diaphragm alongside the oesophageal hiatus. A jejunostomy tube was placed in the upper jejunum and the abdomen closed. The tube of stomach was tacked to the posterior mediastinal pleura with a few sutures. A 3-inch incision was then made in the neck, along the anterior border of the left sternomastoid from the jugular notch upwards, and by blunt dissection a passage was made between thorax and neck, anterior to the great vessels, and the tube of stomach was brought out in the neck and tacked to the skin. The thorax was then closed, with under-water drainage.

The patient tolerated the operation very well and was maintained by jejunostomy feeds. On 3 July the wound in the neck was reopened and the tube of stomach mobilized from its bed. The inferior thyroid artery was identified and ligated and the thyroid gland mobilized towards the mid-line to permit easier identification and mobilization of the oesophagus. The latter was mobilized with some difficulty, probably ascribable to previous peri-oesophagitis due to the caustic soda. When the oesophagus was opened in the root of the neck the wall was found to be densely



Left: *Fig. 1.* Shows the extent of this formidable stricture considered radiologically to begin at D4. In fact the stricture began about 2 inches higher, and extended to the diaphragm.

Right: *Fig. 3.* Barium passing through the site of anastomosis in the neck one month after the anastomosis had been made.

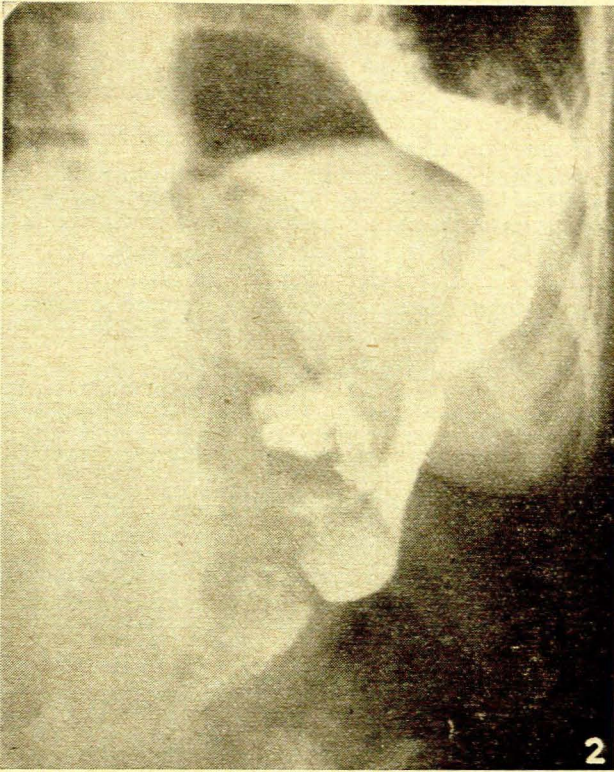


Fig. 2. Thick barium had been poured down the tube and the patient had swallowed a small quantity of thin barium. The picture shows the meeting of these two streams at the Y in the stomach—before the anastomosis in the neck had been completed.

scarred and the stricture to commence considerably above the level indicated by the X-ray—in fact tissue approaching normal was found only at the level of the thyroid cartilage; the base of the tongue was easily palpable through this opening. A satisfactory anastomosis was contrived at this level with two rows of interrupted thread sutures. There was no tension on the anastomosis. The distal oesophagus was ligated with strong chromic catgut, the mucous membrane above the ligature thoroughly destroyed with the caustery, and the stump pushed back into the mediastinum. The wound was closed and a glove drain left.

This operation was tolerated very well. After 72 hours the patient was allowed to swallow fluids. On the 5th day a fistula developed. This had closed spontaneously 6 days later and the patient was taking liquids with ease. On 27 July the jejunostomy tube was removed and semi-solids permitted—and taken well. At the end of a month she was on normal diet.

The patient returned on 30 September complaining once more of difficulty in swallowing and was found to have a soft stricture at the anastomosis. This was very easily dilated to the maximum dilator size.

The patient has a certain amount of regurgitation if she lies prone directly after a meal. This is a disadvantage and it is too early as yet to know whether there will later be trouble with stricture formation.

COMMENT

This case is described in an endeavour to draw attention to the technique evolved by Mes. He demonstrated several very successful cases at the 1948 South African Medical Congress in Pretoria, when the late T. Lindsay

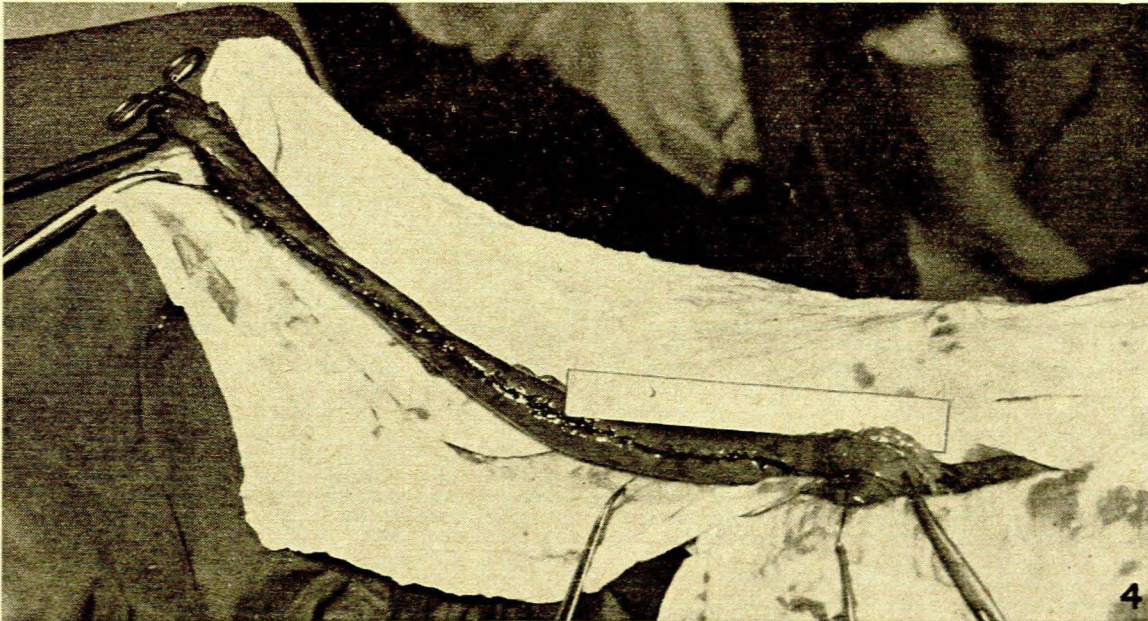


Fig. 4. Shows the length of the constructed tube. The lowest forceps points to the pylorus. The second is at the Y in the stomach. The metal strip, which has been outlined for the sake of clarity, is 9 inches in length.

Sandes described the method as a significant and well-thought-out step in the treatment of these difficult cases.

The technique used in this case differs slightly from that of Mes in that the tube was brought through the thorax and not ante-thoracically. Mes also used an ingenious staged method for making the gastro-oesophageal closure in the neck. The use of the antibiotics now available renders this unnecessary. The striking advantage in his method is the ease with which a very long tube with excellent blood supply is available to bridge the gap between the diaphragm and the neck. In the case here described the tube reached easily beyond the level of the zygoma and could have been made even longer by using Mes' manoeuvre of taking in the greater curve round the cardia as well. Moreover there was definite arterial bleeding at the very end of the tube and its colour was excellent throughout its length.

Since the first case was operated upon by the Mes method, Prof. J. H. Louw has used the method on several children with a combined abdomino-thoracic incision which has proved a great improvement. In

addition a duodenal tube has been introduced down the new 'tube of stomach' with its tip beyond the pylorus and the patient fed *via* this tube. This replaces the jejunostomy used in the first case, and is obviously better from every point of view.

The method has distinct advantages over the standard oesophago-gastric anastomosis. It obviates the discomfort after meals caused by the distension of the intra-thoracic stomach. The incidence of oesophagitis caused by acid regurgitation should theoretically be much less also, for the tube can be assumed to be largely 'vagotomized'. The method should be applicable in malignant disease of the oesophagus both as a palliative and as a curative procedure.

My thanks are due to Dr. F. D. du T. Van Zyl who placed this case in my care and to Mr. B. T. Todt who was responsible for the photographs.

REFERENCE

Mes, G. M. (1948): *J. Int. Coll. Surg.*, **2**, 270.

POSTSCRIPT

17 August 1956. The patient writes to say she has no difficulty whatsoever in swallowing.