

CLINICAL PATTERNS IN INTESTINAL STRANGULATION

JOHN HAMMAN, F.R.C.S. (EDIN.), *Vanderbijlpark Hospital*

Although it is a fact that during the last decade fatality rates of only single figures have been published for certain forms of acute intestinal obstruction, the full mortality rate is still in the region of 10-15%, while that of established strangulation has been varying reported in the region of 20% or more.^{2-7, 9, 11, 13, 14} In this country Kok,⁸ in his recent report on deaths occurring during or shortly after anaesthesia, comments on the incidence of such cases operated on for acute bowel obstructions.

My observations are based on a series of 114 strangulating bowel occlusions, of which 78% showed some degree of vascular insufficiency while 26% were gangrenous. The mortality rate was 15% while that for intra-abdominal strangulation was 20%. In 10 cases operation was not undertaken.

The time element is important. The fatality rate was *nil* for patients dealt with during the first 24 hours and low for cases operated on during the first 48 hours, but thereafter the mortality rose steeply and was 50% and more for cases operated on the fourth day or later. Although the greatest incidence of gangrene was noted amongst the fourth-day group, 8.6% of cases seen during the first 24 hours had infarcted loops, while 22% of the first 48-hour group were affected in a similar way.

Although it has been stated that shock in strangulation is seldom if ever irreversible, if adequate supportive measures are instituted, it is my impression that a 'point of no return' has frequently been reached by the time some of these cases are seen by a surgeon. The recognition of such lesions at as early a stage as possible becomes then a matter of some importance.

CLASSIFICATION AND CLINICAL FEATURES

I have classified my cases, irrespective of the aetiological factors, into the following groups:

1. *Internal loops*, where the affected loop lies in a free peritoneal cavity.

2. *Excluded loops*, where the affected loop, while being intra-abdominal, is excluded from the general peritoneal cavity, as in most cases of intussusception or where a strangulated loop is sealed off by omentum.

3. *External loops*, where the loop is extra-abdominal, as in external herniae.

Table I shows the justification for this classification in terms of the prognosis and major clinical features. There

were no diagnostic errors regarding the external group, and very few of the excluded group (intussusceptions) gave rise to difficulty in diagnosis.⁷ Amongst the internal group, however, such errors were common and at times led to delay in treatment or to inadequate or precipitate treatment. More than 40% of patients who presented at operation with gangrenous loops had been incorrectly diagnosed in the first instance. Thus, in relation to the clinical patterns, my remarks are more or less confined to cases with internal loops; 52 such cases are reviewed here.

The signs and symptoms of intestinal strangulation fall into 3 groups, viz. (1) those related to the degree of luminal occlusion, (2) those pertaining to the degree of vascular insufficiency and (3) those resulting from a closed loop, which is a feature of most cases.

LUMINAL OCCLUSION

The classical signs and symptoms of cases in this group are colic, vomiting, distension and constipation (Table II).

TABLE II. SIGNS AND SYMPTOMS IN RELATION TO LUMINAL OCCLUSION

| | Internal | | Excluded | External |
|--------------------|----------|------------|----------|----------|
| | Viable | Gangrenous | | |
| Colic | 71% | 35% | 80% | 60% |
| Vomiting | 71% | 61% | 80% | 30% |
| Distension | 57% | 44% | 30% | 30% |
| Constipation | 54% | 35% | 40% | 40% |

1. Colic

While it may be true to say that colic is a feature of most cases of intestinal occlusion, the recognition of this symptom is a somewhat different matter. Typical colic, while being a marked feature of intussusception, where it was noted in 80% of cases, was observed or recorded in the history of only 71% of cases, presenting with internal loops, and in only 35% of cases with gangrenous loops.

This fact contributed towards diagnostic error, and reasons for this are as follows:

(a) Once luminal occlusion is fully established, irreversible colic passes off and ileus supervenes. Most of my cases showed some degree of torsion, and under such conditions complete luminal occlusion may eventuate within a relatively brief period. Moreover, the internal group tended to present much later than the others, thus allowing time for luminal occlusion to become complete. Consequently, by the time many of these patients were seen, colic was no longer a feature. Amongst the intussusceptions, on the other hand, the lesion tends to be progressive during the first 48 hours and the apex of the inverted loop often acts as a foreign body; typical colic thus becomes a more apparent feature.

(b) The fact that colic was noted in only 35% of cases

TABLE I. PROGNOSIS IN TERMS OF PERITONEAL RELATIONSHIPS

| | Internal | Excluded | External |
|------------------------------|----------|----------|----------|
| Mortality | 28% | 12% | 5% |
| Vascular insufficiency | 86% | 82% | 69% |
| Gangrene | 45% | 6% | 13% |
| Shock | 35% | 11% | 9% |

with internal loops which were gangrenous, does not imply that colic was at no time present in the other cases. Often enough in such cases the more acute, generalized and unremitting pain of a strangulation so dominates the patient's mind that his earlier crampy pain is overlooked. At the same time, where such patients presented as acute emergencies, it is apparent that those who first saw them accepted the obvious picture of an abdominal crisis requiring laparotomy without delving sufficiently deeply into the patient's history in every case.

(c) Where the upper level of occlusion is high in the small intestine, colic may not be a feature of an occlusive lesion.

(d) Colic is not necessarily a mid-line pain.¹⁰

2. Vomiting

Much attention has been paid to vomiting as a symptom, and there is a tendency to expect repeated vomiting, which is often a late feature of acute bowel occlusion.

In 80% of the inversions, and in 60-70% of cases with internal loops, vomiting occurred. It was, however, an initial symptom only in the majority, repeated vomiting being seen mainly in late cases. Constant retching, which has been described as characteristic in cases of established strangulation, was uncommon. Blood in the vomitus, or an actual haematemesis, was noted in a few instances where an infarcted loop presented.

Far more important than vomiting is anorexia and nausea. A high degree of gastric retention may be present without any vomiting. It is my practice to pass a gastric tube and estimate the degree of retention as a diagnostic measure. One has frequently heard housemen say to a patient: 'Have you been vomiting?' and the patient, who may have vomited once and who suffers from intense nausea, promptly says: 'No'.

The absence of vomiting at times is hard to explain. One of my cases was an adult female who had a triple torsion of the midgut and who was seen only on the third day of her illness. She had vomited only once, did not admit to colic at any time, was not distended, and said that she had passed flatus after the onset of her abdominal pain. She presented with acute pain, shock, peritoneal irritation and signs of internal bleeding. A gynaecologist operated on her for a bleeding tubal pregnancy—only to find himself confronted with 18 feet of infarcted gut.

3. Distension

Although Aird¹ and Wangenstein¹⁵ have stressed the inconstant relationship between strangulation and distension, there is a tendency to expect gross and obvious distension where an occlusive process is concerned. Distension was not a prominent feature in my cases except where colonic closed loops and late cases were concerned. At the same time a localized loop distension may be more real than apparent and should be carefully looked for by rectal, vaginal, and bimanual examination. Only 30% of inversions showed abdominal distension and these were on the whole late cases. Of the cases with internal loops only 50% presented with distension as a feature and only 44% of cases with gangrenous loops showed this sign.

Most strangulating loops are of medium length and are easily accommodated in the pelvis without visible distension of the abdominal wall, while in cases of infarction the blood-

sodden loop is incapable of becoming distended to any degree.

4. Constipation

Constipation is the least reliable feature of an occlusive lesion. A motion and flatus may be passed subsequent to the onset of a strangulating lesion and within a few hours of infarction. Again, the presence or absence of absolute constipation has frequently been accepted or rejected on subjective grounds alone, and the presence of such a symptom may be more real than apparent. In less than 50% of cases of inversion and of gut torsion in this series, was constipation a prominent symptom.

I seldom use the 2-enema test because it is disturbing to the patient, and because staff simply will not remain at the bedside to determine exactly what happens after the administration of an enema, and lastly because X-ray examination probably provides more adequate information.

The real or apparent absence of the classical evidence of an acute bowel occlusion was a not uncommon source of misdiagnosis by those who first saw my cases. Where loops were viable 2 of the 4 classical signs were present in 70% of cases and the remaining 2 in over 50%. But where loops were non-viable only 1 of the classical signs was present in over 50% of cases and the others presented in less than half of the patients, or were only detected to this extent.

Case 1

A middle-aged woman presented with gastro-intestinal bleeding and abdominal pain but no vomiting and no distension, and she was apparently not constipated since faecal matter was at first mixed with the blood passed *per rectum*. Despite the fact that she complained of typical colic she was treated as a case of gastro-duodenal bleeding in a medical ward until the third day. At this stage an X-ray examination revealed a single small-bowel fluid level. At operation she had a non-viable small-bowel intussusception due to a polyp.

Case 2

A middle-aged man developed abdominal pain but no history of colic was obtained. Distension and vomiting became apparent only on the third day. Although he had absolute constipation from the start, the fact that he frequently went to the lavatory, in response to a rectal tenemus, was assumed to indicate the passage of motions. His doctors became alarmed only on the third evening, when signs of peritonitis became apparent. At operation he was found to have a gangrenous and perforated ileo-caecal volvulus.

VASCULAR INSUFFICIENCY

The signs and symptoms of vascular insufficiency are essentially: Shock, tachycardia, peritoneal irritation, pain, evidence of blood loss, and a tumour.

1. Shock

Much stress has been laid on shock as a clinical sign of strangulation. In this series shock was a prominent feature in cases with long loops (many of which were gangrenous) but was noted in only 14% of cases with medium loops and in only 11% of cases with short loops. Again, shock was prominent in internal-loop strangulation. It was not a clinical feature of inverted or external non-viable loops.

Where loops were of medium length and viable, shock was only present if sufficient time had lapsed to allow of severe distension of the proximal gut. Thus shock as a clinical sign is of little assistance in diagnosing the medium-length strangulating, but not yet infarcted, loop. Also, shock may not be apparent in cases of medium-loop infarction, but here

it should be stressed that shock as a pathological state, as distinct from a clinical symptom, may be far more real than apparent. Patients may present with none of the usual bedside criteria of shock and yet have a seriously reduced blood volume.

Two cases operated on by me, illustrate this observation. Both were African females whom I saw on the fourth day of illness after being originally diagnosed as a case of amoebic liver abscess and a case of tubo-ovarian abscess. In neither was a history of colic obtained, neither had vomited more than twice, neither was distended and neither had admitted to constipation. Both presented with evidence of peritoneal irritation and an abdominal tumour. Both had systolic blood pressures of over 110 mm. Hg and pulse rates of under 100. Neither appeared to be in the least shocked. Both, however, were given a pint of blood pre-operatively. At operation each presented with a medium-loop gangrene, there was no distension to any degree of proximal gut, neither loop had ruptured, but both cases had a pint or so of bloody exudation in the peritoneal cavity. After operations lasting little more than half an hour, both passed into a state of acute and irreversible peripheral vascular failure.

These patients were either given inadequate transfusions before surgery or they had already reached a 'point of no return'.

2. Tachycardia

A rapid pulse may be expected but is again not the rule even in the face of medium-loop gangrene. What is important, however, is a sudden and abrupt rise in the pulse rates of patients who are being treated conservatively for simple occlusion.

3. Peritoneal Irritation

Much stress¹⁵ has been laid on evidence of peritoneal irritation in diagnosing the strangulated as distinct from the simple occlusion. While it is a fact (Table III) that such

TABLE III. LOCAL SIGNS OF STRANGULATION

| | Internal | | Excluded | External |
|-----------------------|----------|------------|----------|----------|
| | Viable | Gangrenous | | |
| Peritoneal irritation | 64% | 83% | 30% | 15% |
| Tachycardia | 46% | 78% | 80% | 50% |
| Tumour | 29% | 35% | 80% | 100% |

signs as rebound pain, abdominal-wall tenderness, guarding or rigidity were prominent where a loop had become gangrenous (in over 80%), the crux of the problem is to diagnose the strangulating, but not yet fully strangulated loop.

In this series evidence of some degree of peritoneal irritation was noted in over 60% of cases. This is a point of some importance. It must be noted, however, that amongst cases with gangrenous loops such evidence was usually, although not always, prominent; amongst the viable group, on the other hand, such evidence had to be carefully looked for.

4. Pain

Abdominal pain, usually acute and unremitting, often generalized but frequently quadrantal, was the least variable and sometimes the only clinical sign. Space does not permit a full discussion of the causes of abdominal pain, but its importance must be stressed. It was commonly acute, but where a replacement gangrene occurred, and in patients already seriously ill from some concomitant disorder, pain was at times misleadingly mild. Patients treated conservatively

for simple occlusions should only be mildly sedated if at all. The following case illustrates the role of pain in this regard.

An adult male presented with the classical signs of simple bowel occlusion. This was confirmed on X-ray examination (Fig. 1) which showed a fluid level. The nature of this level, together with an inverted U loop, should have suggested a closed-loop obstruction. No comment, however, was made on this. After a period of gastro-intestinal suction the patient's symptoms

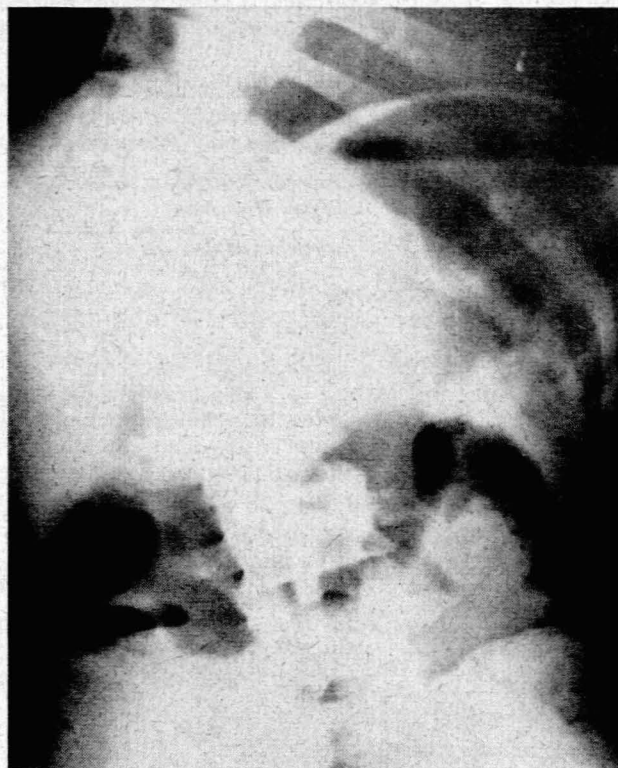


Fig. 1. A fluid level in a closed-loop occlusion.

settled down, distension was relieved, normal bowel sounds were heard and flatus was passed. A repeat X-ray examination at this stage showed no evidence of bowel occlusion, but the patient, who had been sedated previously, began to complain of a continuous pain in the R.I.F. He said that this pain was present from the beginning, but was now acute. At operation a plum-coloured loop presented as part of a small-bowel (adhesive) volvulus. Had he not been sedated return of the pain while on gastro-duodenal suction would have been apparent at an earlier stage.

5. Evidence of Blood Loss

Evidence of whole-blood loss were only of clinical significance where long-loop strangulations were fully established.

6. Tumour

A palpable tumour mass was noted in over 70% of cases with the inversions but was less often a feature of cases with free-lying internal loops; yet in 35% of cases with gangrenous loops and in 29% of cases with viable loops a mass was detected.

The presence of a mass in a patient who shows any evidence whatsoever of an occlusive process, is strongly indicative of strangulation.

The need for careful rectal and bimanual examination should be stressed once more.

CLOSED LOOP

The signs and symptoms related to a closed loop were as follows: (1) Failure to secure adequate relief of pain after a trial period of gastro-intestinal suction. (2) A disproportionate distension or a localized loop distension or a palpable tumour. (3) X-ray evidence of a closed loop or isolated loop or disproportionate loop distension.

1. Trial Suction

Table IV shows my results in a series of 30 cases where simple and strangulating lesions presented at a stage where a trial period of suction was indicated. Adequate suction

TABLE IV. RESPONSE TO GASTRO-DUODENAL SUCTION

| | Simple Occlusions | | Closed Loops |
|---------------------------|-------------------|----------------|--------------|
| | High | Middle and Low | |
| Complete relief of pain | 100% | 44% | Nil |
| Incomplete relief of pain | Nil | 44% | 33% |
| No relief | Nil | 11% | 67% |
| Return of original pain | Nil | 11% | 80% |

no doubt implies the passage of a long tube into the small bowel. This is, however, often both time-consuming and difficult and even a gastric tube is sometimes useful in this connection. Table IV also shows that suction is of diagnostic importance.

2 and 3. Other Signs of Loop Distension

Table V shows the extent to which other signs of closed-loop obstruction were present. It must, however, be stressed

TABLE V. SIGNS RELATING TO CLOSED LOOPS (INTERNAL LOOPS ONLY)

| | All Loops | Gangrenous Loops | Viable Loops |
|-----------------------------|-----------|------------------|--------------|
| | Tumour | 31% | 35% |
| Disproportionate distension | 28% | 26% | 41% |
| X-ray signs of closed loop | 40% | 50% | 36% |

that the X-ray findings apply to that proportion of cases only who underwent X-ray examination.

It should also be stressed that although the signs suggestive of closed-loop obstruction were not individually prominent, the *sum total* of such evidence indicated, or should have indicated, the presence of a closed loop in at least 70% of the cases reported in this series.

CONCLUSION

Space does not permit of a discussion of the distinctive radiological features or the differential diagnosis in these cases. The purpose of this paper is merely to present some of the patterns of strangulating bowel occlusions and to stress the fact that, since each individual symptom or sign is a variable factor, no constant or characteristic symptom pattern should be expected.

It should also be stressed that the term 'sub-acute obstruction' is a bad one except when applied to a stenosis of long standing. The mechanism of the vast majority of bowel occlusions is such that there is a constant threat to the blood supply of the affected loops, and vascular impairment may become complete within a very brief period.

In many of my cases where an incorrect diagnosis had been made this resulted largely from the fact that in the absence of *obvious* evidence of gut occlusion, the *possibility* of a strangulating lesion had not been thought of nor diligently looked for by the clinician who saw these patients in the first instance.

REFERENCES

- Aird, I. (1949): *Companion in Surgical Studies*. Edinburgh: Livingstone.
- Eliason, E. L. and Welty, R. F. (1947): *Ann. Surg.*, **125**, 1.
- Barling, E. V. (1956): *Aust. N.Z. J. Surgery*, **25**, 285.
- Bollinger, J. A. and Fowler, E. F. (1953): *Arch. Surg. (Chicago)*, **66**, 888.
- Drugas, F. G. and Schiff, C. A. (1954): *Ibid.*, **66**, 612.
- Evans, E. I. and Bigger, I. A. (1947): *J. Amer. Med. Assoc.*, **133**, 8.
- Hamman, J. (1952): *S. Afr. J. Clin. Sci.*, **133**, 8.
- Kok, O. V. S. (1958): *S. Afr. Med. J.*, **32**, 7.
- Maingot, R. (1955): *Abdominal Operations*, 3rd ed. London: Lewis.
- McKittrick, L. S. and Sarris, S. P. (1940): *New Engl. J. Med.*, **222**, 611.
- Mortez, W. H. and Morten, J. L. (1950): *Ann. Surg.*, **132**, 897.
- Moses, W. R. (1949): *Amer. J. Surg.*, **77**, 2.
- Nemir, P. *et al.* (1949): *Ann. Surg.*, **130**, 5.
- Thurston, D. L. *et al.* (1953): *Arch. Surg. (Chicago)*, **67**, 67.
- Wangensteen, O. H. (1945): *Intestinal Obstructions*, 2nd ed. Springfield, Ill.: C. Thomas.