

# ENVIRONMENTAL BONE DISEASE OF HITHERTO UNDESCRIBED TYPE

N. F. DODD, M.B., CH.B. (CAPE TOWN); D. W. LEVY, M.B., CH.B. (CAPE TOWN), M.R.C.P.; and W. P. U. JACKSON, M.D.

*Department of Medicine, Groote Schuur Hospital, Observatory, Cape and*

*M. L. TRAUT, M.B., CH.B. (CAPE TOWN), District Surgeon, Kenhardt, Cape*

This is a preliminary report of an unusual bone disorder which occurs in a small, localized community and is closely related to fluorosis. 400 Coloured children attend school in Kenhardt, a small town in the north-eastern Karoo in the Cape Province. Of these, 150 come from the 'Rooiblok location' situated  $\frac{1}{2}$  mile outside the village. Of the children from this location 30 have been observed to be bow-legged, yet none of those living elsewhere are affected at all.

The condition appears to start when the children are 3 - 5 years old. They complain initially of pain in the legs. The bone deformities become apparent between the ages of 5 and 6 years. These, in the main, consist of bowing of the femora and tibiae (Figs. 1 and 2). The oldest known affected person is 25 years of age, the majority being under 15 years. It is believed by those on the spot that the incidence of this condition is increasing. Many other children in this locality complain of limb pains without showing obvious bony deformity.

Although several cases occur in the same family, affected families are not interrelated. In fact the background and heritage of the families of this 'new' Rooiblok community, established only in 1941, is such as to make an hereditary basis most unlikely.

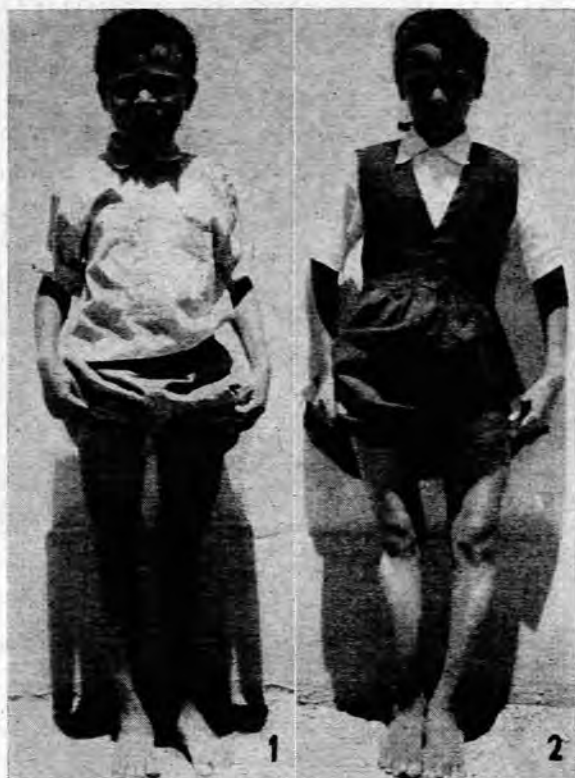The children are apparently normal in all other respects apart from the skeletal system. The parents show no obvious bony deformity, but many adults complain of back pain.

Rickets had earlier been suspected on clinical grounds. However, neither specific treatment nor prophylactic therapy have had any obvious effect. From the start the age of onset and curious localization of the condition rendered this diagnosis very unlikely.

In this report we wish to discuss the results of our investigations into the geography, nutritional background, and conditions of this region as well as 2 sample cases investigated in the Department of Medicine, Groote Schuur Hospital.

## THE GEOGRAPHY, ENVIRONMENT AND CONDITIONS OF THE REGION

Kenhardt lies in a hollow between hills. Fig. 3 is a diagram of the area under investigation, *not* drawn to scale. Aerial maps illustrate clearly the tendency for drainage to occur radially towards Kenhardt as a central point. There are, in Kenhardt, two Coloured communities—'Die Lokasie' and 'Rooiblok'. The European settlement lies between the two and is separated from Rooiblok by a river bed which is



Figs. 1 and 2. Examples of the clinical deformities found among Rooiblok children attending school in Kenhardt, i.e. bowing of femora and tibiae.

normally dry, but acts as an overflow for the dam (Fig. 3). The European community and 'Die Lokasie' obtain their water supply from several boreholes sunk through rock about 5 miles from the town and lying on the far side of the river bed. The Rooiblok location obtains its water

from ghorras—shallow wells sunk to a depth of 10 - 20 feet above the rock.

The river was dammed in 1900 but the wall was washed away soon afterwards. It was rebuilt of earth in 1930. The dam water is used solely for irrigation purposes for the area between the village and the dam.

The Rooiblok settlement has existed for at least 41 years and its water has always been obtained from ghorras. Until 1941, this settlement was a European one, but following a flood it was subsequently resettled by the present Coloured community.

The affected people come from one section of the whole Rooiblok area, that which is closest to the dry river bed which acts as an overflow (Rooiblok South, Fig. 3). One or 2 other cases have come from the area irrigated by the dam, not actually in Rooiblok itself. These people obtain their water supply from ghorras situated near the irrigation canal. The bony disorder occurs only in those children born in Rooiblok South, apart from 2 children (the de Bruin's) who moved into the Rooiblok area at an early age and developed the same condition after some 2 - 3 years.

The diets of the two Coloured communities are believed to be much the same—including meat, milk, and eggs, but with little in the way of green vegetables or fruit. It is certainly highly unlikely that the diets of Rooiblok North and Rooiblok South could differ appreciably from each other. Insecticides are not used on any produce grown. (Certain insecticides are said to cause a rise in the fluorine content of fruit.<sup>1</sup>)

CASES INVESTIGATED AT GROOTE SCHUUR HOSPITAL

Case 1

N.M., Coloured female, aged 13 years (Figs. 4 and 5). Bony deformity of legs noted since childhood. No other symptoms. Parents said to be normal. Two siblings have the same condition.

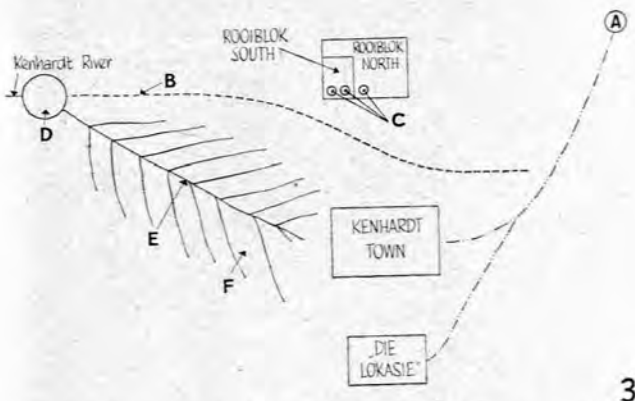
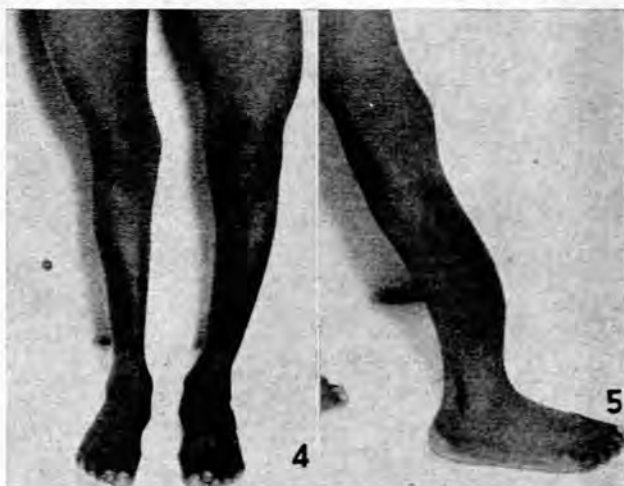

Fig. 3. Diagram of Kenhardt area showing the approximate relative situations of the 'dorp' and the locations:  
 A = Boreholes approximately 5 miles from Kenhardt which supply drinking water to the town and 'die lokasie'.  
 B = Dry river bed acting as an overflow from the dam.  
 C = 'Ghorras' from which Rooiblok's drinking water is obtained.  
 D = Dam built in 1930.  
 E = Irrigation canal.  
 F = Area irrigated by dam water.



Figs. 4 and 5. Case 1 showing clinical deformities.

General examination: Afebrile. Thin, rather short (height 4 ft. 3 3/4 inches). Hypertelorism. The tibiae are bowed anteriorly and the femora laterally. The ligaments are not lax; there are no joint deformities. There is no evidence of old rickets. Teeth show the brown staining of fluorosis with extreme degrees of pitting. There is gross caries at the gingival margins (Fig. 6).

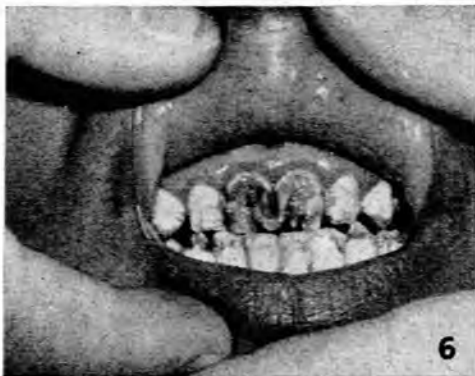

Fig. 6. Teeth changes in case 1 showing changes as described in text.

**Cardiovascular system:** Pulse 72/min., blood pressure 115/60 mm. Hg, N.A.D.

**Respiratory system:** N.A.D.

**Gastro-intestinal system:** Liver palpable, 1 finger-breadth below costal margin.

**Central nervous system:** N.A.D.

**Blood picture:** N.A.D.

**Urine:** N.A.D.

**Skeletal survey.** (See Figs. 7-9.) Bone age is compatible with chronological age. There is evidence of generalized coarsening of trabeculae with demineralization and thinning of cortices. In addition there are the following bone changes:

**Skull.** Thickening of outer table.

**Teeth.** Defective lamina dura of upper incisor teeth. Areas of erosion in some of the crowns. Central incisors taper in a peculiar fashion towards the apices.

**Vertebrae.** Bodies somewhat flattened and porotic, showing double transverse lines in each body.

**Femora.** Bowing laterally with thinning of the cortex and buttressing on the convex aspect.

**Other special investigations:** Serum proteins: albumin 4.3 g.%, and globulin 3.8 g.%, serum calcium 9.6 mg.%, serum inorganic phosphorus 5.1 g.%, serum alkaline phosphatase 8.2 units (Bodansky-Shinowara), blood urea 18 mg.%, urea and creatinine clearance within normal limits, and Sulkowitch test negative.

Permission for bone biopsies was refused.

#### Case 2

S.S., Coloured male, aged 15 years. (Figs. 10 and 11). Com-

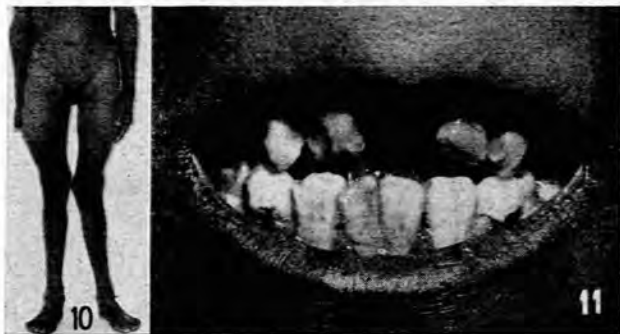

Fig. 10. Case 2 showing clinical deformities.  
Fig. 11. Teeth changes in case 2.

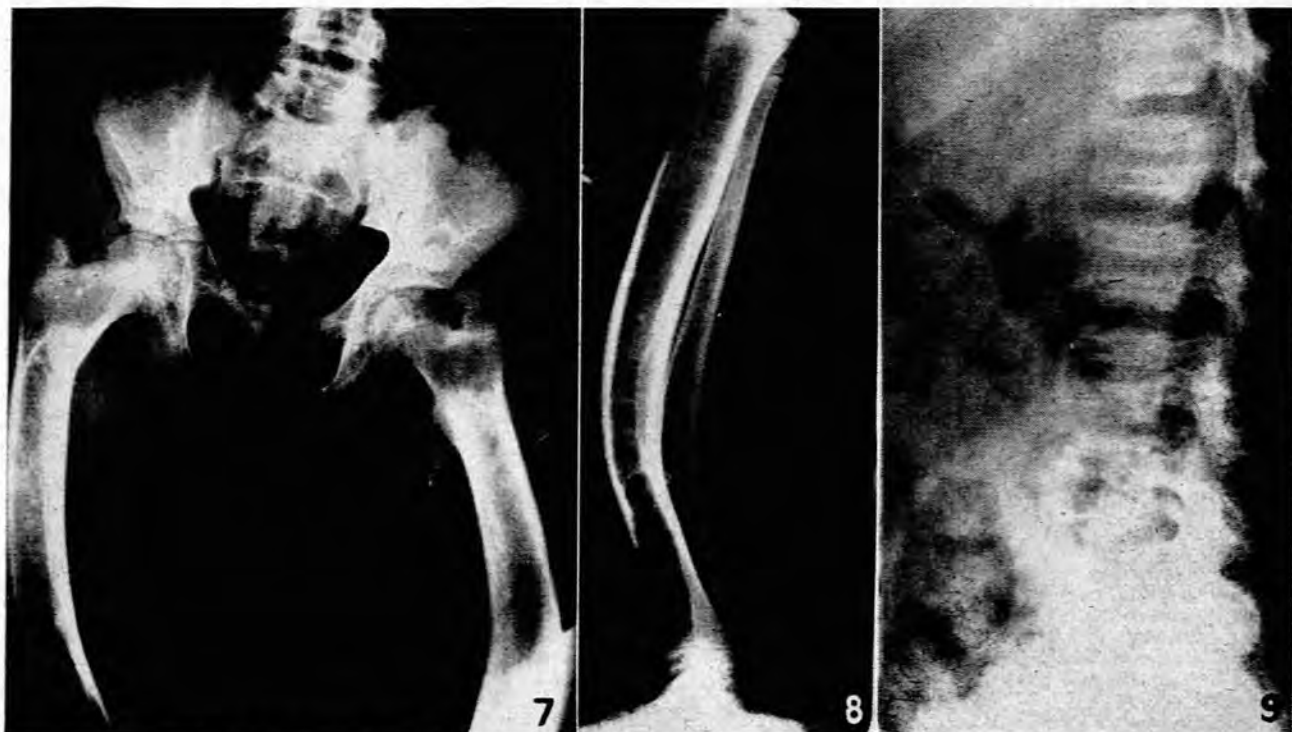
plaints of pain in legs on walking or standing. Two older siblings similarly affected.

**General examination:** Height 4 ft. 7½ inches. Pre-pubertal. Teeth showed similar gross caries at the gingival margins with the brown pigmentation and pitting of advanced fluorosis. Anterior bowing of the tibiae (the left more markedly affected than the right). Lateral bowing of the femora. No joint abnormality detected. Other systems clinically normal.

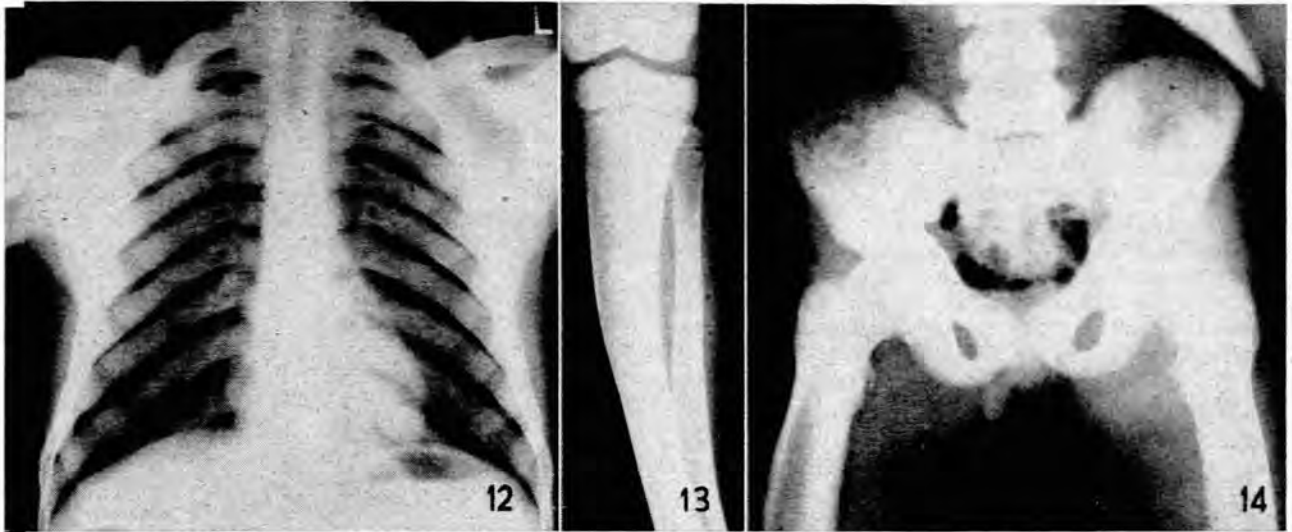
**Blood picture:** N.A.D.

**Urine:** N.A.D.

**Skeletal survey.** (See figs. 12-14.) Bone age is compatible with chronological age. Some of the bones showed rather in-



Figs. 7-9 X-rays of case I showing coarsening of trabeculae, demineralization, and deformities described in the text.



Figs. 12 - 14. X-rays of case 2 showing the characteristic findings of fluorosis in addition to the bowing of the femora and tibiae.

definite outlines. There was cortical thickening of the long bones and apparent generalized sclerosis as seen in moderately advanced fluorosis, with coarse trabecular pattern and early calcification at the attachments of the ligaments and muscles. The femora and tibiae were bowed in a similar manner to case 1.

Serum calcium, inorganic phosphorus, blood urea, serum potassium, sodium, chloride, and bicarbonate were all within normal limits.

*W.R. and Berger:* Negative.

*Urea clearance:* Normal.

24-hour urinary calcium was 41 and 63 mg. per 24 hours. 24-hour urinary phosphorus was 470 and 1,170 mg. per 24 hours. 24-hour urine for fluorine analysis revealed 6.6 mg. in a volume of 2,350 c.c.

*Bone biopsy (greater trochanter):* 'Specimen consists of a single piece of cartilage-covered bone 4.5 cm. in diameter.

Histology shows cessation of bone formation at the junction of bone and cartilage. Bone trabeculae vary in size and thickness, but most are somewhat cellular and a few contain small islands of cartilage in the midst of the bone. Occasional groups of active osteoclasts and osteoblasts are seen and cement lines are pro-

minent but have not resulted in a Paget's-like mosaic. Some basophilic stippling of bone matrix appears to be an artefact.

Neither excessive bone resorption nor woven bone formation, nor unduly wide osteoid seams were observed' (Dr. J. A. H. Campbell).

*Fluorine analysis of bone:* 8,500 p.p.m. fluorine.

#### X-rays of Parents of Case 2

The pelvis and upper ends of the femora of both adults (Figs. 15 and 16) present virtually the same appearance. There is gross generalized sclerosis, with obliteration of the trabecular pattern and thickening of cortices of the femora. Irregular outlines of the bones are produced by calcification in several ligamentous and muscular attachments.

#### FURTHER INVESTIGATIONS OF SAMPLES FROM THE AFFECTED AREA

##### Water

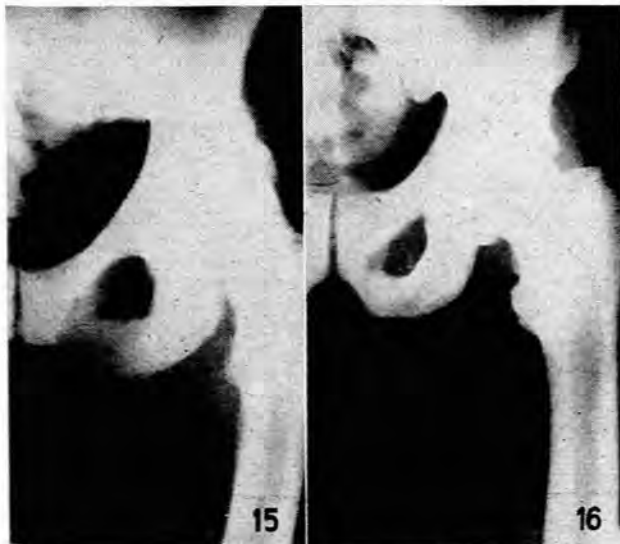
On investigating *water samples* for their *fluorine content*, the following findings were recorded: Rooiblok South 7.4 p.p.m., Rooiblok North 6.0 p.p.m., and 'dorp' (village) water 2.6 p.p.m. 'Dorp' water is also supplied to the other Coloured location. The critical level of fluorine content, with respect to bone disease, probably lies in the region of 2 p.p.m.

##### Animal Bone

The fluorine content of animal bone (sheep from Rooiblok location) was found to be 145 p.p.m. The results were calculated on the bone ash. Monier-Williams<sup>6</sup> gives the normal content of leg of lamb as 28 - 36 p.p.m. A live chicken was obtained from the affected area. Chickens are said to be abnormally resistant to fluorosis. When affected they develop a stiff-legged gait with ankylosis of the knee joints. The specimen bird was, unfortunately, a very young one. It was submitted to Dr. W. A. J. du Plessis of the Blue Cross Veterinary Hospital, Newlands, Cape, who kindly observed the bird. No abnormality could be found. It is still under observation.

##### Investigations in Progress

A further radiological and photographic survey of more affected persons and also 'controls' in the neighbourhood



Figs. 15 and 16. X-rays of parents of case 2 showing the classic characteristics of fluorosis.

is being organized, and further analyses of water and soil from the Kenhardt area are under way.

#### DISCUSSION

We have described a bone disorder occurring in a sharply delimited community and locality. There is good evidence that hereditary factors do not play any part.

It seems, therefore, that the causative factors must be environmental. Superficially the X-rays of the 2 young patients seen in this hospital suggest 2 different conditions, because the skeleton of one of the patients is more dense, and that of the other less dense than normal. More careful examination, however, indicates a basically similar pattern, for which the evidence is:

1. The clinical similarity of these 2 cases and others from the same locality.
2. Although the radiological consistency of the bone differs, the coarsening of the bony trabeculae and the type of gross deformity is similar in the 2 cases.
3. The abnormalities of the teeth were also the same in both patients.

It seems that this may be the same disorder seen at different stages of its development.

It is known that fluorosis is endemic in the Kenhardt area.<sup>1</sup> The teeth of people in this area show the mottling and pitting of fluorosis. In addition the caries which occurs at the gingival margin in gross fluorosis is common throughout the district. While a minimum fluorine content of drinking water is necessary and protective to teeth, the severe pitting found in advanced fluorosis may predispose to caries.

The X-ray findings in case 2 are quite characteristic of fluorosis, except for the altered shape of some of the bones which indicates an unusual degree of softening at some stage.

Classically, fluorosis manifests radiologically as a marked sclerosis, at first with accentuation of the trabecular structure. Later apparent coalescence of trabeculae gives a picture of generalized uniform increased density of the bones, which appear hazy in outline, chalky, and structureless. The regions of the spine and pelvis are most affected. In advanced cases, calcification of ligaments can occur.

The end-stage is that seen in the pelvis of the two adults as described above. Case 2 illustrates the earlier phase of fluorosis, although the bowing of the bones is not typical of this condition. Case 2 could be said to show a radiological picture somewhere between the picture of case 1 and that of his own parents.

There is little reference in the literature to softening or bowing of the bones in fluorosis. In his book on fluorine intoxication Roholm<sup>2</sup> discusses 3 clinical types: (1) Teeth changes, (2) the osteosclerotic form, and the (3) 'osteomalacic' form (also seen in animals) in which the bones are 'reduced in strength' and bone atrophy and defective calcification occur.

Weinmann and Sicher<sup>4</sup> in their discussion on fluorosis point out that the findings in spontaneous and experimental fluorosis are, in part, contradictory. The bones of human patients are usually diagnosed as sclerotic, while osteoporosis and 'osteomalacia' have been reported in diseased animals and in experiments.

These authors suggest that the radiological examination and the weights of bones may lead to a false impression, since X-rays may not differentiate between true osteosclerosis and the apparent increase of calcium content of bone due to calcification of the soft tissues, e.g. endosteum, periosteum, blood vessels, and ligaments. Their study of the histology had led them to postulate that the presence of fluorides causes rapid resorption of bone commencing in the marrow cavity, without inhibition of new-bone formation at the periosteal surface.

In young individuals the resorption is very rapid and the new bone is immature in type, consisting of loosely arranged spongy bone as opposed to the mature lamellated bone in older persons.

In a survey of fluorosis in Nalgonda, India, only dental changes in the children were found.<sup>3</sup> Shortt *et al.*<sup>5</sup> state that the bone changes take 30 - 40 years to develop. Poor nutrition, high altitude, and excessive heat were thought to be factors accounting for the earlier onset in the Nalgonda series. (Their youngest case with bone changes was 21 years old.)

Skeletal changes are rarely found in the USA in spite of fluorine levels of 8 p.p.m. in the water of certain regions.<sup>4</sup>

There can be no doubt that our young patients demonstrated fluorosis, in common with their elders. Despite the work quoted above, no mention of softening or bending of bones in clinical human fluorosis has been found, and in any event the clinical manifestations are rare in childhood. Furthermore, the concentration of fluorine in the drinking water is no higher than in many other places in the world, from where no similar phenomena have been reported.

Taking all the unusual aspects of our cases into account, perhaps we can postulate:

1. That fluorine is only one of the factors, though probably the most important, and
2. That in combination with either some other deficiency or a secondary factor, as yet unknown, fluorosis is occurring in an enhanced, accelerated, and unusual form.

We are presenting this problem in the hope that those of our colleagues, who may have come across similar cases in other areas, will contribute their experience and ideas to the solution.

#### SUMMARY

An unusual bone disorder is reported which occurs in a small localized community in the outskirts of Kenhardt. It is related to fluorosis.

We should like to thank Dr. J. G. Burger, Superintendent, Groote Schuur Hospital, Observatory, Cape, for his interest in this study; Prof. J. F. Brock, who arranged for us to undertake this investigation; Dr. L. Werbeloff; Dr. W. Rosenblatt, consultant dental surgeon to Groote Schuur Hospital; Dr. J. A. H. Campbell for the histological opinion; Dr. L. Been of the Union Health Department, for putting so many facilities at our disposal. Mr. N. Penny of the Government Laboratories for the chemical analyses, Mr. B. T. A. Todt for the clinical photographs and Mr. E. R. Levick for the diagram.

This work was supported in part by the South African Council for Scientific and Industrial Research, in a grant to the Endocrine Research Group of the University of Cape Town.

#### REFERENCES

1. Ockerse, T. (1946): *Endemic Fluorosis in the Union of South Africa*. Pretoria: Government Printer.
2. Roholm, R. (1937): *Fluorine Intoxication*. London: Lewis.
3. Siddiqui, A. H. (1955): *Brit. Med. J.*, 2, 1408.

4. Weinmann, J. P. and Sicher, H. (1955): *Bones and Bones.*, 2nd ed. St. Louis: Mosby.
5. Shortt, H. E., McRobert, G. R., Barnard, T. W. and Nayar, A. S. N. (1937): *Indian J. Med. Res.*, 25, 553.
6. Monier-Williams, G. W. *Trace Elements in Food.* New York: John Weley.

22 March 1960. Colour: White. Sediment: moderate.  
Muddiness: nil. Conductivity: 2,200

IN PARTS PER MILLION PARTS OF WATER

Total solids 1,480	Saline ammonia 0.04
Solids in suspension —	Albuminoid ammonia 0.24
Chlorine 500	Oxygen absorbed (4 hours at 27°C) 0.05
Sulphur - oxide 137	Total hardness 430
Nitrogen as nitrate 10	Permanent hardness —
Nitrogen as nitrite <i>nil</i>	Alkalinity (as calcium carbonate) 420'
Fluorine 4.8	

ADDENDUM

The following is an analysis of a specimen of water from a well in Rooiblok South. This analysis was done in the Department of Agricultural Technical Services Scientific Laboratory in Johannesburg.

Report on the analysis of a sample of water taken from No. 2—Rooiblok-Kenhardt—Open Well. Received on