

## FAMILIAL PES CAVUS, ABSENT TENDON JERKS AND EXTENSIVE MUSCULAR ATROPHY

HYAM ISAACS, M.B., B.CH., DIP. MED., *Medical Registrar, Johannesburg General Hospital*

Numerous heredo-familial disorders producing muscle atrophy have been described. Different syndromes present from time to time, each having characteristics which might appear specific for the family concerned. Only those syndromes have survived, in which the defect is slight or in which the defect only becomes severe or manifest after the age of procreation or in those who inherit the condition as a sex-linked genetic factor. An interesting example of this last mode of inheritance was described by Popow,<sup>1</sup> who followed four generations of a family of which 9 males were affected, showing features of the Roussy-Lévy syndrome.

Considering certain heredo-degenerative disorders, Spillane<sup>2</sup> has postulated a spectrum of disorder ranging between affections of the cerebellum and spinal cord, of which Friedreich's disease and peroneal muscular atrophy are examples, with the Roussy-Lévy syndrome as a sub-group. Different families have features which tend to be specific. This concept may be extended to include the higher centres, e.g. cases of mental disorder occurring in families with peroneal muscular atrophy, as described by Gibson,<sup>3</sup> or with peripheral nerve affections, as in hypertrophic polyneuritis of Déjerine and Sottas or as in peroneal atrophy itself. Concepts of this nature, however, over-simplify the problem. The term degeneration is all-embracing and does not take into account the possible varieties of metabolic and structural change which produces the same end-result. Metabolic failure at different stages of the same process or of different processes might be genetically determined and account for the variety of manifestations.

Peroneal muscular atrophy was first adequately described in France by Charcot and Marie,<sup>4</sup> and in England by Tooth.<sup>5</sup> The condition is transmitted as a Mendelian dominant, as a recessive, or rarely as a sex-linked gene. The onset is usually in adolescence but ranges from infancy to early adulthood. As is so often the case, the original description bears only a partial resemblance to the condition as we know it today. The original papers of Charcot and Marie and of Tooth, as summarized by Symonds and Shaw,<sup>6</sup> made no mention of pes cavus and only brief incomplete references to the reflexes. The condition was described as a progressive atrophy beginning in the feet and legs and affecting the hands and forearms after a lapse of several years. Sachs<sup>7</sup> was probably the first to emphasize the association with bilateral pes cavus. Sensation was generally described as normal. Since then, however, occasional cases have been noted with sensory disturbances, the commonest being loss of vibration sense in the lower extremity, other modalities being rarely affected. England and Denny-Brown<sup>8</sup> described 7 generations of a family consisting of 303 members, of which they studied 18. Two of these had extensive sensory trophic changes in addition to the muscular atrophy.

Roussy and Lévy<sup>9</sup> published their findings in a family showing bilateral pes cavus, weakness of the hands, and total absence of tendon jerks. They regarded the condition as a separate entity, distinct from Friedreich's disease on the one hand, and from peroneal muscular atrophy on the other. Symonds and Shaw<sup>6</sup> in the same year published a report of a family with a similar picture and considered that both families

represented *formes frustes* of the Charcot-Marie-Tooth disease.

A strong case can be made for the Roussy-Lévy syndrome as a separate entity; it has possibly as much right to separate identity as Friedreich's disease or Charcot-Marie-Tooth disease, all showing some features in common—for example, peroneal muscle atrophy with cerebellar signs of Friedreich's ataxia, as described by Ross<sup>10</sup> and Greenfield.<sup>11</sup> Of particular interest is the family described by Spillane.<sup>2</sup> Of the 21 affected members, 16 showed the Roussy-Lévy syndrome, 4 of whom had in addition an explosive type of dysarthria; 2 and possibly a 3rd, showed typical peroneal muscular atrophy. One showed typical Friedreich's disease with kyphoscoliosis, bilateral pes cavus, absent knee and ankle jerks, and bilateral extensor plantar responses. Von Bogaert and Borremans<sup>12</sup> presented 6 cases resembling the Roussy-Lévy syndrome, kyphoscoliosis, occurring in 4, lordosis in 1, and mental retardation in 1. There was no evidence of sensory or cerebellar disturbances. Rather than group their cases under Friedreich's disease, they postulated a separate genetic kyphoscoliotic factor. Other points of distinction of the Roussy-Lévy syndrome are the extreme chronicity of the condition, the widespread nature of the disorder, even though previously this may have been confined mainly to areflexia, and the absence of the cerebellar, ocular and cardiac involvement in cases of Friedreich's disease.

### THE AFFECTED FAMILY

The family described here was discovered when the patient A.F.A. presented at the medical out-patients department of the Johannesburg General Hospital in order to obtain a medical certificate for disability pension. The family tree is shown in Fig. 1, in which the members with pes cavus and

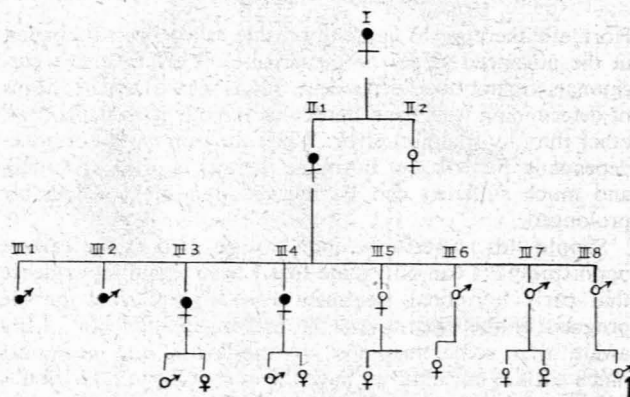


Fig. 1. Inheritance shown through 4 generations. Black circles denote affected members.

absent tendon jerks, and for muscular atrophy, are indicated with black circles. It will be seen that one-half of the members of the 3rd generation shown are thus affected.

1 (III 1).

A.F.A., aged 39 years, married, had no children of his own. He complained of progressive weakness of the whole body. The trouble first started in 1939 when, at the age of 21, he developed

weak ankles so that his feet would turn inwards. At this time he had already noted the development of 'hammer toes'. The condition slowly progressed, so that in 1942 an arthrodesis was performed on both ankle joints, with marked improvement in walking. Weakness of the hands was noted first about 10 years later, and has progressed to the present stage, when opposition of the thumbs is impossible. Weakness of the shoulders and difficulty in rising from the sitting position have been noted lately. There has never been any sphincter disturbance. Eyesight is normal and the patient walks well with a narrow high-stepping gait. When questioned about other members of the family, he stated originally that they were all normal, but at a subsequent interview numerous abnormalities were disclosed.

On examination: A well adjusted male of good intellect. B.P. 120/70 mm. Hg. Normal cardio-vascular, respiratory, gastro-intestinal and genito-urinary systems. The cranial nerves were intact, with the possible exception of the muscles of expression. There was a little difficulty in whistling, and the smile was rather straight, suggesting some weakness of the zygomaticus. The blown-out cheeks were of poor tension and the temporal muscles were small. The muscles of the shoulder girdle, pelvic girdle, hands, feet and legs were small and atrophic. Over the gluteus maximus and medius fibrillation could be seen. The legs show the typical 'rooster leg' appearance of peroneal-muscle atrophy and the feet show marked pes cavus with the typical 'Friedreich's toes'. The tendon reflexes were absent; the cutaneous reflexes were present and normal. Sensation was intact with the exception of vibration sense, which was lost in the lower limbs up to the hips. Muscle tone was diminished and movement and power in the affected muscles was reduced. Coordination was normal; cerebellum normal.

*Facial muscles:* Slight weakness of zygomaticus and orbicularis oris on both sides.

*Shoulder girdle:* Moderate atrophy of all muscle, more marked on the right side, where complete atrophy of rhomboids.

*Pelvic girdle:* Atrophy of all muscle groups on both sides, most marked in the glutei.

*Lower extremity:* Moderate atrophy of all muscle groups on both sides. Marked atrophy of leg muscles and small muscles of feet.

*Upper extremity:* Moderate atrophy of all muscles on both sides, with marked atrophy of small muscles of hand and total loss of opponens pollicis.

*Spinal, thoracic and abdominal musculature:* Power slightly reduced on both sides; otherwise normal.

Muscle reaction to stimulation showed the reaction of degeneration over affected muscles. Muscle biopsy confirmed the atrophy. Details of muscle atrophy are as follows: The 24-hour excretion of creatinine and creatine showed an increase in creatine to 326 mg. per 24 hours (average). All other investigations were normal, with the exception of the CSF protein, which was 80 and 84 mg. % on 2 occasions.

The progression of the condition over the years has been extremely slow. The patient is a carpenter and is still able to supplement his pension by doing odd jobs.

#### 2 (II 1)

Mother of case 1, aged 68 years. Has pes cavus, broad feet, absent knee and ankle jerks, and loss of vibration sense up to the knee. Cerebellum normal on testing. States that she developed 'hammer toes' at about 16 years of age, and that her mother had claw toes with high arched feet and had to wear boots for as long as she could remember. The family originated in Germany. She has a sister who cannot be traced.

#### 3 (III 3)

Sister of case 1, aged 44 years. Has pes cavus, broad feet, absent ankle jerks, intact sensation and no cerebellar signs. Her son of 18 years and daughter of 14 years are both said to be normal.

#### 4 (III 5)

Sister of case 1, aged 40 years. Has high arched feet but no pes cavus. Reflexes extremely brisk, particularly in the lower limb, plantars flexor. Sensation intact. No cerebellar signs. Has son aged 7 years, has high arched feet, otherwise normal; daughter aged 9 years, normal.

#### 5 and 6 (III 6 and III 7)

Twin brothers of case 1, aged 35 years. High arched feet, no pes cavus. Reflexes and sensation normal. No cerebellar signs.

One has a daughter of 7 years, normal, and the other has daughters aged 5 years and 3 years, both normal.

#### 7 (III 4)

Sister of case 1, aged 31 years. Has high arched broad feet, legs thin up to knees, and arms thin up to elbows, and has noted that she has been getting thinner and weaker progressively over the past 10 years. Wasted thenar eminences; atrophy of muscle of shoulder girdle most marked on the right. Details of muscle atrophy are as follows:

*Facial muscles:* Normal on both sides.

*Shoulder girdle:* Slight atrophy of all musculature, most marked on the right side, where mainly in rhomboid.

*Pelvic girdle:* Normal on both sides.

*Lower extremity:* On both sides slight atrophy of all groups and moderate atrophy of leg muscles (except peronei and long extensors and flexors, which are normal).

*Upper extremity:* Slight wasting of all muscles on both sides. Moderate atrophy of small muscles of hand.

Absent reflexes. Sensation normal, cerebellum normal. Has 2 children aged 3 years and 3 months respectively, both normal.

#### 8 (III 8)

Brother of case 1, aged 28 years. High arches; normal toes; marked hyperreflexia, especially in the lower limbs. Sensation normal. Normal cerebellum. His son aged 2 years is normal.

#### 9 (III 2)

Brother of case 1, aged 24 years, pes cavus, absent ankle jerks, sensation normal. No cerebellar signs.

#### DISCUSSION

In Friedreich's ataxia, peroneal atrophy and the Roussy-Lévy syndrome, the one frequent feature which is common to all is pes cavus. Superficially, one might regard this as a link between the three conditions, but it must be remembered that the pes cavus is a secondary manifestation and is not itself genetically determined, the primary defect occurring either in the peripheral nerves or anterior horn cells of the spinal cord and resulting in atrophy of the small muscles of the foot. The unopposed action of the long muscles of the leg, if not affected at the same time, or if affected to a lesser degree, moulds the foot into the characteristic deformity. The long muscles of the legs may be affected first or more severely, and then pes cavus does not occur; in fact pes planus may result. Peroneal atrophy is a bad term, because the brunt of the atrophy may, as previously mentioned, occur in other muscles such as those of the foot, and particularly those of the anterior compartment of the leg, leading to foot drop. When in fact the major atrophy occurs in the peroneal group, the patient stumbles with the foot in an inverted position.

In peroneal atrophy, the site of the primary pathology has been a source of contention for years. In the original description, Tooth held that the pathology was primarily in the peripheral nerve, as opposed to Charcot and Marie, who cited the spinal cord. This argument has continued to the present time, with Kinnear-Wilson<sup>13</sup> in favour of the spinal cord, and England and Denny-Brown<sup>8</sup> in favour of the peripheral nerve and regarding the spinal change as secondary to peripheral degeneration. The latter authors consider the Roussy-Lévy syndrome a separate entity with primary spinal pathology.

Case 1 has the typical 'rooster legs', pes cavus, atrophy of the small muscles of hands starting years later (involving to a lesser extent the forearms), loss of vibration sense up to the hip joint, all of which are characteristic of peroneal muscular atrophy. But against this diagnosis is the fact that the wasting does not stop at the lower third of the thigh, nor does it stop at the elbows. Marked wasting is noted with fibrillation affecting the shoulder and pelvic girdle.

The slight atrophy of the muscle of the face, with atrophy

of the shoulder girdle, could be confused with the muscular dystrophy of Erb or with that of Landouzy and Déjerine, but this latter condition is excluded clinically by the involvement of small muscles, pes cavus, areflexia, etc.

Friedreich's ataxia can hardly be included in the differential diagnosis, the only compatible features being the pes cavus and areflexia of lower limbs.

Case 1, and to a lesser extent case 7, are considered to be examples of the Roussy-Lévy syndrome, case 1 showing a degree of atrophy hitherto not recorded. Gordon<sup>14</sup> reported 4 cases of the Roussy-Lévy syndrome with right-sided scapulo-humeral atrophy; in the present cases scapulo-humeral atrophy was most marked on the right side. In the present family the onset of the disease occurs in early adult life, with gradual development of pes cavus, and in most members this remains the only manifestation. The progress is extremely slow and the atrophy out of all proportion to the disability produced. With the aid of well-timed orthopaedic procedures, these people can be kept active for what might well be a normal life span.

#### SUMMARY AND CONCLUSIONS

Four generations of a family comprising 21 members (Fig. 1) have been studied. A hereditary neurological disorder was observed. The mode of transmission appears to be through a Mendelian dominant gene, for the incidence of abnormality in the 3rd generation approaches the anticipated 50%.

Widespread atrophy is noted in one member and to a lesser

degree in another. No evidence of cerebellar involvement could be found. An unusual degree of hyperflexia was noted in 2 other members. The 4th generation were observed to be quite normal at present, but affected members are to be anticipated as the condition in this family only becomes manifest in early adult life. The condition is considered to be an example of the Roussy-Lévy syndrome. Its relation to Friedreich's ataxia and peroneal muscular atrophy have been discussed, the latter in detail, as the Roussy-Lévy syndrome is usually included under this heading.

A plea is made for the retention of the syndrome as a separate entity.

I wish to thank Prof. G. A. Elliott, for reading and correcting this paper, and Dr. A. L. Agranat, Physician, and Dr. K. Mills, Medical Superintendent, of the Johannesburg General Hospital for permission to submit this article for publication.

#### REFERENCES

1. Popow, A. (1932): *Rev. neurol.*, **2**, 583.
2. Spillane, J. D. (1940): *Brain*, **63**, 275.
3. Gibson, R. (1956): *Brit. Med. J.*, **2**, 1281.
4. Charcot, J. M. and Marie, P. (1886): *Rev. Medicine*, **6**, 97.
5. Tooth, H. H. (1886): *The Peroneal Type of Progressive Muscular Atrophy*. London: H. K. Lewis.
6. Symonds, C. P. and Shaw, M. E. (1926): *Brain*, **49**, 387.
7. Sachs, B. (1889): *Ibid.*, **12**, 447.
8. England, A. C. and Denny-Brown, D. (1952): *A.M.A. Arch. Neurol. Psychiat.*, **67**, 1.
9. Roussy, G. and Lévy, G. (1926): *Rev. neurol.*, **1**, 427.
10. Ross, A. T. (1942): *Neur. J. and Ment. Dis.*, **95**, 680.
11. Greenfield, J. G. (1911-1912): *Proc. Roy. Soc. Med.*, **5**, 75.
12. Von Bogaert, L. and Borremans, P. (1932): *Rev. Neurol.*, **2**, 529.
13. Wilson, S. A. K. (1940): *Neurology*, vol. 2. London: Edward Arnold & Co.
14. Gordon, A. (1933): *Med. J. Rec.*, **138**, 13.