

A HAZARD ASSOCIATED WITH THE USE OF A FACE MASK: CASE REPORT

S. V. POTGIETER, M.B., CH.B., and J. W. MOSTERT, M.B., CH.B., D.A. (LOND.), F.F.A.R.C.S. (ENG.),*

Karl Bremer Hospital, University of Stellenbosch

Hazards directly associated with the clinical application of face masks for purposes of anaesthesia, of resuscitation, or both, are not generally known. A sequela is here reported, with a brief discussion of the care needed in the use of rubber face masks, and the results of an investigation prompted by our suspicion (which proved to be unfounded) that the new chemically-active anaesthetic halothane (fluothane) might be incriminated.

At the Karl Bremer Hospital it is standard practice for the anaesthetic face masks to be washed with hexachlorophene soap and water *only* after each use and powdered with talc when dry.

CASE REPORT

J.M.S., a European female patient aged 35 years, underwent an appendectomy, the anaesthetic time being 1½ hours. Pre-medication consisted of 50 mg. of pethidine, 25 mg. of phenergan, and 0.65 mg. of atropine. For induction of anaesthesia the patient received 400 mg. of thiopentone, and anaesthesia was maintained with halothane vaporized from a Rowbotham bottle

* Now of King Edward VIII Hospital, Durban.

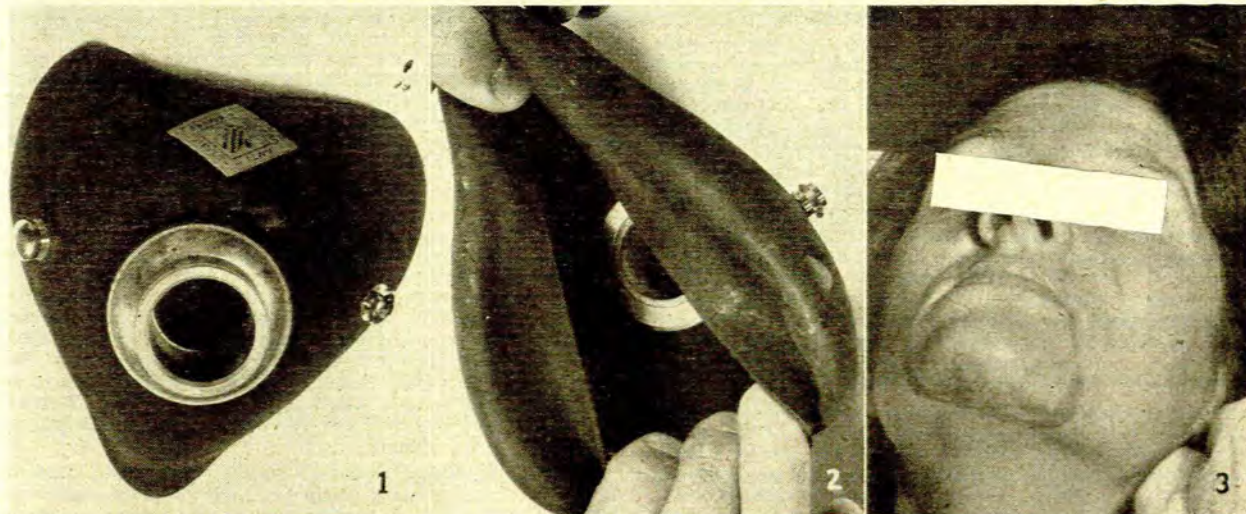
inserted into the inspiratory limb of a semi-closed Boyle mark-11 circle absorption system. A dose of 60 mg. of gallamine ('flaxedil') was given fractionally to aid relaxation. Oxygen only, at a flow rate of 1 litre per minute, was led into the absorption system.

A size 3 M. & I.E. 'Eversal' rubber mask (Figs. 1 and 2) was fixed tightly in position by a harness, over a rubber Water's oropharyngeal airway, in such a way that the chin was held up by the mask, so that manual support of the jaw was unnecessary.

On the following morning a chemical burn exhibiting some dark pigmentation (Fig. 3) withstood the attempts of one of the nurses to remove it; the lesion resembled an impression of the face mask so closely that the nurse tried to rub it off believing it to be a stain.

DISCUSSION

While it is obvious that the eyes need protection from a mask, neither of us had seen or heard of such a burn on the face. Trivial lacerations of the lips are known to result from improperly applied masks, but there was nothing to suggest significant pressure or allergy in the present case. Dr. J. Marshall, consultant dermatologist at the hospital, confirmed the diagnosis of primary chemical burn followed by increased pigmentation which in time would disappear entirely. The lesion faded and was, in fact, hardly visible 14 days later.



Figs 1, 2 and 3.

Our investigation was therefore directed to the anaesthetic masks as such. Something must have rendered the mask used in this case harmful to the skin. On smelling the masks one with a slight but distinct phenolic odour was found. On questioning, the anaesthetic nurse stated that, after cleaning a theatre in which a patient suffering from tetanus had been operated on, the anaesthetic equipment had been left to soak in a weak solution of 'instrument dettol' and water. After this the mask had been washed with soap and water, and because it still had a faint smell it was again washed with soap and water, and only then made available for routine use. To exclude a possible sensitivity in the patient a patch test was done on her with antistatic rubber soaked in (1) halothane, (2) a 5% solution of 'instrument dettol', and (3) halothane and a 5% solution of 'instrument dettol'; and with white lint soaked in (1) 5% 'instrument

dettol' and (2) halothane. The patches were covered with waterproof adhesive plaster and left for 48 hours. Upon removal, and after washing the skin to remove traces of the black antistatic rubber, no skin lesion could be seen.

CONCLUSION

A patient suffered a primary chemical burn of the face after a surgical procedure, as a result of 'instrument dettol' being in contact with the face mask used (a practice warned against by the manufacturers). Although it was a weak solution repeated subsequent washing with soap and water did not remove it. A first-degree burn was sustained by the first patient on whom it was subsequently used.

We wish to thank Dr. R. S. Cormack, Medical Superintendent (acting), Karl Bremer Hospital, for permission to publish this case report.