

FUNICULAR DIRECT INGUINAL HERNIA

P. G. LARGE, M.S. (LOND.), F.R.C.S. (ENG.) and A. BEILES, M.B., B.CH. (RAND), F.R.C.S. (EDIN.),

Departments of Anatomy and Surgery, University of Natal

The first description we have found of this hernia is that of Ogilvie (1937). He described its main features as consisting of a tubular process of peritoneum passing through a small circular defect in the posterior wall of the inguinal canal medial to the inferior epigastric vessels (Fig. 1). He described the margins of this defect in the fascia transversalis as firm, sharply defined, and almost tendinous. He pointed out that the sac often passes through the superficial inguinal ring and that the hernia may be indistinguishable on clinical examination from an indirect inguinal one. He believed that the circular opening in the fascia transversalis which is found in cases of funicular direct hernia did not represent the general weakness of this fascia which is so evident in cases of direct inguinal hernia. Gill (1939) recorded details of 3 cases of funicular direct inguinal hernia in males aged 26, 59, and 40 years. In the second of these a Richter's hernia was present, and the third was a recurrence after recent repair of an inguinal hernia. He mentioned in a footnote a similar hernia in a female. He also considered that such herniae are indistinguishable clinically from the indirect inguinal variety. Both these authors stressed the importance of searching for such a hernia during all operations for hernial repair.

Burton and Blotner (1941) used the term 'diverticular hernia' to describe small pear-shaped or sausage-shaped protrusions of peritoneum or fat through rents in the fascia transversalis. They described the margins of such rents as being sometimes clearly demarcated. They stated that such 'diverticula' are in 87% of cases offshoots of a direct inguinal hernia or the direct part of a bilocular inguinal hernia. Only rarely was the diverticulum found unassociated with direct inguinal hernia.

We believe that the term 'diverticular hernia' as defined by Burton and Blotner includes herniae of the type described by Ogilvie and Gill, though they do not refer to these authors. We consider the term 'diverticular' applied to hernia to be imprecise and misleading, because it is applicable in a sense to all herniae. Aird (1946) uses the term 'funicular direct hernia' and this is adopted in this paper because it is an accurate description of the hernia.

In spite of these papers, funicular direct hernia has received scant recognition and, although it is rare, a knowledge of its existence is important if therapeutic errors are to be avoided. We record 4 cases: case 1 operated on by Sir Heneage Ogilvie, cases 2 and 4 by one of us (P.G.L.) and case 3 by Mr. E. M. Barker.

CASE REPORTS

Case 1

A male aged 32 years was admitted to Guy's Hospital in 1949 with a clinical diagnosis of right indirect inguinal hernia, which extended into the scrotum. At operation the sac was seen to come through a well defined defect about $\frac{1}{2}$ inch in diameter in the fascia transversalis medial to the inferior epigastric vessels. The sac had passed through the superficial inguinal ring. Repair

of the defect was by approximation of its edges with a silk stitch after dissection and excision of the sac.

Case 2

An Indian male aged 32 years was admitted to King Edward VIII Hospital in 1957. In 1949 he had an operation for a left inguinal hernia but was disconcerted to find the hernia still present, and quite unaltered, on getting out of bed a few days after the operation. The second admission was for strangulation of a left indirect inguinal hernia which reduced spontaneously. Later clinical examination showed an indirect inguinal hernia, which descended into the scrotum. At operation the external oblique aponeurosis was found to be scarred but the cremaster was not, and did not appear to have been dissected previously. A hernial sac was found which extended into the scrotum within the cremaster and behind the spermatic cord. It passed through a defect in the fascia transversalis $\frac{1}{2}$ inch in diameter, lateral to the outer edge of the rectus abdominis muscle and above the level of the pubic tubercle. This defect had sharply defined and thickened edges, and the sac itself was thickened at this point. The sac was excised and ligated and the defect in the fascia transversalis was closed with braided nylon sutures. This repair was reinforced by a nylon lattice passing from the rectus sheath to the inguinal ligament and covering the whole area extending from the pubic tubercle to the deep inguinal ring.

Case 3

An Indian male aged 30 years was admitted to King Edward VIII Hospital in 1957. He had had a swelling in the right groin for 11 years. This swelling had not descended into the scrotum and a clinical diagnosis of indirect inguinal hernia was made. At operation a narrow and elongated sac was found within the cremasteric fascia behind the spermatic cord. It came through a sharply defined defect in the fascia transversalis about $\frac{3}{8}$ inch in diameter. Bladder wall was found in the medial wall of the

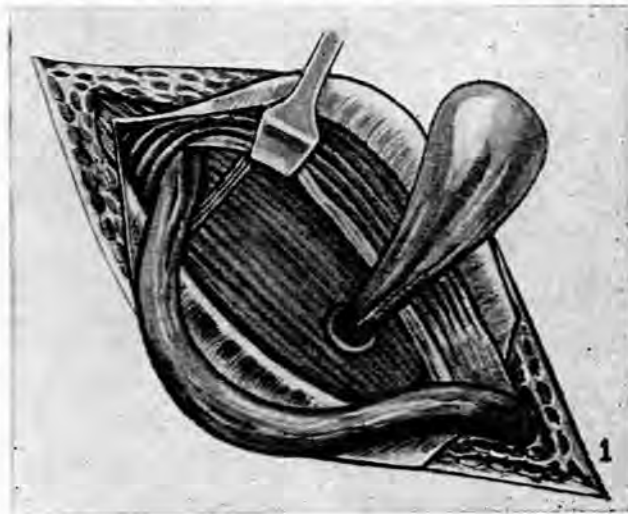


Fig. 1. Diagram of the right inguinal canal, as seen at operation for hernia, showing the sac of a funicular direct inguinal hernia and its relation to the fascia transversalis and inferior epigastric vessels. The diagram also shows the external oblique aponeurosis, the spermatic cord and the internal oblique muscle.

sac, which was freed, ligated, and excised. The defect in the fascia transversalis was repaired with silk sutures.

Case 4

A European woman aged 40, who had had an inguinal hernia for 2 years. The sac passed through the superficial inguinal ring and a clinical diagnosis of indirect inguinal hernia was made. At operation the sac was narrow and elongated. Its neck was at a well defined defect in the fascia transversalis, $\frac{1}{4}$ inch in diameter, with thick margins lying medial to the inferior epigastric vessels. The bladder wall lay in the medial wall of the sac, which was excised after freeing it. The defect in the fascia transversalis was repaired with catgut sutures.

DISCUSSION

The anatomical features of these 4 herniae are the same as those described by Ogilvie and Gill. Thus they are unlike the more common direct inguinal hernia, in which there is a diffuse bulge due to weakness of the fascia transversalis. In general, the ages of the patients described here are less than those with direct inguinal herniae. In all these patients, the defects in the fascia transversalis were well defined with sharp and thickened margins, and the sac was tubular. All were diagnosed clinically as indirect inguinal herniae, and strangulation had occurred in one of our cases (case 2), as in one of Gill's cases (1939). Bladder lay in the medial wall of the sac in cases 3 and 4 and in one of Gill's cases. Case 4 described here was a woman, as was one of those mentioned by Gill.

The aetiology of funicular direct hernia is obscure. All these herniae manifested themselves in adult life, which indicates that they were acquired, as there is no known embryological reason why there should be a defect in the fascia transversalis medial to the inferior epigastric vessels. We believe with Ogilvie and Gill that this type of hernia is probably acquired and that its cause differs from that of the diffuse bulge of the fascia transversalis usually seen in direct inguinal herniae. It is likely that the fascia transversalis defect is traumatic in origin and, because its margins are strong, the sac tends to be tubular and its neck small.

Treatment

The importance of this hernia lies in possible failure to recognize it at operation, which occurred in case 2 and in one of Gill's cases. Should this failure occur in the presence of a strangulated knuckle of bowel the consequences might be disastrous. With mobilization of the spermatic cord and cremaster muscle the presence of a funicular direct hernia will always be obvious. The general principles of hernial repair are followed, viz. complete excision of the sac, closure of the defect in the fascia transversalis, and reinforcement of the posterior wall of the inguinal canal where required. It is a simple matter to close the small defect by suture without tension since the fascia transversalis is not a rigid structure.

SUMMARY AND CONCLUSIONS

1. Four cases of funicular direct inguinal hernia are reported.
2. This hernia has received scanty recognition in the text-books and other literature.
3. The aetiology and anatomy are discussed.
4. The importance of its recognition at operation is stressed.
5. The operative repair is indicated.
6. Inspection of the fascia transversalis as a routine at all operations for the repair of inguinal hernia would reduce the chances of overlooking a funicular direct hernia.

We are indebted to Sir Heneage Ogilvie for permission to publish details of case 1, to Prof. A. E. Kark and Dr. S. Disler, Superintendent of King Edward VIII Hospital, of cases 2 and 3, and to Mr. L. V. Pearson of case 4.

REFERENCES

1. Ogilvie, H. ed. Maingot, R. (1937): *Post-Graduate Surgery*. Vol. 3, p. 3,620. London: Medical Publications.
2. Gill, W. G. (1939): *Brit. Med. J.*, 1, 263.
3. Burton, C. C. and Blotner, C. (1941): *Surg. Gynec. Obstet.*, 73, 212.
4. Aird, I. (1949): *Companion in Surgical Studies*, p. 534. Edinburgh: Livingstone.