

## INTERNAL CAROTID ARTERY THROMBOSIS

## A CASE REPORT

N. MCE. LAMONT, M.D. (GLASG.), F.R.F.P.S.

and

D. BRINK, M.B., CH.B. (CAPE TOWN), D.M.R.D. (LOND.)

*King Edward VIII Hospital, Durban*

It was in 1937 that Moniz<sup>1</sup> first reported angiographic studies in carotid-artery thrombosis, thereby focussing attention on this rare condition. We report this case in detail as it has presented with certain unusual features.

## CASE REPORT

An African Pondo male, aged approximately 40 years, was working on 6 April 1956, when he complained of headache. The next day he had a right-sided Jacksonian seizure, which was witnessed by the medical officer of the sugar company for which the patient worked as a cane-cutter. On the following day he was paralysed on the right side of his body, and was noticed to have a speech defect. He was admitted on the next day (9 April) to this hospital.

Examination showed the patient to be in a drowsy state and completely inarticulate. The *dysphasia* seemed more motor than sensory in that he appeared to understand commands, but failed to respond correctly. He was incontinent of urine but there were no signs of retention. His first bowel-action took place 5 days after admission with the aid of an enema. He showed no signs of distress and was not restless.

*Nervous System*

A detailed examination of the nervous system showed the following positive findings (the examination was completely objective on account of the *dysphasia*):

*Cranial Nerve II.* (a) *Visual Fields.* Accurate assessment in the early stages was not possible, but later examination failed to reveal any hemianopia. It was, however, suspected that the vision of the left eye was impaired at the original examination. (b) *Fundi.* There was distinct papilloedema of the left optic disc. The veins were engorged, but there were no haemorrhages. The right fundus was normal. These findings changed after the patient had been in hospital for 5 days, shortly after an arteriogram was performed. Marked pallor of the left retina, a pale disc, a few poorly-filled vessels, and a cherry-red spot at the macula were found. The picture was in fact one of complete occlusion of the central artery of the retina. On 25 May, 6 weeks later, examination showed the fundus of the right eye to be normal, and confrontation showed no apparent sectorial field loss. The left eye had the appearance of an old occlusion of the central artery of the retina with attenuated vessels, optic atrophy, and haemorrhagic residues at the macula.

*III, IV, VI.* The left pupil was slightly larger than the right, and contracted only when light was shone in the right eye. Eye movements were normal, but there was a transient deviation to the right side for the first 4 days.

*V.* Both motor and sensory branches seemed intact, and the conjunctival reflex was present in both eyes.

*VII.* An upper-motor-neurone lesion of the right side of the face was evident.

*IX, X, XI, XII.* The patient fed well without any nasal regurgitation, and there was no deviation of the protruded tongue.

*Motor System.* Muscle tone was increased on the right side of the body, which was totally paralysed.

*Sensory System.* Pain was the only sensation assessable, and protest was elicited to pin-prick on the face, trunk, arms and legs on each side of the body.

The *reflexes* were those of an upper-motor-neurone lesion of the right side of the body.

*Cerebrospinal Fluid.* The pressure was 45 mm. of water, and the globulin was slightly increased. There were 6 erythrocytes per c.mm. Chlorides—710 mg. % (as NaCl); Protein—110 mg. %.

*Other Findings*

All *pulses* were palpable. The left carotid pulse at the level of the angle of the jaw was, however, appreciably more difficult to feel than the right.

The *blood pressure* was 110/70 mm. Hg.

The *liver* was palpable 1 inch below the costal margin in the mid-clavicular line, and was of firm consistency.

*Blood Examination.* Haemoglobin 13.2 g. % (89%); P.C.V. 39%; M.C.H.C. 34%. W.B.C. 7,000 per c.mm. (P. 58%; L. 34%; M. 4%; E. 4%). The blood Wassermann reaction was positive in 4 dilutions. Alkaline phosphatase 9 K.A. units. Zinc turbidity 14 units. Total proteins 7.0 g. % (albumin 3.2 g. %, globulin 3.8 g. %). A/G ratio 0.8 : 1. Cephalin cholesterol—24 hours ++, 48 hours +++.

*Liver Biopsy.* A good core of tissue was obtained from the right lobe of the liver (Figs. 1 and 2). This showed a mild degree of

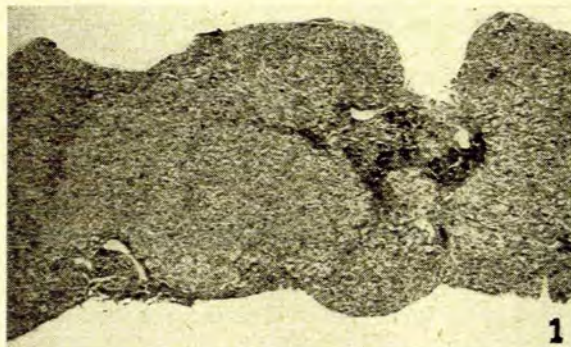


Fig. 1. Appearances of liver biopsy showing lobular distortion producing 'scalloping' of the borders of the biopsy specimen and thickening of the portal tracts loaded with iron-containing phagocytes.  $\times 23$ .

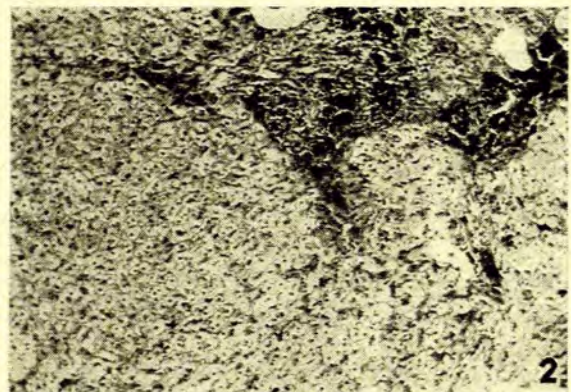


Fig. 2. Higher-power view of complete portal tract (right of centre in Fig. 1), showing coarse granular iron pigment in portal tract with stellate processes of fibrous tissue radiating from this portal tract.  $\times 150$ .

hepatocellular fat and siderosis, with a moderate degree of portal siderosis. Architectural distortion was evident. The appearance was one of early cirrhosis of the liver with nutritional siderosis.

X-ray of chest showed no abnormal shadows.

Arteriography (12 April). Under local anaesthesia, the left carotid artery was punctured percutaneously by means of the Seldinger technique. The preliminary palpation established that

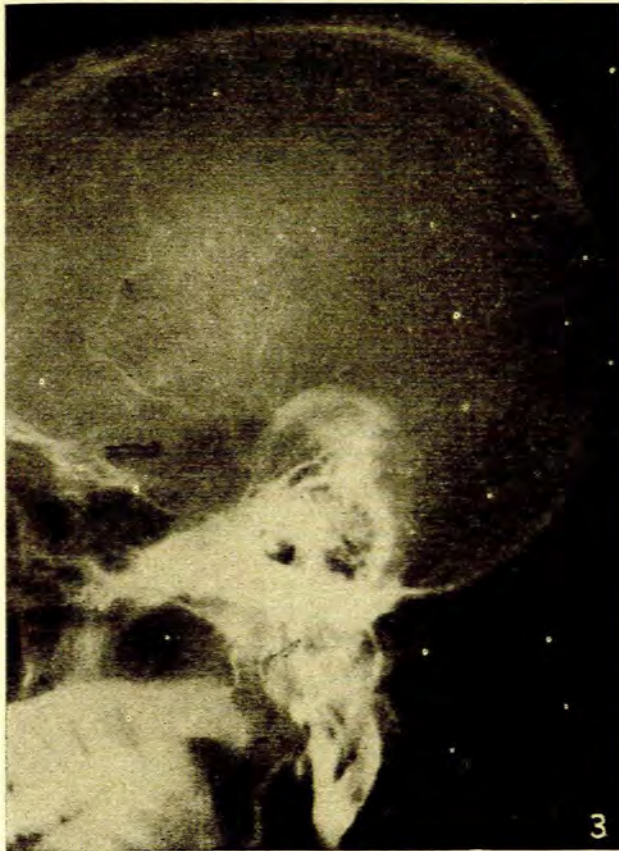


Fig. 3. Arteriogram showing occlusion of internal carotid artery close to its origin.

the artery was rather cord-like, with appreciable diminution in pulsation as compared with the right. The first injection of dye (Diagonal 40%) produced filling of the external carotid artery only, and it was thought that the catheter had possibly entered the external carotid artery. The catheter was slightly withdrawn and the tube centred down to include the neck. On repeat injection, a well-defined block of the internal carotid artery just beyond the bifurcation was demonstrated. Filling was absent beyond this point. (See Fig. 3).

#### Progress

During 7 weeks' observation in hospital, the patient became less drowsy, and his vocabulary increased to 4 words. Whereas at the beginning he was rather vegetable-like in his behaviour, he subsequently became emotionally labile, with occasional violent outbursts.

#### Treatment

As a prophylaxis against pulmonary infection, a 10 days' course of penicillin was given at the beginning of hospitalization. Apart from physiotherapy, no other active measure was employed. Anti-coagulants were not used.

#### DISCUSSION

The distinctive features of this case were the sudden onset of right-sided hemiplegia and dysphasia (implying

involvement of that part of the brain supplied by the middle cerebral artery), together with ipsilateral papilloedema, which changed after 5 days to complete occlusion of the central artery of the retina. The latter artery is a branch of the ophthalmic artery, which rises from the internal carotid between the carotid bifurcation and the carotid syphon. It follows that those cases with the occlusion in the region of the carotid syphon will not present local eye signs, whereas those cases with the block near the bifurcation are liable to develop ipsilateral eye signs.

There is an effective anastomosis between the ophthalmic and external carotid arteries. It would appear that in the case we have presented, this anastomosis was functioning initially. Ralph<sup>2</sup> mentions that in cases of carotid artery thrombosis cerebral oedema occurs initially, followed by cerebral atrophy and dilatation of the lateral ventricle. This has been shown in ventriculographic studies. The initial cerebral oedema and resultant venous occlusion, together with the anastomosis between the ophthalmic and external carotid arteries mentioned above, would account for the development of papilloedema in the left eye in the case we have described.

Ralph also draws attention to the fact that filling of the anterior, and less commonly the middle, cerebral arteries of the affected side takes place when dye is injected into the opposite (patent) carotid artery. This 'cross-filling' takes place *via* the anterior communicating artery in the circle of Willis. The major effect of the internal-carotid thrombosis is therefore manifest most often upon the territory supplied by the middle cerebral artery.

It may be significant that the occlusion of the central artery of the retina developed shortly after arteriography (the arteriogram was done on 12 April, and the occlusion appeared on 13 April). Vascular spasm, a feature common during arteriography, may have caused the final sealing off of the anastomotic blood-supply to the left eye. This must have been precarious, as shown by the functional interruption of the pathway of the light reflex which was found at the first examination. This raises the question whether the intra-arterial injection of vasodilator drugs such as procaine before the injection of contrast medium should be undertaken as a routine measure in cerebral arteriography.

Ralph points out that the procedure of 'cross-filling' has been attended by a fatal outcome in 4 reported cases, and he stresses the inadvisability of its use as a routine diagnostic procedure.

The symptomatology in 107 reported cases of thrombosis of the internal carotid artery has been reviewed by Johnson and Walker.<sup>3</sup> According to their analysis, the case we have described would appear to fall into the group characterized by sudden catastrophic onset (35% of the 107 cases). The other main groups were those with a slowly progressive course (25%), and those with transient attacks (40%). Papilloedema was recorded in only 2 cases of the 107 reported. There was no case mentioned with initial papilloedema followed by occlusion of the central artery, nor was consensual contraction to light of the pupil recorded. A positive serological reaction for syphilis was found in only 2 cases in the analysis.

The angiographic picture of the occlusion (Fig. 3) differs in outline from the types described by Gurdjian and Webster<sup>4</sup> (Fig. 4). They record none in which the block was convex downwards. We can only assume that

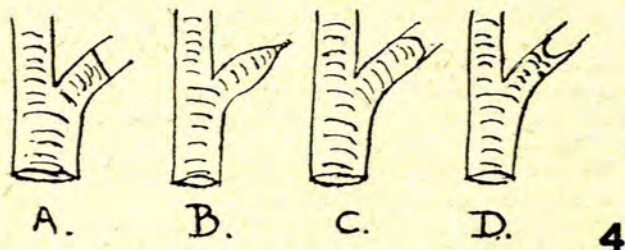


Fig. 4. Diagram showing common forms of occlusion<sup>4</sup> A, B and C, as compared with D found in this case.

the unusual shape was due to the fact that the arteriogram was done at an early stage in the development of the occlusion.

The organic liver-disorder in this case may be coincidental. It is interesting, however, to conjecture the possibility of an aetiological relationship. There is evidence to suggest that the macromolecular syndrome in chronic malnutrition (Gillman and Gillman<sup>5</sup>), is associated with cardiovascular and other forms of

fibrosis. Fisher<sup>6</sup> considers that the commonest cause of thrombosis of the carotid artery is atherosclerosis. Syphilis must also be considered as a possible aetiological factor in this case, bearing in mind that liver cirrhosis is sometimes associated with a false positive serological reaction.

#### SUMMARY

A case of spontaneous thrombosis of the left internal carotid artery, diagnosed by angiography and associated with nutritional siderosis and cirrhosis of the liver, is described. Certain unusual features are discussed with reference to the literature.

We record our thanks to Dr. Disler, Superintendent of King Edward VIII Hospital for permission to publish this case; to Dr. I. C. MacEwan for confirmation of the ophthalmology, and to Prof. T. Gillman for the report on the liver biopsy and also for his constructive criticism.

#### REFERENCES

1. Moniz, E. (1937): *Presse méd.*, **45**, 977.
2. Ralph, L. L. (1954): *J. Fac. Radiol. (Lond.)*, **5**, 210.
3. Johnson, H. C. and Walker, A. E. (1951): *J. Neurosurg.*, **8**, 631.
4. Gurdjian, E. S. and Webster, J. E. (1953): *J. Amer. Med. Assoc.*, **151**, 541.
5. Gillman, J. and Gillman, T. (1950): *Perspectives in Human Malnutrition*, p. 490. New York: Grune and Stratton.
6. Fisher, M. (1951): *Arch. Neurol. Psychiat.*, **65**, 346.