

# CERVICAL INCOMPETENCE AND SECOND TRIMESTER ABORTIONS\*

F. N. NESER, M.D. (RAND), M.R.C.O.G.,

*Assistant Gynaecologist and Obstetrician, Department of Gynaecology and Obstetrics, University of Pretoria*

The recognition of cervical incompetence as a cause of some second-trimester abortions is generally accredited to Shirodkar<sup>1, 2</sup> and Lash and Lash.<sup>3</sup> Since the publication of their work the condition has excited considerable interest in Europe, America and Australia. In South Africa, however, it seems to have received scant attention.† In this article the available literature on the subject is reviewed and the experience gained in the management of 9 such cases is summarized.

Cervical incompetence is usually ascribed to previous trauma to the internal os of the cervix. It is suggested that this injury weakens the sphincteric action of the internal os to such an extent that it is unable to withstand the increasing intra-uterine pressure during pregnancy. The result is that a gradual and painless dilatation of the cervix takes place, terminating with an abortion at some time during the second trimester. Abortion is often preceded by sudden spontaneous rupture of the membranes, or by a watery discharge of liquor amnii for several days.

A more detailed picture of the condition can be obtained by considering the following points of interest which have been culled from the available literature.

## FROM THE LITERATURE

### *History*

A careful evaluation of the history of patients who have sustained second-trimester abortions is valuable. Cervical incompetence rarely manifests itself during a first pregnancy, but it should be noted that congenital weakness of the cervix

\* Paper presented at the 7th Interim Congress of the South African Society of Obstetricians and Gynaecologists (M.A.S.A.), Pretoria, August 1958.

† See, however, Adno, J. (1958): *S. Afr. Med. J.*, **32**, 1189, and Editorial (1958): *Ibid.*, **32**, 1079.

has been reported.<sup>4</sup> According to Barter *et al.*,<sup>5</sup> sudden loss of the amniotic fluid between the 16th and the 28th weeks of pregnancy, not preceded by painful contractions, is the most striking feature in the history.

A watery vaginal discharge may also precede abortion by several days. This occurs when the unruptured membranes bulge into the vagina; the discharge is thought to be due to the fact that the amniotic epithelium secretes liquor in both directions after the continuity of the chorion has been disrupted.

McDonald<sup>6</sup> noted that many patients complained of some lower abdominal discomfort before abortion occurred, while in a number of cases the feeling of a lump in the vagina, due to bulging of the sac of forewaters, was the presenting symptom.

A history suggestive of previous trauma to the cervix is nearly always obtainable, and the following types of injury have been held culpable by various authors: Curettage after abortion, attempts at criminal abortion, overzealous dilatation and curettage for dysmenorrhoea or for diagnostic purposes, deep lacerations from a previous delivery, precipitate labour, traumatic forceps delivery, extraction of shoulders through a constriction ring, Dührssen's incisions, amputation of the cervix, vaginal hysterotomy or Caesarean section, and abdominal lower-uterine-segment Caesarean section or hysterotomy.

An important point in the history of these cases which has not been previously stressed, is that in late cases the foetus is nearly always born alive, and that in earlier cases the products of conception are fresh. The delivery of a dead or macerated foetus, or products of conception which are obviously not fresh, is strongly against cervical incompetence as the cause of abortion.

### Clinical Findings

An almost unequivocal diagnosis of cervical incompetence can be made if a speculum examination of the patient is done when abortion is impending. In these cases the cervix is found to be well effaced and partially dilated. The intact bag of forewaters is seen to bulge into the vagina without tension (Fig. 1), and it can easily be reduced by gentle pressure

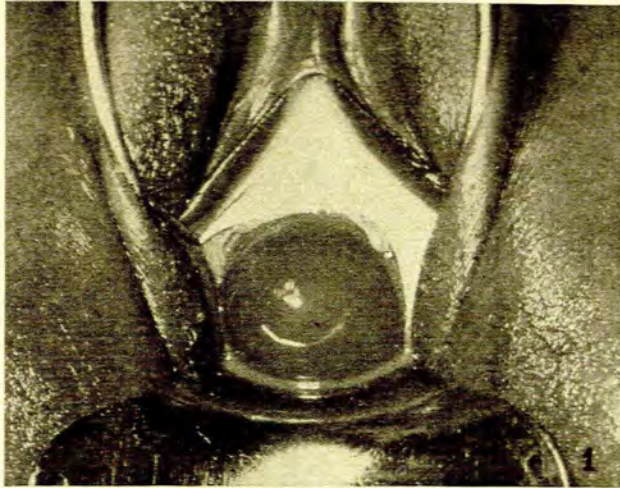


Fig. 1. Showing the intact bag of forewaters bulging into the vagina.

from a wet sponge. Glistening areas in which the amniotic epithelium has been exposed by denudation of the chorion, are often visible, and in this event a watery vaginal discharge is invariably present. The uterus is soft and contractions are not often detected before the membranes have ruptured.

In the non-pregnant state, extensive lacerations resulting in a patulous type of cervical canal may be found. More often, however, the cervix appears to be normal. The diagnosis may be suspected if a uterine sound passes without resistance through the internal os; and if the sound can be moved from side to side throughout the entire length of the cervical canal the competence of the cervix is very much suspect indeed. According to Johnstone,<sup>7</sup> the fact that an 8 mm. dilator can be passed without resistance is also very suggestive.

### Special Investigations

In 1953 Rubovits *et al.*<sup>8</sup> suggested that a definitive diagnosis could be made radiologically. Two techniques were employed. In one, a rubber balloon filled with a radio-opaque medium was introduced into the uterine cavity. X-ray pictures were then obtained while traction was applied to the balloon. In normal cases it could not be pulled into the cervical canal, but in cases that were considered to have an incompetent cervix it could be shown to fill the abnormally dilated passage. The other technique used was that of hysterosalpingography. Normally the internal os grips the cannula firmly, so that the junction between the cervical canal and the uterine cavity is demarcated quite clearly. In the abnormal cases, however, it was found that this junction could no longer be clearly seen, and that the cervical canal filled with varying amounts of lipiodol, according to the degree of incompetence of the cervix.

Hunter *et al.*<sup>9</sup> made hystero-graphic studies of the uterus in cases of 2nd-trimester abortions, before and after the

cervical canal had been irrigated with solutions of bromelain and papain. By this method they attempted to define 3 types of incompetent cervix. If the initial hystero-gram showed an incompetent type of os, with no change after irrigation, the cervix was considered to be congenitally incompetent, and unlikely to respond to a repair operation. If, on the other hand, the initial X-ray examination revealed a competent cervix which became incompetent after irrigation with bromelain and papain, the cervix was considered to be physiologically incompetent, and more likely to respond to repair. When the initial hystero-gram revealed a localized defect of the cervical canal, structural incompetence was diagnosed, and these cases were found to be particularly suitable for repair operations.

### Treatment

The treatment in all cases has consisted of some attempt to repair or strengthen the internal os of the cervix.

Shirodkar<sup>1, 2</sup> inserted a fascia-lata suture around the cervix at the level of the internal os, in pregnant and non-pregnant women, while Barter *et al.*<sup>5</sup> used a similar technique in non-pregnant women only. A purse-string type of suture of non-absorbable material, inserted approximately at the level of the internal os during pregnancy, was employed by Johnstone<sup>7</sup> and McDonald.<sup>6</sup>

Operative repair of cervical defects in the non-pregnant state was preferred by Baden,<sup>10</sup> Rubovits *et al.*<sup>8</sup> and Palmer<sup>4</sup> and Lacomme; and Lash and Lash,<sup>3</sup> who found that the injury or defect in the cervix could invariably be shown to be situated anteriorly, have advocated a rather extensive type of repair operation.

### Results of Treatment

A summary of the various types of treatment so far employed, and the results obtained, is given in Table I. It

TABLE I. SUMMARY OF TREATMENT OF CERVICAL INCOMPETENCE REPORTED IN THE LITERATURE

Author	No. of Cases Treated	Method of Treatment	No. of Successes
Barter <i>et al.</i> <sup>5</sup>	22	Cervix repaired with fascia lata at level of internal os	14
McDonald <sup>6</sup>	70	Silk purse-string suture inserted when abortion threatened	33
Baden and Baden <sup>10</sup>	1	Trachelorrhaphy when membranes were bulging at 24 weeks	1
Rubovits <i>et al.</i> <sup>8</sup>	4	Trachelorrhaphy in non-pregnant state	3
Lash and Lash <sup>3</sup>	6	Repair in region of internal os in non-pregnant state	5
Johnstone <sup>7</sup>	3	Trachelorrhaphy just after abortion 1 case. Silk suture during pregnancy 2 cases	2
Palmer and Lacomme <sup>4</sup>	1	Trachelorrhaphy in non-pregnant state	1
Shirodkar <sup>2</sup>	43	Fascia-lata repair at level of internal os during pregnancy	34
Shirodkar <sup>1</sup>	56	Fascia-lata repair in non-pregnant state	45
Total	206		138 (67%)

is immediately apparent that the results are essentially similar, and that none of the methods appear to have any particular advantage over any of the others. In all, 206 cases have been treated, with 138 successes. The proportion of successes may not seem large, but it should be remembered that the patients were all women who had suffered so many consecutive miscarriages that they had begun to despair of ever having any more children.

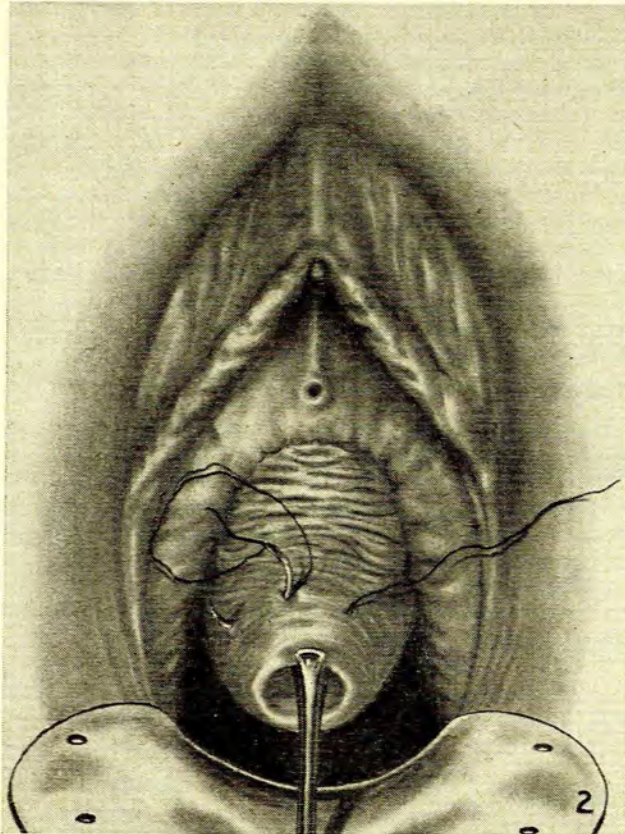


Fig. 2. For explanation see text.

#### REPORT ON 9 CASES

Nine women who were diagnosed as suffering from an incompetence of the cervix were encountered in the hospital and private practices of staff members of the Pretoria Hospital (Table II). These patients had sustained between 2 and 8 consecutive 2nd-trimester abortions before being treated. Amongst them they had 56 pregnancies, which resulted in the birth of only 12 viable infants.

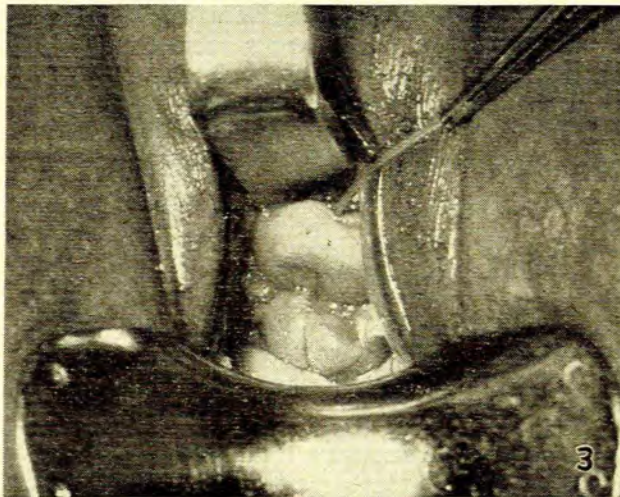


Fig. 3. Showing the same patient as in Fig. 1 after the suture had been inserted.

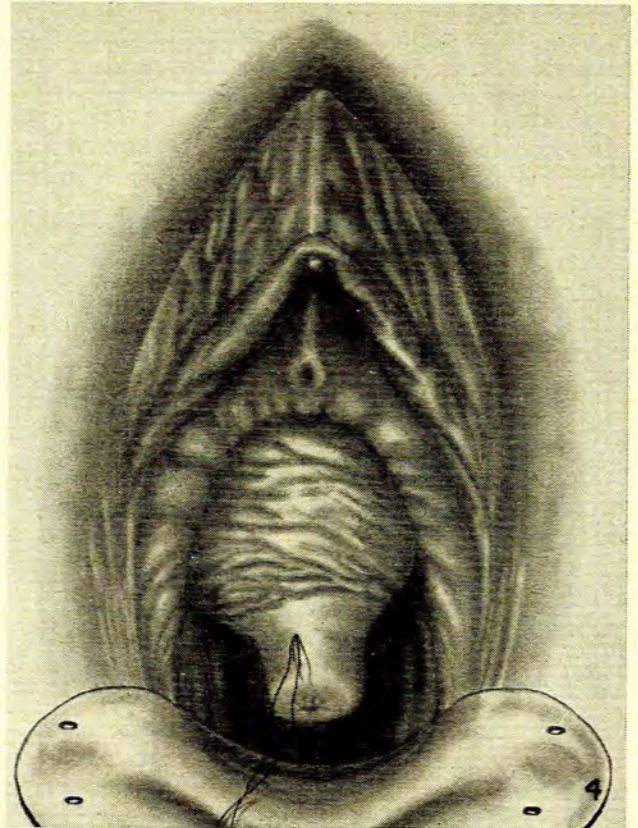


Fig. 4. For explanation see text.

In 7 cases the women were seen for the first time during pregnancy, and the diagnosis was made on the previous history and the appearance of the cervix at the time of examination. Two patients were seen when they were threatening to abort, and in these cases the diagnosis was established by the finding of a well-effaced and partially dilated cervix, with bulging membranes, in the absence of uterine contractions.

#### Treatment

In all but one case the treatment consisted of the insertion of a non-absorbable purse-string type of suture into the cervix at about the level of the internal os during pregnancy. In the remaining case a similar suture of No. 3 chromic catgut was used.

The technique is extremely simple (Fig. 2). The cervix, having been grasped with a vulsellum, or any other suitable type of forceps, is pulled gently downwards. A small incision through the skin is made at the level where the smooth epithelium of the cervix ends and the rugosities of the vagina begin. This point corresponds more or less with the level of the internal cervical os. The point of a needle carrying a No. 3 silk suture is inserted through the incision, and brought out as far laterally as possible. The needle is reinserted at the point of exit, and again brought out at some distance from the point of insertion. In this way, after 4-5 bites have been taken, and the needle has eventually emerged again through the original site of entry, the cervix is surrounded at the level of the internal os by a purse-string type

of suture. The depth at which the suture is placed should not exceed 2-3 mm.

Once the suture has been inserted it is pulled fairly tight and knotted. The degree of tension which can be applied with safety is a matter of experience, but if a uterine sound can afterwards be passed through the cervical canal without obstruction there need be no fear that the tension will be so great as to cause necrosis. The ends of the suture are left long so that they can easily be found later, when they have to be divided (Figs. 3 and 4).

A point of practical importance, emphasized by McDonald,<sup>6</sup> is that particular care should be taken to insert the suture firmly in the posterior aspect of the cervix. It is at this point that it tends to tear out, if it does so at all.

After the operation the patients were kept in bed for 4-5 days. During this period painful uterine contractions often occurred, but they disappeared in all cases within 48-72 hours. The suture seemed to be well tolerated, and the manipulations to the cervix did not lead to immediate abortion in any case.

On being discharged from hospital the women were told to avoid all strenuous activities, but apart from this no special precautions were taken.

Nine patients who were thought to be suffering from cervical incompetence were treated in this way; the results are summarized in Table II. No particular stage of preg-

TABLE II. SUMMARY OF 9 CASES OF CERVICAL INCOMPETENCE TREATED AT PRETORIA HOSPITAL

Case	No. of Previous Pregnancies	No. of Viable Children	Treatment	Outcome
1 M.D.V.	2	0	Nylon purse-string suture at 24 weeks. Progesterone implant	Aborted at 28 weeks
2 M.M.	13	2	Silk purse-string suture at 8 weeks. Reinserted at 18 weeks	Aborted prem. twins at 28 weeks. Fundus size of 34 weeks
3 L.J.S.	8	0	Silk purse-string suture at 16 weeks. Primolut depot 125 mg. weekly	Delivered live child at 37 weeks
4 M.C.D.	6	4	Silk purse-string suture at 16 weeks	Delivered live infant at 38 weeks
5 G.B.	3	1	Silk suture at 12 weeks. Reinserted at 16 weeks. Primolut depot 125 mg. weekly.	Prem. twins born at 30 weeks. One survived. Uterus enlarged to 36 weeks
6 M.A.	8	1	Silk suture at 10 weeks. Primolut depot 125 mg. weekly for 20 weeks	Live child born at 37 weeks
7 G.M.	5	1	No. 3 chromic catgut suture inserted at 15 weeks when membranes were bulging	Aborted 12 days later when chromic suture snapped
8 J.E.L.	5	0	Silk suture inserted at 15 weeks	Aborted at 24 weeks
9 C.E.M.	6	3	Silk suture inserted at 14 weeks. Progesterone implant	Aborted at 26 weeks
Total	56	12		

nancy was selected for the operation, the suture being inserted as soon as the diagnosis had been made. Of the 9 patients treated only 4 were eventually delivered of infants which survived. The number of successes is disappointing when compared with the results which have been published by other authors, but the series is so small that no real significance can be attached to this figure. Furthermore it is possible that 2 of the recorded failures may well have carried to term but for unforeseen circumstances. In case 7 a chromic catgut suture was unfortunately inserted into the cervix. When the gut gave way 12 days later the patient aborted almost immediately. Had a silk suture been used instead, it is possible that the pregnancy might have continued until

the foetus had become viable. Case 2 turned out to have a twin pregnancy. When the fundus had enlarged to the size of a 34-week pregnancy, the suture tore out and the patient aborted. A single foetus in this case might well have been retained long enough to have become viable.

It will be noted that some form of progesterone therapy was employed in many cases as well, and this makes it difficult to assess the true value of the sutures which were inserted. It can only be emphasized that they had all received progesterone therapy during previous unsuccessful pregnancies.

The following brief description of 3 cases illustrates the difficulties which may be encountered in the treatment of these patients:

#### Case 6

Mrs. M.A., aged 33 years, was seen for the first time when 14 weeks pregnant. She had suffered from 6 previous abortions, all between the 16th and 28th weeks of pregnancy. When seen again 4 weeks later, she complained of a watery vaginal discharge. A speculum examination showed the cervix to be 3-fingers dilated, with the membranes bulging into the vagina, in the absence of uterine contractions.

The patient was immediately hospitalized and after the bulging membranes had been reduced, a silk purse-string suture was placed around the cervix. She suffered from sporadic uterine contractions for a few days thereafter, but soon settled down. Ten days later, however, such violent contractions developed that the suture had to be divided, and she aborted almost immediately afterwards.

She was seen again a year later (March 1957) and found to be 8 weeks pregnant. Fourteen days later another purse-string suture was placed around the cervix, and she was discharged on the 10th post-operative day. Weekly injections of depot progesterone were administered until the 30th week of pregnancy. Gestation continued uneventfully until the 37th week, when the membranes ruptured spontaneously. The silk suture was immediately removed, and a live infant weighing 6 lb. 6 oz. was born 12 hours later.

#### Case 5

Mrs. G.B., aged 22 years, underwent a lower-uterine-segment Caesarean section after a failed forceps operation in May 1954.

She became pregnant again a year later. The pregnancy proceeded uneventfully until the 26th week, when the membranes ruptured spontaneously. A premature infant weighing 2 lb. was born 11 hours later and died after 18 hours.

Ten months later she was again pregnant. The pregnancy ended at 18 weeks with an almost painless abortion. At a subsequent examination after 6 weeks, it was found that a uterine sound could be moved from side to side throughout the entire length of the cervical canal. Cervical incompetence was suspected, and the patient was asked to return later for hystero-graphy.

When seen again in June 1957 she was about 12 weeks pregnant. She was immediately hospitalized, and a silk purse-string suture was placed around the cervix on the following day. Slight vaginal bleeding persisted post-operatively and, a month later, speculum examination revealed that the suture had torn out posteriorly. The old suture was removed, and another inserted. Subsequent rapid enlargement of the uterus suggested the possibility of a twin pregnancy or hydramnios. When the pregnancy had advanced to 30 weeks, and the uterus had reached the size of a 36-week pregnancy, strong contractions ensued, and the suture had to be removed. Premature twins weighing 2 lb. 6 oz. and 2 lb. 12 oz. were born 1½ hours later. The smaller infant died after 10 hours but the other survived.

#### Case 7

Mrs. G.M., aged 31 years, was first seen in September 1955, when approximately 8 weeks pregnant. She had one child, 7 years old, as a result of a normal confinement in 1948. Subsequently she had 4 consecutive abortions between the 14th and 16th weeks of pregnancy. In all cases the abortion was preceded by a watery vaginal discharge, followed by painless rupture of the membranes 3-4 days later.

When the present pregnancy had advanced to about 15 weeks,

the patient complained that she again had a watery vaginal discharge. Speculum examination showed the cervix to be approximately 2 cm. dilated and well effaced. The membranes were bulging through the opening, and a few small areas where the chorion had been denuded, thus exposing the glistening amnion, were observed. She was immediately hospitalized, and a No. 3 chromic catgut purse-string suture was placed around the cervix. The post-operative course was uneventful, and the patient was discharged on the 7th day. On the 12th post-operative day, however, she aborted suddenly. Subsequent speculum examination revealed the broken chromic suture, still adherent to the anterior lip of the cervix.

#### DISCUSSION

At this stage it is pertinent to ask whether cervical incontinence really exists as an entity, and it must be admitted that this has by no means been conclusively demonstrated. The syndrome has been described by a number of authors; but enthusiasts are sometimes carried away by their own enthusiasm, and their energy often serves to convert others to their point of view.

In the first place, X-ray photographs purporting to demonstrate incompetence or structural abnormalities of the internal os are hardly convincing. I have seen a number of cases where hystero-grams which were obtained for other purposes showed apparent incompetence of the internal cervical os. Yet none of these women had shown any tendency to repeated abortions.

Secondly, it can easily be demonstrated that a uterine sound can be moved from side to side in the cervical canal of many multiparous women who have never had a miscarriage. Nevertheless, the results of treatments which have been published to date do suggest that some sort of cervical syndrome must exist. Furthermore, to anyone who has had an opportunity of examining a case of this nature during the process of abortion, the bulging of the membranes through the effaced cervix, in the absence of detectable uterine contractions, must seem significant. In the present state of our knowledge, however, it is not easy to decide whether the tendency to abortion is actually due to a weakness of the cervix or, perhaps, to an incoordination between its function and that of the uterine body which we are as yet unable to detect.

In the final analysis the problem is a diagnostic one. If all women who have had previous abortions were treated for cervical incompetence, the results of the treatment would naturally appear to be very favourable. If, on the other hand, only those patients who are thought to be suffering from cervical incompetence were treated, poor selection, due to inaccurate diagnosis, would lead to very inferior results and unfair condemnation of the method.

In my opinion, therefore, until more accurate diagnostic methods have been devised, only those patients in whom the cervix can be seen to be giving way should be treated as cases of cervical incompetence. By adopting this attitude we shall be better able to assess the efficacy of treatment and the validity of the diagnosis of cervical incompetence. It is suggested that all women who are suspected to be suffering from cervical incompetence should have a speculum examination at weekly intervals, and that only those patients in whom progressive effacement and dilatation of the cervix occurs should be accepted for operation. This attitude has been adopted by McDonald,<sup>6</sup> and it is probable that his series of cases is the only one to date which represents the true picture of the condition (Table I).

An interesting objection to the theory of incompetence of the internal cervical os was offered by Danforth, when commenting on a paper by Rubovits *et al.*<sup>8</sup> He alluded to the accepted theory that the upper portion of the cervix normally becomes incorporated into the uterine body during pregnancy, to form the lower uterine segment. Recent studies by de la Harpe<sup>12</sup> have confirmed this theory, and it would seem that incompetence of the internal os can play no part in the abortion syndrome under discussion. If, therefore, cervical incompetence does exist as an entity, it must be conceived of as an incompetence or weakness of the cervix as a whole, and not merely as incompetence of the internal os alone. The finding that many women in whom a portion of the cervix has been amputated tend to have repeated abortions<sup>11</sup> also suggests that competence of the internal os is not of cardinal importance in this respect and, incidentally, casts doubt upon the validity of hystero-grams which purport to demonstrate incompetence of the internal cervical os.

In the present state of our knowledge there would seem to be little to be gained from classifying cases under the headings congenital, physiological, traumatic, or anatomical. A great deal of basic research into the physiology of uterine action and its effect on the cervix is needed before a realistic classification can be attempted. Gradual dilatation of the cervix during pregnancy could, for instance, equally well be due to an inherent or acquired resistance of the uterine musculature to stretching, as to a weakness of the cervix. In this connection the work of Hunter *et al.*<sup>9</sup> is most stimulating, and further studies along these lines seem to offer some hope of clarifying the problem.

A number of treatments has been devised to combat or cure cervical incompetence. Roughly, they can be divided into those which seek to obtain a permanent cure, and those which aim only at temporary alleviation of the condition. The operations which have been designed to cure the condition permanently are open to criticism on several grounds. In the first place the procedures are usually fairly radical and, in the pregnant patient, may in themselves be sufficient to induce uterine contractions. Secondly, the scar tissue formed as a result of the operation may result in an inability of the cervix to dilate so that Caesarean section is a common sequel. If, on the other hand, normal labour should occur, stretching of the scar tissue may result in re-establishment of the state of incompetence.

Procedures which aim at supporting the cervical canal temporarily have been shown to be as effective as any other measures and they are not associated with any of these disadvantages. The insertion of a purse-string suture consisting of some inert material such as silk or nylon around the cervix, is a simple procedure. It causes very little local or general disturbance, and can be repeated without harm as often as is necessary during the same or subsequent pregnancies. It can be removed quite easily before or during labour, and there need be no fear of sufficient fibrosis to cause a degree of cervical stenosis necessitating Caesarean section.

I am, therefore, convinced that simple suturing of the cervix is the method of choice for most cases, and that, at present, it should only be employed in those patients in whom progressive dilatation of the cervix has been observed during pregnancy.

## SUMMARY

Attention is drawn to the possibility that cervical incompetence may be a cause of a number of 2nd trimester abortions.

The literature on the condition is reviewed, and the results of the treatment of 9 cases is recorded.

A plea is made for the use of simple suturing of the cervix, instead of the more elaborate operations which have been described, and it is suggested that treatment should be confined to those cases in whom cervical incompetence can be demonstrated during pregnancy.

Thanks are due to Prof. F. G. Geldenhuis and Dr. F. W.

van der Westhuizen for permission to publish cases under their care, and also to Mr. E. J. Waanders for his excellent illustrations.

## REFERENCES

1. Shirodkar, V. N. Quoted by Lewis, T. L. T. (1956): *Progress in Clinical Obstetrics and Gynaecology*, p. 428. London: Churchill.
2. *Idem.* Quoted by Barter *et al.*, *loc. cit.*<sup>3</sup>
3. Lash, A. F. and Lash, S. R. (1950): *Amer. J. Obstet. Gynec.*, 59, 68.
4. Palmer, R. and Lacomme, M. (1950): *Rev. franç. Gynec.*, 45, 218.
5. Barter, R. H., Dusbabek, J. A., Riva, H. L. and Parks, J. (1958): *Amer. J. Obstet. Gynec.*, 75, 511.
6. McDonald, I. A. (1957): *J. Obstet. Gynaec. Brit. Emp.*, 64, 346.
7. Johnstone, J. W. (1958): *Ibid.*, 65, 208.
8. Rubovits, F. E., Cooperman, N. R. and Lash, A. F. (1953): *Amer. J. Obstet. Gynec.*, 66, 269.
9. Hunter, R. G. and Civin, W. H. (1957): *Ibid.*, 73, 875.
10. Baden, W. F. and Baden, E. E. (1957): *Ibid.*, 74, 241.
11. Fisher, J. J. (1951): *Ibid.*, 62, 644.
12. De la Harpe, M. M. Personal communication.