

## POISON IVY DERMATITIS: THE FIRST SOUTH AFRICAN CASES\*

C. M. ROSS, M.B., CH.B., M.R.C.P., F.R.F.P.S.

*Dermatologist, Boksburg-Benoni Hospital, Far East Rand Hospital and No. 1 Military Hospital, Voortrekkerhoogte*

This is the story of a mistake in diagnosis, in fact of many mistakes. It begins in 1956 and has, I hope, now ended. Within these 3 years it has led to the appearance of not less than 8 cases of a self-limited but severe dermatitis. In the first 6 instances this was recognized only as an unusual external contact reaction; the cause was not determined. By good fortune, case 7—Mrs. A.P.—recalled clearly that her symptoms began after she had helped her husband to cut down their garden hedge. She stated further that her 3 children and her husband had, in the past, been similarly affected. The hedge contained hawthorn, youngberry, and an ivy creeper. She was patch-tested to the leaves of all three and gave a positive reaction to the last. Despite the fact that poison ivy had never before been recognized in the Union, my suspicions were aroused, and I sent the specimen, accompanied by a note suggesting its possible nature, to the Division of Botany of the Department of Agriculture. Their answer dispelled any doubts I might have entertained. Case 8 occurred in the young Native boy who was given the job of destroying and removing the remainder of the hedge.

Poison ivy (*Rhus radicans* Linn.) is a member of the anacardiaceae or cashew family. It is described by Meunier<sup>1</sup> as a woody stemmed erect shrub or vine, climbing by aerial rootlets on fences, walls or trees. It has slender creeping rootstocks which arise from its basal stem nodes and may run horizontally underground for several yards, sending up short leafy shoots from its nodes. Its leaves are alternate and compound with 3 leaflets. The leaflets are glossy or dull green and glabrous or somewhat hairy, with margins entire, toothed or somewhat lobed (Fig. 1). The flowers are polygamous in slender, open, axillary panicles. The calyx is 5-lobed and there is a corolla of 5 yellow-green petals, 5 separate stamens, a solitary pistil, and a 1-celled ovary. The fruit is a small white or cream-coloured, almost dry, nearly globular drupe, about 4-6 mm. in diameter, with a greyish striped 1-seeded stone about 3-4 mm. in diameter.

The plant is widespread throughout the USA and Southern Canada, where it is found in dry rocky fields, pastures, fence rows, banks, waste places and rich alluvial woodlands. It appears to have been introduced into Olifantsfontein, where the cases occurred, about the year 1950, but it has not been possible to discover precisely whence it came, for the several families who in turn occupied the house where the original plant grows have now moved away and many of their members have died. It says much for the hardiness of the plant that the original cutting took and still flourishes. Fig. 2 shows its precarious foothold in a tiny opening cut

\* A paper read at the National Meeting of the Dermatological Group (M.A.S.A.) on 29 March, 1959.

in the concrete of a south-facing stoep. From there it was passed as slips to at least 4 of the gardens in the neighbourhood, in 3 of which it luxuriates. As far as I know, it has not yet found its way elsewhere, but gardeners are generous people and cuttings from so strongly growing a plant may easily have been given to others and for the moment have been forgotten. Natural spread may also have taken place.

The initial attack of ivy dermatitis (Sutton *et al.*<sup>2</sup>), which sensitizes, differs from subsequent attacks occurring after sensitization. The first outbreak is likely to manifest itself as a crusted exudative painful lesion from primary irritation—a lesion, sterile on culture, which resists all kinds of treatment and remains practically unchanged for several days. Once sensitization has developed, swelling and vesiculation make their appearance at distant sites where relatively low concentrations of antigen have reached the skin—concentrations too low to serve as primary irritants, but ample to evoke a reaction when an allergic state exists.


In subsequent attacks, the symptoms begin typically upon the backs of the fingers, in the interdigital spaces and on the eyelids, although they may begin on the ankles or other parts which have been exposed through thin clothing. The lesions are vesicular, usually grouped, and often linear. The eyelids are puffy, being worse in the morning and better in the evening, when the swelling is dissipated by the movement of the facial muscles. The dermatitis is transmitted to other parts, especially the forearms and the male genitals, which become greatly swollen. Although on occasion incubation periods ranging from 6 hours to 12 days have been reported, a period of about 36 hours usually elapses from the time of exposure until the onset of symptoms, and from then they develop to reach a maximum in 5 days. Then a more or less abrupt crisis takes place in the uncomplicated case and the patient, miserable as he has been, knows that he is making a change for the better. Roughly 3 weeks more are then required for the skin to revert to normal, but this healing time is naturally dependent on the intensity of the dermatitis and upon the degree of sensitivity.

The cases seen here have scarcely been so dramatic. The first, V.C. aged 8, came to me in September 1956. He then had no lesions whatever, but his mother stated that during the preceding 2 months he had had several transient attacks of swelling of his ears, lips and eyes which had subsided in 4 or 5 days. This child is a keen cricketer, and it is now obvious that he developed his symptoms through poking his head into the plant growing in his garden (Fig. 3) when looking for his cricket ball. T.P., aged 13, and A.P., aged 11, who were seen by Dr. Findlay in January 1957, live across the road from him and frequently joined with him in games.

When Dr. Findlay examined them, he found T.P. to have an acute swelling and eczema of the face, with a punctate urticarial rash associated with scratch marks on the arms, and a punctate morbilliform rash on the neck and upper chest. A.P. showed a scratch on the left side of the face with oedema and eczema in the surrounding area. Their father, Mr. P., had a haemorrhagic rash on his arms, and it is likely that he

had again been busy on his hedge. Their sister A.M.P., aged 5, became a patient of mine in October 1957, when she had a diffuse erythema and swelling of the right cheek which made me think of erysipelas; 6 days later it had cleared from the face to leave some crusting around the nostrils and on the cheek, but had produced papulo-vesicles on the palms and wrists and eczematoid patches on the chest. The 6th case, Mrs. D., aged 50, sought advice in January 1958 for erythematous patches studded with scratched papules which were situated on her left cheek, in front of her left ear and on the right of her nose. When I examined case 7, Mrs. A.P., aged 49, the patient whose history led to the unravelling of the mystery, she had what I thought to be a non-specific contact reaction on her buttocks, upper thighs and natal cleft. The areas were red and there was some scaling and papulation but, as exposure had taken place 2 weeks earlier, her symptoms were obviously subsiding. Curiously enough she had not handled the plant but had brought a cup of tea to her husband who was working on their hedge; and after lifting her frock had sat down on the cut foliage; hence the peculiar distribution.

It is this odd distribution which calls to mind the case reports of the trouble which has befallen sensitized Americans abroad who have developed dermatitis in countries where poison ivy itself is unknown through contact with other dermatitis-producing anacardiaceae. Cases have been described of their soldiers getting dermatitis of the buttocks in Japan through sitting on toilet seats finished in Japanese lacquer derived from *Rhus verniciflua*, and in the tropics of rashes on other parts of the body from laundry marked with juices of the *Samecarpus anacardium*, or Indian ink tree. (When this tree is cut a milky sap exudes, which darkens and is then used in the manufacture of these marking substances.) In our country they would obviously be most likely to come into contact with mangoes, *Mangifera indica*, or with the products of the cashew-nut tree, *Anacardium occidentale*. In the new edition of his book on the Medicinal and Poisonous plants of Southern Africa, which is soon to be published, Professor Watt<sup>3</sup> states that although the seed kernel of the cashew-nut is edible it is actually poisonous unless roasted till all the pericarp oil has exuded. The fumes which come off during this process are exceedingly irritant. The oily juice is dark brown or almost black in colour and is acrid and irritant to the skin, causing swelling, vesiculation and even



Figs. 1, 2 and 3. Poison ivy (*Rhus radicans*).

acute dermatitis. The husk or shell likewise produces a contact dermatitis. The tar from the bark is vesicant and the brown oily juice which exudes on warming a fresh surface of the nut is used as a topical irritant by African herbalists. In Tanganyika, the juice is used for making scars, keloids and tribal marks. In Europe, dock workers have developed 'vanilla itch' due to the fact that cardole, extracted from the juice, is painted on the pods to give them a bright brown shiny appearance.

The Pretoria Botanical Garden contains several specimens of *Heeria argentea* (Thunb.) Meisn., an indigenous shrub-like member of the anacardiaceae which has been reported as causing severe dermatitis amongst Natives in Pondoland. However, the curator tells me that, though he usually mentions this effect to visitors and though many people have handled the plant, no reaction to it has yet occurred.

The fact that the American population, as estimated by random samples, is sensitized to an extent of over 50% to poison ivy makes it not unlikely that in the near future one of the many visitors we have from America will come into contact with one of these related irritants, and will develop a cross sensitization. Fortunately, cross reactions are weaker and can normally only be elicited in those whose primary sensitivity is extreme. If it were not so, even calamine lotion, through its phenol content, could conceivably be hazardous for the poison-ivy sensitive person and could act as a secondary allergen.

#### DESENSITIZATION AND TREATMENT

In the following section I have freely borrowed from Kligman's excellent article.<sup>4</sup>

The antigenic composition of the related irritant species is precisely known and, expressed in general terms, all the antigens are phenols, catechols or resorcinols, with a 15-carbon-atom chain, usually unsaturated, in a position meta to one of the hydroxyl radicals. The saturated component (hydro-urushiol) illustrates the general structure (Fig. 4). The position of the carbon atom is important and dihydric phenols such as adrenaline and dihydroxyphenylalanine which occur in the body and which have the atom in the 4 position do not produce cross reactions.

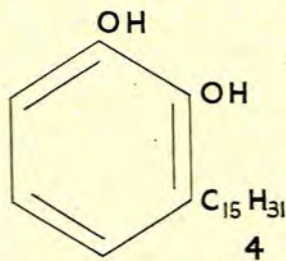


Fig. 4. Hydro-urushiol (3-pentadecyl catechol).

The plant allergens are contained in the sap, which is distributed to the roots, stems, leaves and fruit by resin canals. The canals do not connect with the surface and it is necessary<sup>5</sup> for contact to be made with a bruised leaf before dermatitis will follow. Uninjured leaves are completely innocuous. Sensitization occurs easily and from casual contact with the plants. Mere traces of allergen are

sufficient and it is probably unwise to assume resistance to sensitization in anyone. Fortunately, a spontaneous decline in sensitivity occurs with increasing age, and fresh antigenic stimulations of a moderate kind through further contact with the ivy do not ordinarily revive a waning or lost sensitivity, nor do they act as booster doses. Relative refractoriness to further exposure following a severe attack, though reported, is uncommon. The prevention, or blocking of the

development of, sensitivity has interested many observers. When Chase<sup>6</sup> and Sulzberger<sup>7</sup> inhibited the development of sensitization in guinea-pigs to 2, 4-dinitrochlorobenzene and arspenamine by prior feeding and intracardiac injection, respectively, it was hoped that this phenomenon would be applicable to poison ivy. Kligman, however, was unable to produce any degree of blocking by giving pentadecylcatechol either orally or intramuscularly to mentally defective children, previously unexposed, before exposing them to surface contact with crushed leaves. He stresses, however, that his studies in this important aspect of the problem have not gone far, and further investigation will be required into the question of total dosage, spacing of doses, absorption of antigen, route of administration, etc. When testing for sensitivity, delayed reactions should not be overlooked; Shelmire<sup>8</sup> has said they may occur even up to 11 days after the test. In sensitized persons, when high concentrations of pentadecylcatechol are introduced into the mouth a severe stomatitis follows and, when given in capsules, a pruritus ani. When injected intramuscularly there may be fever, malaise and other constitutional symptoms, and therefore Kligman proposes that there is biologically a state of generalized or systemic allergy, though under the usual clinical circumstances the potential of other tissues to react does not become manifest. In exceptional cases, however, reactions have been reported such as leucocytosis, eosinophilia, tissue eosinophilia, glomerulonephritis (presumably due to secondary bacterial infection of the widespread dermatitis), id reactions in the shape of erythematous, macular and papular rashes (compare the case T.P.), palmar dyshidrosis, and pigmentary changes.

External prophylaxis, through attempts to remove the allergen within 5 minutes of exposure by washing with soap or with acetone and ether in equal parts, is of little value in highly sensitive persons, though it seems to have some merit in the mildly sensitive if done before 1 hour elapses. Penetration or fixation of the antigen in the skin therefore appears to occur with great rapidity. Water-resisting and oil-resisting barrier creams and petroleum jelly (which was used as a control) offered no practical degree of protection in sensitive subjects against the effects of contact with freshly crushed leaves. Detoxicants and local complexing and chelating compounds were likewise ineffective, probably because of the rapidity with which penetration takes place.

As topical therapy nothing surpasses simple compresses and non-medicated shake lotions and creams. Local steroids, in all the variety of forms now available and regardless of the frequency of application, do not appear to have any moderating effect even when treatment is begun within 10 minutes of the application of the allergen. Parenteral steroids are another matter. Dr. Findlay treated the patient T.P. with ACTH gel, and I felt that one of my cases was rapidly improved with oral meticorten. Kligman strongly advocates the parenteral use of steroids, but dismisses as valueless antihistaminics and all other oral and parenteral medications.

Phylactic treatment by the administration of ivy extracts during the acute phase, which at one time was thought to be valuable,<sup>8, 9</sup> is not only useless but dangerous<sup>10, 11</sup> and when given may produce a systemic reaction comparable to that previously described.

It will thus be seen that this plant, despite its beauty, is the source of a great deal of discomfort and distress. It has worried the Americans for over 300 years and as early as

1610 Captain John Smith,<sup>12</sup> that interesting adventurer, the man for whose life the Indian princess Pocahontas pleaded, reported cases in his men. It is now the commonest cause of allergic contact dermatitis in America. This being so, it is hoped that this paper will lead to the seeking out and destruction of all specimens that have taken root in the Union and will thus contribute, to the prevention of disease here.

#### SUMMARY

The paper describes what are believed to be the first cases of dermatitis due to contact with poison ivy that have been recognized in the Union.

The nature of the allergen responsible and the treatment of the condition are briefly discussed.

A strong recommendation is made that all specimens of the plant growing in this country should be uprooted and destroyed.

#### OPSOMMING

Die artikel beskryf wat beskou word as die eerste gevalle van dermatitis, as gevolg van kontak met 'Poison Ivy', wat in die Unie voorgekom het.

Die aard van die allergeen wat verantwoordelik is, en die behandeling van die toestand word kortliks bespreek.

Dit word ten sterkste aanbeveel dat alle 'Poison Ivy'-plante in die land vernietig word.

I wish to acknowledge my gratitude to the Division of Botany of the Department of Agriculture, to Prof. D. G. Steyn, of Pretoria, and to Prof. J. M. Watt, of Johannesburg, for advice and assistance in preparing this paper; and to Dr. I. Kopman, of Olifantsfontein, and Dr. G. H. Findlay, of Pretoria, for allowing me to use material relevant to some of the cases.

#### REFERENCES

1. Meunscher, W. C. (1951): *Poisonous Plants of the United States*. New York: Macmillan Co.
2. Sutton, R. L. (1956): *Diseases of the Skin*. St. Louis: C. V. Mosby Co.
3. Watt, J. M., and Breyer-Brandwyk, M. G.: *The Medicinal and Poisonous Plants of Southern Africa*, 2nd ed. In preparation.
4. Kligman, A. M. (1958): *AMA Arch. Derm.*, 77, 149.
5. Shelmire, B. S. (1939): *J. Amer. Med. Assoc.*, 1134, 1085.
6. Chase, M. W. (1946): *Proc. Soc. Exp. Biol. (N.Y.)*, 61, 257.
7. Sulzberger, M.B. (1929): *Arch. Derm. Syph.*, 20, 669.
8. Strickler, A. (1921): *J. Amer. Med. Assoc.*, 77, 910.
9. *Amer. Derm. Assoc., Annual Meeting (1925): Arch. Derm. Syph.*, 12, 888.
10. Goldman, L. (1939): *J. Med.*, 20, 294.
11. Howell, J. B. (1947): *Ann. Allergy*, 5, 219.
12. Smith, J. (Captain John Smith) (1624): *The General History of Virginia, New England and the Summer Isles*, Book 5, p. 172. From Pinkerton, J. (1812): *A General Collection of the Best and Most Interesting Voyages and Travels in all Parts of the World*, London: Longman, Hurst, Rees, Orme and Brown, and Caddell and Davies.