

# Suid-Afrikaanse Tydskrif vir Geneeskunde South African Medical Journal

Posbus 643, Kaapstad

P.O. Box 643, Cape Town

Kaapstad, 16 November 1957  
Weekliks 2s. 6d.

Vol. 31 No. 46

Cape Town, 16 November 1957  
Weekly 2s. 6d.

## ISOLATED CONGENITAL PULMONARY INCOMPETENCE

N. SEGEL, B. VAN LINGEN, V. RESNEKOV and M. MCGREGOR

*From the Cardio-Pulmonary Research Unit of the Council for Scientific and Industrial Research and the Department of Medicine of the University of the Witwatersrand Medical School, and the Johannesburg Hospital Department of Radiology*

Pulmonary incompetence is common as an acquired lesion. It may follow pulmonary artery dilatation due to pulmonary hypertension or be caused by damage to the valve cusps by surgery, bacterial endocarditis, rheumatic fever or syphilis. As an isolated congenital anomaly, however, it is extremely rare and may be the result of either idiopathic dilatation of the pulmonary artery or congenital abnormalities of the

valve cusps. The case to be reported is considered to be another example of the isolated congenital lesion.

### CASE REPORT

A 7-year old boy was admitted to the Cardiac Clinic (Johannesburg General Hospital), for investigation of a cardiac murmur which had been discovered on routine examination some 3 years earlier. He was perfectly well in all respects and had no symptoms. Clinical examination revealed a normally developed young patient; pulse rate 88/min; blood pressure 100/60 mm. Hg; venous pressure normal; no clubbing or cyanosis. The cardiac impulse was unremarkable except for a marked systolic thrust with a short thrill palpable in the pulmonic region. The first heart sound at the mitral area was moderately accentuated where there was a Grade 2 high-pitched blowing systolic murmur. In the pulmonic region the second heart sound was normally split with both components equal. A loud systolic ejection click, a Grade 3 high-pitched pansystolic murmur and a Grade 3 early decrescendo diastolic murmur were also audible. Both these murmurs were conducted down the left sternal border. At the tricuspid area a Grade 2 low-pitched, mid-diastolic murmur was heard (Fig. 1) which became louder with inspiration. The electrocardiogram (Fig. 2) revealed an incomplete right bundle-branch block. Chest X-ray

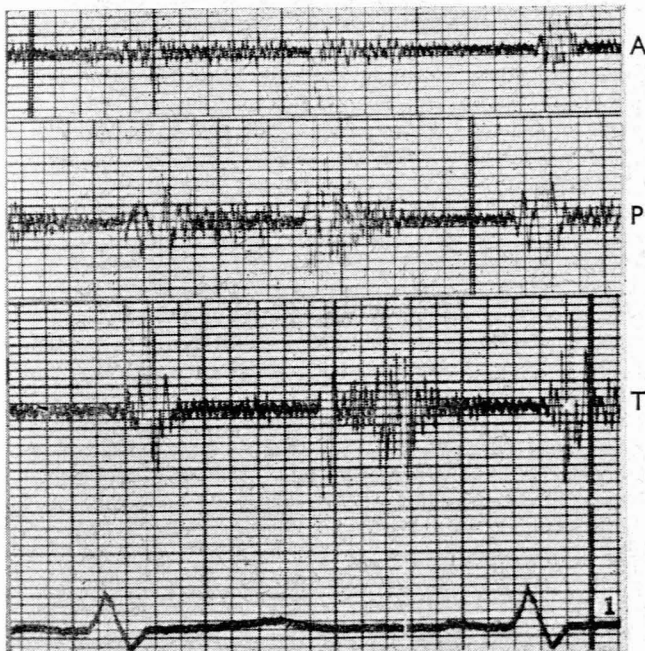


Fig. 1. Phonocardiograms recorded with a Sanborn 'Log' microphone at the aortic (A), pulmonic (P), and tricuspid (T) areas mounted by superimposition of electrocardiograms so that events in the first cycle appear synchronous.

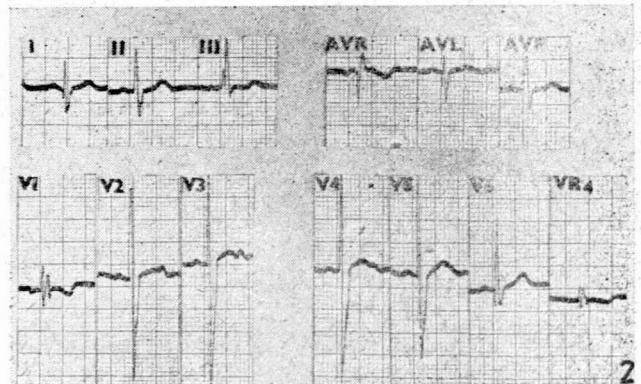


Fig. 2. Electrocardiogram.

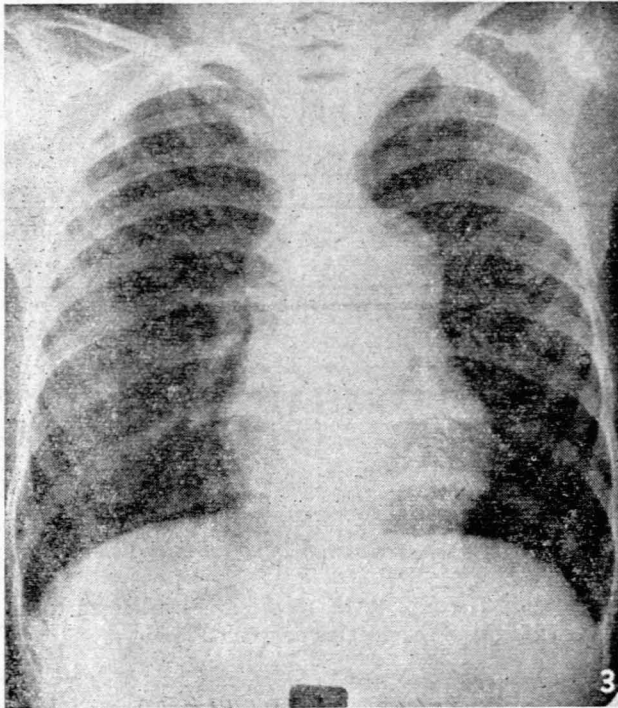


Fig. 3. Chest Roentgenogram. Note the full pulmonary arc and normal lung fields.

(Fig. 3) showed a heart of normal size with marked enlargement of the pulmonary artery segment. This vessel showed large pulsations on fluoroscopy and kymography. The lung vascular markings were normal. Cardiac catheterization revealed no evidence of a shunt, with normal pressures in the right atrium (mean 3 mm. Hg) and right ventricle (25/0 mm. Hg). There was a systolic pressure gradient across the pulmonary valve of 10 mm. Hg and an unusually low diastolic pressure (15/5 mm. Hg) (Fig. 4).

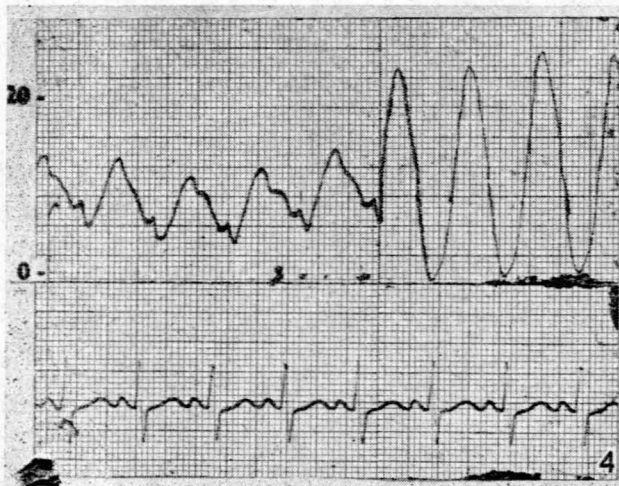


Fig. 4. Pressure record in main pulmonary artery and right ventricle. This is not, as it appears, a continuous withdrawal from artery to ventricle, but is cut from two separate records obtained within the same half minute. Note the negative inflection commencing 0.12 seconds after the onset of the ventricular complex.

Ear oximetry with effort was normal, excluding a significant right-to-left shunt.<sup>1</sup> There was no detectable pressure gradient across the tricuspid valve. An unusual feature of the pulmonary artery pressure curve was the presence of a small negative inflection in early systole producing an apparent delay in the upstroke of the pulmonary pressure curve.

#### DISCUSSION

The diagnosis of isolated pulmonic regurgitation in this case rests on the following points. There was clinical evidence of pulmonic regurgitation in the form of an early diastolic murmur over and below the pulmonic area without any features of aortic incompetence. This was supported by the presence of a hyperdynamic pulmonary artery segment on screening, and an unusually low pulmonary diastolic pressure with a negative wave in early systole on the pressure record. There was no radiological or catheter evidence of any other lesion which might have caused dilatation of the pulmonary artery. Finally, a congenital origin was supported by the detection of murmurs at an early age. The presence of mild pulmonic stenosis as well cannot be excluded, though it is unlikely in the presence of a normal right ventricular systolic pressure. It seemed more probable that this was an example of functional pulmonic stenosis due either to the marked dilatation of the main pulmonary artery<sup>2</sup> or to increased systolic flow or to both. It is well recognized that a systolic pressure gradient may occur in the absence of organic stenosis in such conditions as anomalous pulmonary venous return or inter-atrial septal defect.<sup>3-5</sup> It has also been observed in artificial pulmonic regurgitation in dogs<sup>6</sup> and in idiopathic dilatation of the pulmonary artery<sup>7</sup>.

As an isolated lesion congenital pulmonary incompetence is a rare anomaly. In 1,000 cases of congenital heart disease studied by Abbott<sup>8</sup> there were only 8 cases of primary pulmonary insufficiency, 6 being due to idiopathic dilatation of the pulmonary artery and 2 to cusp abnormalities. Idiopathic dilatation of the pulmonary artery is only associated in a minority of cases with pulmonic regurgitation. For example, in the reports of Green *et al.*,<sup>7</sup> Kaplan *et al.*<sup>9</sup> and Oppenheimer,<sup>10</sup> regurgitation occurred in 8 out of 28 cases and dilatation may have been the cause of the regurgitation in a ninth reported by Morton and Stern.<sup>11</sup> The presence of incompetence due to cusp abnormalities appears to be even less common. Thus Kissin,<sup>12</sup> in a review of 151 case reports of four-cusped pulmonic valves, found evidence of pulmonic incompetence in only 3. Ford and co-workers<sup>13</sup> reviewing the literature of bicuspid pulmonic valve found 16 cases, of whom only 4 may have had an associated pulmonic regurgitation. A case of congenital absence of the pulmonary valve with pulmonic insufficiency and associated with ventricular septal defect has recently been reported by Campeau *et al.*<sup>14</sup>

One cannot be certain whether the regurgitation here was the result of valve deformities or was secondary to dilatation of the pulmonary artery. In those few cases of idiopathic dilatation of the pulmonary artery in which pulmonic regurgitation has been observed, electrocardiograms were normal in all.<sup>4, 7, 9</sup> This suggests that in this condition, incompetence does not reach large proportions. By contrast, incompetence resulting from cusp abnormalities has been associated with 'bundle-branch block' or right ventricular hypertrophy in all cases in which records have been

available.<sup>9, 13, 14</sup> The presence of an incomplete right bundle-branch block pattern in our case therefore, favours its inclusion in the latter group.

The murmur which we have referred to as mid-diastolic appeared earlier in timing than a mitral stenotic murmur and its site of maximal intensity and respiratory variation suggested that it was tricuspid in origin. In the absence of a detectable tricuspid pressure gradient or evidence of increased flow through the tricuspid valve, it seemed possible that this was an 'Austin-Flint murmur' of the tricuspid valve. This implies that it was similar in mechanism to the apical mid-diastolic murmur associated with aortic regurgitation. The murmur described by Ford *et al.*<sup>13</sup> in their case of pulmonic incompetence has a similar configuration.

Of especial interest was the notch which at first glance appeared to occur at the end of diastole (Fig. 4). Comparison with the electrocardiogram indicated, however, that it was early systolic in time. We attributed this negative pressure wave to a Venturi effect produced by an increased stroke volume passing under high velocity into a markedly dilated pulmonary artery. This phenomenon has been observed in pulmonic stenosis<sup>15-17</sup> and has been attributed to a Venturi effect.<sup>15</sup> In pulmonic stenosis it may result in deeply negative inflections in the pressure tracing during systole. For many years a halt in the ascending limb of the pulse in free aortic regurgitation has been recognised and was attributed by Wiggers<sup>18</sup> to sudden acceleration of blood as it enters the aorta. This explanation was offered by Ford *et al.*<sup>13</sup> to explain a similar inflection in the pulmonary artery pressure curve of a subject with pulmonic incompetence, and the same inflection appears in the pulmonary artery pressure record of another case of pulmonary regurgitation reproduced by Kjellberg *et al.*<sup>4</sup> It is in no way diagnostic of pulmonic regurgitation, however, and occurs in a number of congenital anomalies in which pulmonary flow is increased or pulmonary stenosis or pulmonary artery dilatation is present.<sup>19</sup>

Finally, insufficient cases are on record for any reliable information to be available regarding prognosis in this condition. Experimental pulmonary valvectomy in the dog<sup>20</sup> has failed to embarrass the heart significantly and the production of regurgitation following relief of a pulmonic stenosis does not appear to carry a poor prognosis.<sup>21</sup> It is most probable that quite severe degrees of incompetence would be well tolerated in the low-pressure pulmonary circuit.

## SUMMARY

Isolated congenital pulmonic regurgitation is a rare condition. A case is reported which had the following characteristics: A pulmonary early diastolic murmur, a mid-diastolic murmur at the tricuspid area, a dilated main pulmonary artery, and an electrocardiogram showing 'incomplete right bundle-branch block'. The pulmonary artery pressure tracing showed a low diastolic pressure, a systolic pressure gradient from right ventricle to pulmonary artery, and a negative notch in the phase of rapid ejection probably due to a Venturi effect. The significance of these features is discussed.

## REFERENCES

1. Van Lingen, B. and Whidborne, Joanna (1952): *Circulation*, **6**, 740.
2. Contro, S., Miller, R. A. and Derrick, J. (1957): *Amer. Heart J.*, **53**, 542.
3. Grishman, A. and Dack, S. (1957): *Clinical Cardiopulmonary Physiology*. New York: Grune and Stratton.
4. Kjellberg, S. R., Mannheimer, E., Rudhe, R. and Jonsson, B. (1955): *Diagnosis of Congenital Heart Disease*. Chicago: Year Book Publishers, Inc.
5. Blount, S. G. Jr., Swan, H., Gensini, G. and McCord, M. (1954): *Circulation*, **9**, 801.
6. Ellison, R. G., Brown, W. J. Jr., Hague, E. E. Jr. and Hamilton, Wm. F. (1955): *J. Thorac. Surg.*, **30**, 633.
7. Greene, D. G., Baldwin, E. D., Baldwin, S., Himmelstein, A. and Roh, G. (1949): *Amer. J. Med.*, **6**, 24.
8. Abbott, M. E. (1946): *Loose Leaf of Medicine*, Congenital heart disease., vol. 4, page 346. New York: Thomas Nelson.
9. Kaplan, B. M., Schlichter, J. G., Graham, G. and Millar, G. (1953): *J. Lab. Clin. Med.*, **41**, 697.
10. Oppenheimer, B. S. (1933): *Trans. Assoc. Amer. Phys.*, **48**, 290.
11. Morton, R. F. and Stern, T. N. (1956): *Circulation*, **14**, 1069.
12. Kissin, M. (1936): *Amer. Heart J.*, **12**, 206.
13. Ford, A. B., Hellerstein, H. K., Wood, C. and Kelly, H. B. (1956): *Amer. J. Med.*, **20**, 474.
14. Campeau, L. A., Ruble, P. E. and Cooksey, W. B. (1957): *Circulation*, **15**, 397.
15. Bouchard, F. and Cornu, C. (1954): *Arch. Mal. Cœur*, **47**, 417.
16. Sobin, S. S., Carson, M. J., Johnston, J. L. and Baker, C. R. (1954): *Amer. Heart J.*, **48**, 416.
17. Torner-Soler, M., Morató-Portell, J. M. and Balageur-Vintró, I. (1957): *Ibid.*, **53**, 213.
18. Wiggers, C. J. (1952): *Circulatory Dynamics*. New York: Grune and Stratton.
19. van Lingen, B. and Segel, N. To be published.
20. Fowler, N. O., Mannix, E. P. and Noble, W. (1956): *Circ. Res.*, **4**, 8.
21. Blount, S. G. Jr., McCord, M. C., Mueller, H. and Swan, H. (1954): *Circulation*, **10**, 161.