

GASTRIC DIVERTICULA

E. ALAN PRICE, M.B., B.Ch. (RAND), D.M.R.D., R.C.P. & S. (ENG.)

X-Ray Department, Johannesburg General Hospital

Gastric diverticulum is a comparatively rare condition. It was first described by Moebius in 1661 and later by Fourier in 1774.⁵ Radiologically it was first demonstrated by Brown in 1916. According to Feldman³ the radiological incidence is 0.4% and the autopsy incidence 0.2%. Statistics available (1946) indicate that about 155 cases have been reported in the literature.⁷ This apparently innocuous pouch, whether congenital or acquired, is not infrequently responsible for disturbed health.

Schmidt and Walters' classification,⁸ which is based on the commonly accepted aetiological factors, recognizes:

1. Congenital ('true') diverticulum—in which all layers of the stomach are intact. These are due to malformation or interrupted development during foetal life.

2. Acquired ('false') diverticulum, of which there are 2 types:

(a) Pulsion diverticula, which are due to increased pressure and are mucosal hernias through weak spots in the muscular wall.

(b) Traction diverticula, resulting from perigastric adhesions due to inflammatory conditions.

The commonest site is at the cardia. Feldman³ states that 85% occur at the cardia on the lesser curve (on the posterior wall just below the cardio-oesophageal opening). Other sites are rare, though cases have been described at the pylorus and the greater curvature.

The aetiology is difficult to attribute to any particular cause. Tracey⁹ points out that 'an anatomical weakness exists near the cardiac orifice, due to a thinning of the

circular and oblique fibres at that site, while the longitudinal bundles continuing down from the oesophagus divide into two muscular groups at the cardia'. This localized point is therefore comparable to that existing at Killian's dehiscence, where oesophageal diverticula occur. Review of the literature shows that diverticula are found most frequently in middle life. This may suggest that the general loss of muscular tone in middle age may be another contributory factor in the causation of pulsion diverticula. The fact that the cardia is a pressure point for all food entering the stomach and is also the site for the passage of large blood vessels and ducts through the wall are other points worth mentioning. A curious fact is that gastric diverticula are a common occurrence in monkeys and hogs¹ and some writers suggest that in the human this may be a form of atavism. The study of these cases has been prompted by certain unusual features which they exhibit, the association of clinical symptoms with this generally assumed harmless condition, and the difficulties and pitfalls in the radiological diagnosis.

CASE REPORTS

Case 1. M.J.E., a European woman aged 62, was admitted to hospital on 10 September 1951 complaining of epigastric discomfort, pain over the left costal margin, distension and very severe belching, of about 4 months' duration. Food aggravated the pain, while eructations and lying down relieved it. Her appetite was poor and she was afraid to eat because food seemed to 'stick' at the epigastrium. She had lost about 16 lb. in weight. There was no history of haematemesis, melaena or vomiting. She had a similar episode 2 years ago, when she received conservative treatment for dyspepsia.

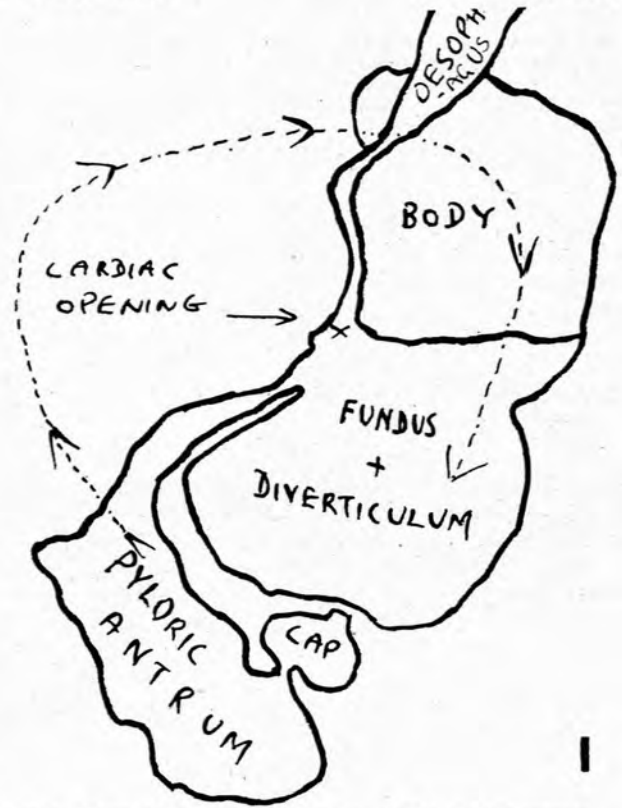


Fig. 1. Case 1. Erect left anterior oblique view of the barium-filled stomach showing the gastric volvulus. Note pyloric antrum points downward as is usual in this type of volvulus. See accompanying diagram. Arrow indicates direction of rotation of the stomach which resulted in a volvulus.

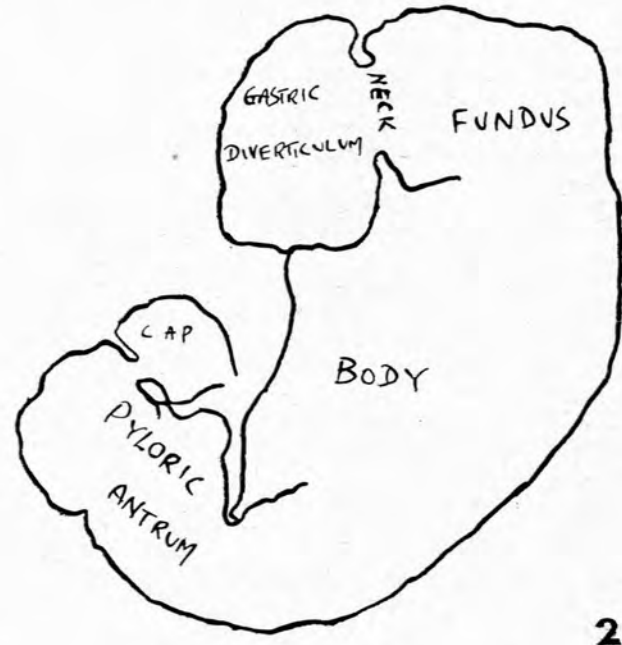
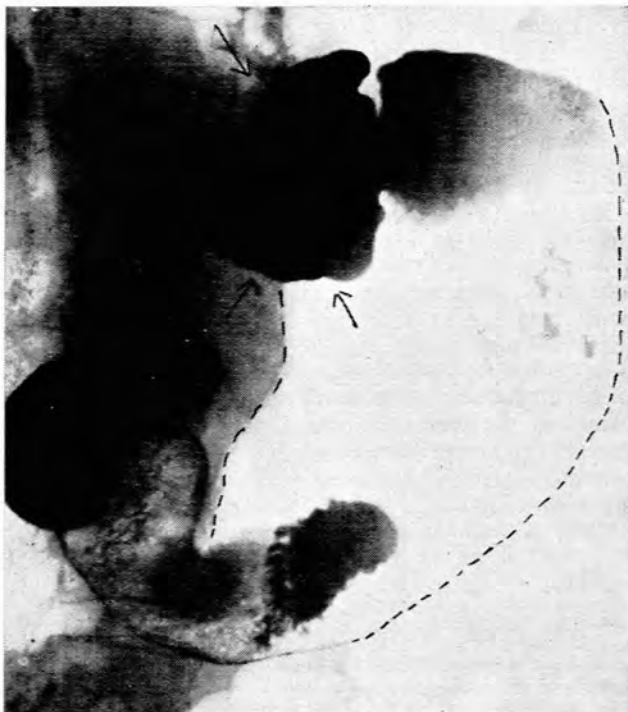


Fig. 2. Case 1. Supine right anterior oblique view showing the large gastric diverticulum with a wide neck. See accompanying diagram.

There was nothing else relevant in the present or past history. On examination the only objective clinical signs were constant belching accompanied by 'weird noises' and aggravated by deep breathing. There was also a constant passage of flatus. No succussion splash was heard over the stomach and there was slight tenderness in the left hypochondrium.

The blood picture was normal. The blood urea was 28 mg. per 100 ml. Serum protein: albumin 5.1 g. per 100 ml., globulin 1.6 g. per 100 ml. The electrocardiogram was normal. The cholecystogram made in the out-patient department was normal.

A barium-meal examination made 3 years prior to admission showed 'a biloculated stomach of the 'cup and spill' type. No other abnormality seen.' A similar examination made 2 years prior to admission showed 'marked gaseous distension of the stomach' and small and large bowel. The stomach presented the appearance of a partial volvulus. No other pathology was noted and no cause for the volvulus was discovered'. Barium studies following the present admission revealed: 'A volvulus of the stomach on the cardiopyloric axis of the organo-axial type. The greater curvature had swept upwards and underneath the diaphragm (Fig. 1). The oesophageal entrance is now on the lateral side of the stomach. This volvulus is associated with a large gastric diverticulum of the cardia (Fig. 2). The follow-through also showed diverticulosis of the colon. Stasis in the diverticulum was present 6 hours after the examination (Fig. 3)'.
Surgical exploration disclosed a capacious stomach with a bulge medial to the spleen. The spleen itself was extremely mobile and it was suspected that it might be partly responsible in the production of the volvulus by traction on the stomach. A splenectomy was performed. A distinct gastric diverticulum was then brought into

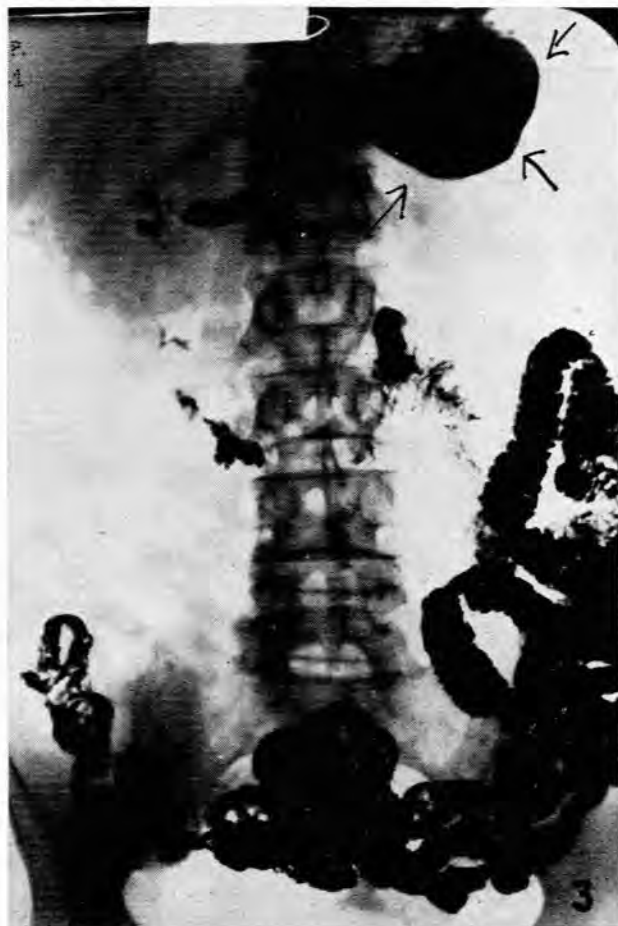

Fig. 3. Case 1. Prone 6-hour film showing stasis in the large gastric diverticulum.

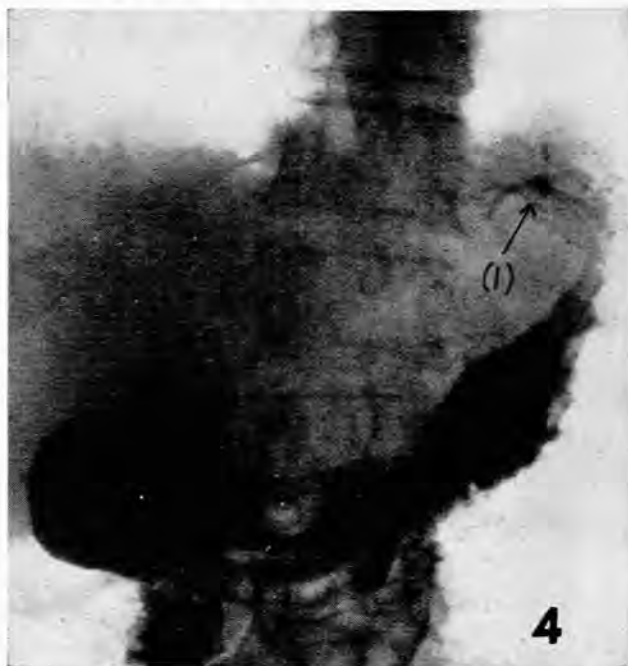

Fig. 4. Case 2. Erect postero-anterior view of stomach showing (1) the irregularity at the fundus resembling an ulcer.

view. Its neck was 2 inches in diameter and the body 3½ inches across. A diverticulectomy was then performed. The rest of the stomach and bowel appeared normal.

Symptoms recurred 6 months later and the partial volvulus was still noted on radiological examination. A partial gastrectomy was performed subsequently. At present, 2½ years after the operation the patient is well.

Case 2. E.J., a European male aged 63, was admitted to hospital for stabilization of his diabetic state, from which he had suffered for the past 25 years. Apart from his diabetes he gave a 2 months' history of distension and the passage of large amounts of foul-smelling flatus by the mouth. He had lost about 15 lb. in weight. There was nothing else of importance in his present or past history.

The physical examination was essentially negative except for bilateral early cataracts. A provisional diagnosis was made of diabetes mellitus with query carcinoma of the stomach. A barium-meal examination performed 2 months before admission had revealed no abnormality.

On the 2nd day after admission, 3 haematemeses of 'coffee grounds' vomit took place, totalling 2 pints. The blood pressure dropped to 85/65 mm. Hg and ketosis developed. Whole blood, 500 c.c., was immediately given and the appropriate treatment for ketosis instituted. Recovery and stabilization was reached 48 hours later.

A week after this recovery from haematemesis a barium-meal examination was performed. 'Some irregularity was noted in the region of the fundus of the stomach, the nature of which was indeterminate, and re-examination was suggested to exclude malignancy. The rest of the stomach and duodenum were normal.'

Ten days later the barium meal was repeated and again the deformity in the fundus was seen. 'There was a persistent fleck of barium at the fundus high up, with rugae radiating towards it. The appearances were strongly suggestive of a healed or healing ulcer.' A barium enema, a cholecystogram and a radiograph of the chest all appeared to be normal.

The patient was discharged and returned periodically as an out-patient. His diabetes remained well controlled, and he gained 8 lb. in weight in the course of the next few months. Clinically he felt reasonably well, but still complained of distension, especially towards the evening and when lying down, epigastric discomfort, and flatulence with foul-smelling eructations.

Three months after being discharged he presented himself for

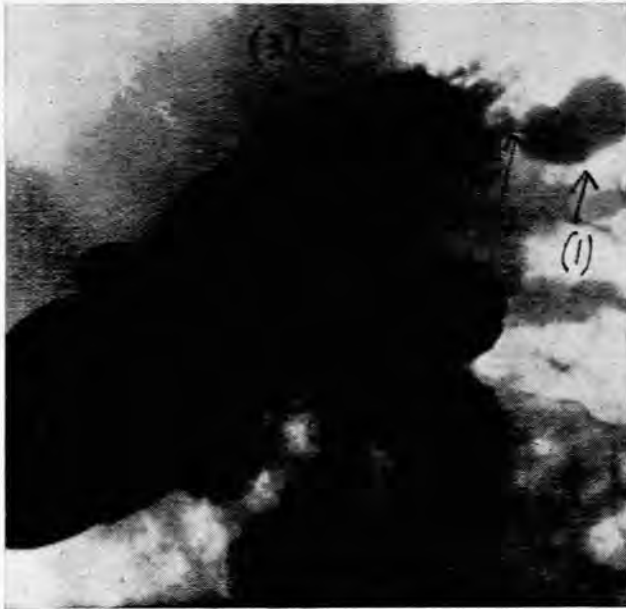

Fig. 5. Case 2. Supine left anterior oblique view of stomach showing (1) pear-shaped smooth diverticulum, (2) narrow neck, (3) level of cardio-oesophageal opening.

another barium-meal examination. The irregularity and convergence of rugae at the fundus simulating a healed ulcer were noted again (Fig. 4). When the patient was placed in the supine position, a pouch appeared near the upper pole of the fundus; this was localized to the posterior wall near the greater curvature, at a level above the cardio-oesophageal opening (Fig. 5). The diagnosis of a gastric diverticulum then became obvious; the films taken show a well-defined, smooth, pear-shaped projection with a narrow neck. Barium remained in the diverticulum for over 6 hours (Fig. 6). Tenderness was not elicited, but the area was inaccessible to palpation. There was no spasm near or opposite the diverticulum and the mucosal pattern of the fundus was otherwise normal. The rest of the stomach and duodenum showed no abnormality.

DISCUSSION

The prevailing general impression is that gastric diverticula are seldom associated with symptoms. Love⁴ mentions that this condition receives much less recognition in England than in the United States. Moses⁶ states that 1 in every 3 diverticula will give rise to adverse symptoms. According to Fawcitt² 'if evidence of an ulcer, neoplasm or gall-stones cannot be found in a patient who complains of unorthodox dyspepsia, flatulence, pain in the chest, etc., and who is not suffering from an obvious condition, then the presence of diverticulum may be suspected'. The symptoms which the diverticulum of a stomach may cause are not specific. They are many and varied. Stasis and decomposition of food may cause irritation, inflammation and ulceration.

Both the cases reported above exhibited symptoms which appear to have been due to the gastric diverticulum or the complications which it has precipitated, viz. a gastric volvulus in case 1, and haematemeses in case 2, with subsequent failure of diabetic control.

Case 1 is a rare and interesting one. A large gastric diverticulum appears to have been the primary cause

for the gastric volvulus, though the extremely mobile spleen was possibly also a contributory factor. No similar record of a gastric diverticulum associated with a gastric volvulus could be found in the available literature.

An interesting feature about case 2 is the relatively uncommon site of the diverticulum, being on the greater curvature, near the upper pole of the fundus at a level above the gastro-oesophageal opening.

Gastric diverticula may be easily missed on radiological examination. The first 2 barium studies in case 1, and the first 3 in case 2 failed to reveal the condition. Feldman³ states, 'Many cases are overlooked in routine radiological examination'. Our case 2 would suggest that this may occur particularly in the presence of a narrow neck (Fig. 5). Such a situation may give rise to a serious diagnostic problem. In all cases of unexplained symptoms referable to the upper gastrointestinal tract, and in which barium studies are negative, the possibility of a gastric diverticulum should be investigated. A slight modification of the routine technique is suggested. This involves the examination of the patient in the supine and prone position soon after the first few mouthfuls of barium have been swallowed, for otherwise a full fundus may obscure the diverticulum. Time should be allowed for the diverticulum to fill, because a narrow neck may be present. It is therefore advisable to re-examine the patient after he has been lying on his back for 10-15 minutes.

SUMMARY

1. A rare case of a gastric diverticulum associated with and causing a gastric volvulus is recorded.

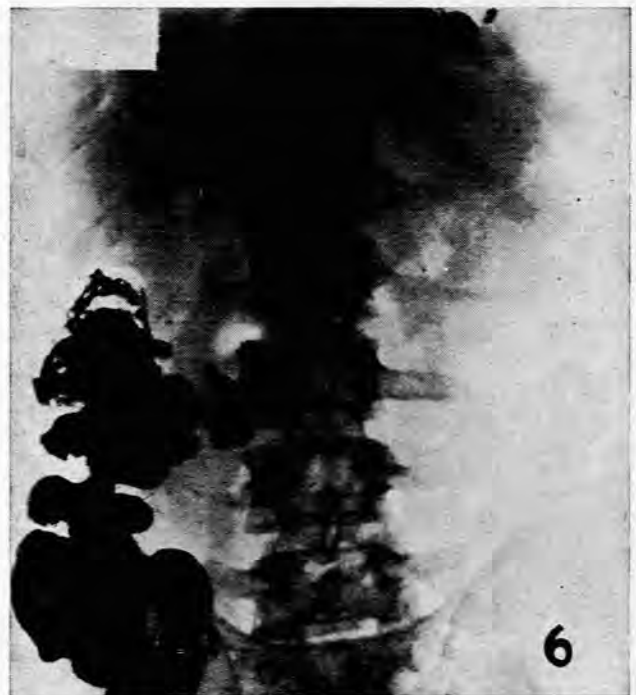

Fig. 6. Case 2. 6-hour film showing retention of barium in the diverticulum.

2. Another case of a gastric diverticulum at an uncommon site and associated with symptoms is recorded.

3. The literature is briefly reviewed with reference to the incidence, classification, site, aetiology and symptomatology.

4. The difficulties which may be encountered in the radiological diagnosis are discussed.

I wish to thank Dr. Josse Kaye, Chief Radiologist, Johannesburg General Hospital, Mr. A. Lee McGregor, and Dr. Julius Buch for their advice and permission to publish the cases. My thanks are also due to Mr. Broadway for the reproductions of the radiographs.

REFERENCES

1. Boppe, M., quoted by Buckstein, J. (1948): *The Digestive Tract in Roentgenology*, p. 223. Philadelphia, London and Montreal: J. B. Lippincott Co.
2. Fawcitt, R. (1949): *Brit. J. Radiol.*, **22**, 427.
3. Feldman, M. (1948): *Clinical Roentgenology of Digestive Tract*. London: Baillière, Tindall and Cox.
4. Love, M. (1942): *Brit. J. Surg.*, **30**, 180.
5. Martin, L. (1936): *Ann. Intern. Med.*, **10**, 447.
6. Moses, W. R. (1946): *Arch. Surg.*, **52**, 59.
7. Resnick, B. (1946): *Amer. J. Roentgenol.*, **55**, 713.
8. Schmidt, H. W. and Walters, W. (1941): *Amer. J. Surg.*, **52**, 315.
9. Tracey, M. L. (1943): *Gastroenterology*, **1**, 518.