

## MYOCARDITIS OF THE NEWBORN

## AN OUTBREAK IN A MATERNITY HOME IN SOUTHERN RHODESIA ASSOCIATED WITH COXSACKIE GROUP-B VIRUS INFECTION

J. MONTGOMERY, M.D., B.Ch., B.A.O., F.R.C.S.

*General Hospital, Umtali, Southern Rhodesia*

JAMES GEAR, M.B., Ch.B., D.P.H., D.T.M. AND H., DIPL. BACT.

F. R. PRINSLOO, B.Sc.

M. KAHN, B.Sc.

Z. G. KIRSCH, M.Sc.

*Poliomyelitis Research Foundation**South African Institute for Medical Research*

In late February and early March 1954, 3 babies developed an acute febrile illness soon after birth in a maternity home in Southern Rhodesia. One of them died on the 12th day after birth, and the other 2 recovered after being ill for about 1 week. As this outbreak was found to be associated with an infection with a Coxsackie group-B virus, the details of the clinical findings and the laboratory studies are recorded.

## CLINICAL FINDINGS

*Case 1.* Baby W was born on 25 February 1954; 'face to pubis' with bruising and oedema of the face and eyes; birth weight 5 lb. 6 oz. There was initial difficulty with feeding and an oesophageal tube was used on 27 and 28 February. Breast feeding was commenced on 1 March, but the baby was lethargic. On this day the mother developed a mild pyrexia; blood films were examined for malarial parasites and found to be negative.

On 4 March the baby was noticed to be flushed and hot and its temperature was found to be 100.4°F rising to 103.4° during the night. Its condition became worse towards morning. The skin was pale with some cyanosis, respirations were rapid and the lower extremities were cold. The physical signs on examination were equivocal but the picture generally was suggestive of pneumonia. The white-cell count was 11,400 per c.mm., (neutrophils 46%, lymphocytes 47%, monocytes 4%, immature cells 3%). No

malarial parasites were detected. The stool and urine tests gave negative results.

Penicillin (200,000 units) was given 6-hourly, and chloromycetin (75 mg.) 3-hourly. Nasal feeds were given 3-hourly and oxygen administered continuously. This treatment was continued until 6 March with no obvious improvement. There was now slight head retraction but no other signs of cerebral nervous irritation. Aureomycin in 25-mg. doses was substituted for chloromycetin. The baby remained very ill with a raised temperature up to 103° F (Fig. 1).

On 7 March there was still no change; the temperature remained elevated and there was considerable retching of mucus. At this stage it was decided to give quinine in spite of negative blood findings and 2½ gr. was given intramuscularly at 8.30 a.m. and repeated at 5.30 p.m. The temperature fell, but there was no corresponding improvement in the baby's general condition.

8 March. Quinine was continued, but all other drugs were discontinued. Vomiting was marked.

9 March. Baby was still limp and lethargic. Nasal feeds were continued. The temperature returned to normal during the day. The last quinine injection was given at 12 noon.

10 March. There was some improvement in the baby's condition and nasal feeding was continued.

11 March. The improvement was maintained and feeding by bottle was complemented by tube.

12 March. Returned to breast feeding. Continued improvement.

14 March. Discharged. Weight 6 lb 5 ozs.

*Follow-up.* No recurrence of symptoms. Normal gain in weight. No drugs given.

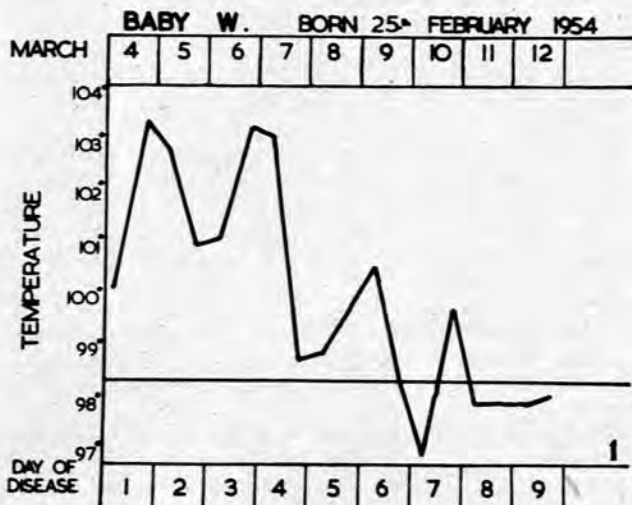


Fig. 1. Case 1, Baby W.

*Case 2.* Baby T, male, was born on 26 February 1954. Normal delivery; slow to cry; some cyanosis; birth weight 8 lb 8 oz.

Normal progress until 3 March, when baby became lethargic and difficult over feeding. Thyroid, gr. 1/10, given thrice daily with apparent improvement.

6 March. Baby lethargic and disinclined to feed. Temperature 100.4°F at 8 a.m. No abnormal physical signs on examination. Stools of normal appearance. Penicillin (200,000 units) and aureomycin (25 mg.) given 6-hourly.

7 March. Baby still lethargic, pale and ill. Breast feeds taken fairly well. Penicillin and aureomycin continued.

8 March. The baby's temperature still elevated and condition unsatisfactory. The white-cell count was 13,400 c.mm., (neutrophils 50%, lymphocytes 44%, monocytes 3%, eosinophils 1%, immature cells 2%). Urine reaction acid, trace of albumin, no sugar; microscopical examination showed scanty pus-cells, occasional red blood-cells. A specimen of stool was sent to the South African Institute for Medical Research for virus studies.

9, 10 and 11 March. The baby's condition was unchanged; he was still lethargic and his temperature still elevated; penicillin was discontinued (Fig. 2).

12 March. Vomited mucus in quantity; mouth sore and red.

13 March. The vomiting diminished and he was able to breast feed. This was complemented. Temperature normal.

14 March. Still lethargic but improvement continued.

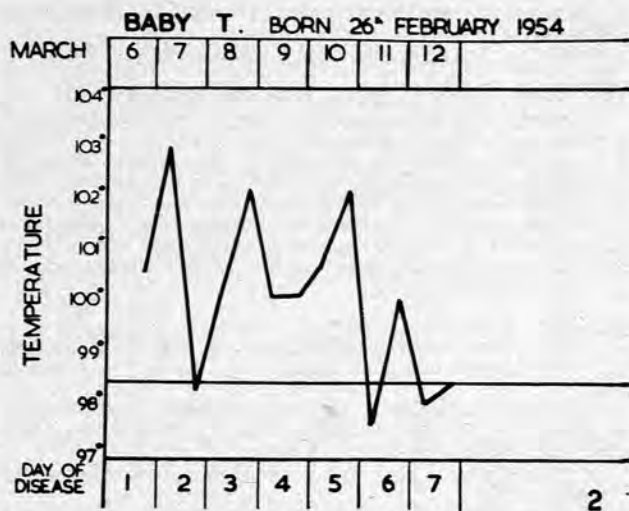


Fig. 2. Case 2, Baby T.

15 March. His improvement was maintained, and he was discharged from the Home. Weight 9 lb.

Case 3. Baby B was born on 2 March 1954; forceps delivery, birth weight 6 lb 1 oz.

5 March. Baby was lethargic and his attempts to feed were poor. His temperature was raised. Aureomycin (25 mg.) given 6-hourly.

6 March. No significant signs were found on physical examination. He vomited and aureomycin was discontinued. Penicillin (200,000 units) 6-hourly given. Nasal feeds were commenced owing to failure to suck. His stools were loose.

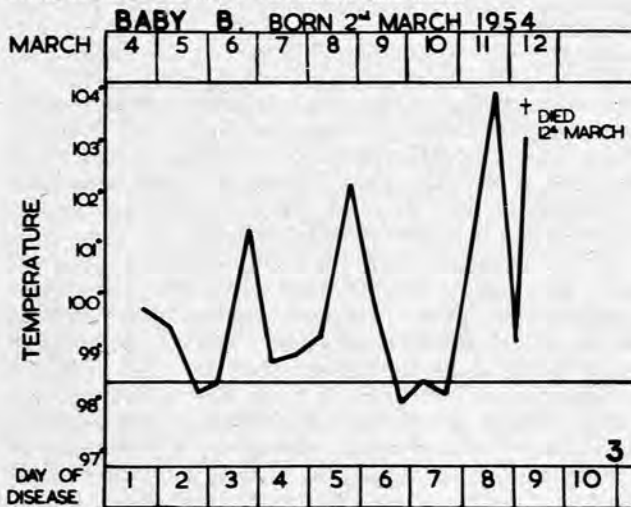


Fig. 3. Case 3, Baby B.

7 March. Respirations and pulse rapid and there was some distension of abdomen. Colour pale and vomiting marked. Temperature remained elevated.

8 March. Slight improvement.

11 March. Temperature rose sharply, stools loose and offensive (Fig. 3).

12 March. Respirations and pulse were fast. Convulsions occurred at 8.45 a.m. Baby died at 9.30 a.m. A post-mortem examination was held at 2 p.m. the same day.

#### Post-mortem Examination

The external appearances were not significant. The lungs were congested, but there was no broncho-

pneumonia. The heart showed no congenital abnormalities and macroscopically appeared relatively normal. The abdominal organs showed congestion. The brain appeared normal.

The organs preserved in formol saline and the brain in sterile glycerin were personally taken to Johannesburg on 17 March for further studies. A specimen of stool taken on 11 March was also submitted for virus studies.

#### PATHOLOGICAL EXAMINATION

In the laboratories of the Poliomyelitis Research Foundation histological sections were prepared from the brain, the heart, one lung, the liver, one kidney and one suprarenal. The results of microscopical examination of these sections were as follows:

**Brain.** Three sections prepared from the cortex and the mid-brain showed congestion but no other pathological change. No foci of inflammation such as were seen in sections of the brain of one of the fatal cases in the previous outbreak of a similar nature in Johannesburg<sup>1, 2, 3</sup> were observed.

**Heart.** The sections of the heart, which macroscopically had not appeared grossly abnormal, on microscopical examination revealed scattered foci of inflammation in the substance of the muscle. These foci were not circumscribed but faded into relatively normal cardiac muscle. In the foci, the muscle showed eosinophilic degeneration and fragmentation and in places the muscle had disappeared, associated with a surrounding inflammatory cell infiltrate mostly of mononuclear cells, histiocytes and lymphocytes, but also including polymorphonuclear leucocytes.

**Lung.** The lung showed very marked congestion, but no consolidation or inflammation. The epithelium of the bronchioles was relatively normal and there was no peribronchial inflammation. The pleura was oedematous and there were a few inflammatory cells present.

**Liver.** The liver showed marked congestion and some of the parenchymal cells showed vacuolation, but there were no foci of degeneration.

**Kidney.** The kidney sections also showed marked congestion, but no inflammation.

**Suprarenal.** The suprarenal showed very marked congestion of the medulla, in which a few foci of inflammatory cells mostly of the mononuclear type were detected.

This examination revealed that the only organ showing marked pathological lesions was the heart. The other changes observed, particularly the marked congestion of the lungs and abdominal organs, could have resulted from the failure of the heart, which emerges as the cause of death.

#### VIRUS STUDIES

Attempts to isolate virus from the specimens of faeces received from each of the 3 babies affected and also from the brain of Baby B were made in the Laboratories of the Poliomyelitis Research Foundation. Recalling that a similar outbreak in Johannesburg in 1952<sup>1</sup> had been found to be associated with an infection with Cocksackie group-B virus,<sup>2</sup> this virus was especially sought. In 2 of the 3 cases it was isolated from the faeces.

#### Methods

A 10% suspension of the material was prepared in nutrient broth. To this a quarter volume of anaesthetic ether was added and allowed to act for 24-48 hours in a +4°C refrigerator. The suspension was then centrifuged at 3,000 revolutions per minute for 1 hour. The aqueous phase underlying the ether layer was withdrawn and transferred to a wide-mouthed specimen-



bottle, which was then placed in a 37°C incubator for 2 hours to allow the dissolved ether to evaporate. Penicillin (100 units per ml.) and streptomycin (100 µg. per ml.) were added to the suspension, which was then ready for inoculation.

The suspensions prepared from the mouse carcasses were treated in a similar manner in some instances, but in others the suspension was not subjected to the action of ether.

Newborn baby mice (less than 24 hours old) were inoculated subcutaneously and then observed for signs of illness, including weakness, paralysis and tremors, for 14 days.

These litters were housed in an isolation unit where no other work was being done with Coxsackie virus and so there was no possibility of cross-infection or of false-positive results.

An account of the relevant details of these studies follows.

#### BABY W.

13 March 1954. A specimen of faeces from Baby W was received.

17 March. After preparing a 1:10 suspension in broth as described above the suspension was inoculated into a litter of 7 one-day-old mice. These were observed for 14 days, but none developed signs of illness.

Virus was not isolated from this patient in this one attempt. The attempt was not repeated, as it undoubtedly should have been, in the light of the subsequent findings.

#### BABY T.

##### First Isolation from Faeces

13 March 1954. A specimen of faeces from this patient was received.

18 March. After preparation, a suspension was inoculated into a litter of 7 one-day-old mice.

23 March. One mouse was weak. It was sacrificed and a suspension of its carcass passaged the same day into a further litter of 7 mice.

24 March. Two mice were paralysed, the rest had severe tremors. One of the paralysed mice was sacrificed and histological sections of its organs were prepared and examined: The fat pad showed necrosis and acute inflammation of some of the lobules; the limb muscles showed small foci of inflammation with eosinophilic degeneration of some segments of muscle, associated with acute inflammatory cell infiltration.

25 March. Of the remaining 4 mice, one was found dead, 2 were paralysed and one had tremors.

##### Second Isolation from Faeces

17 March 1954. A second specimen of faeces from Baby T was received. A 10% suspension was prepared and treated as before.

19 March. This suspension was inoculated into a litter of 7 one-day-old mice.

20 March. One was found dead and discarded.

22 March. One had slight tremors.

25 March. One was weak. It was sacrificed and its carcass kept for passage.

26 March. Three had tremors.

27 March. One was paralysed and the rest had tremors. The paralysed mouse was sacrificed and histological sections prepared from its organs: The brain sections showed perivascular cuffing of blood vessels in some areas, pyknosis of the nuclei of some cells, a few inflammatory cells, and small areas of softened white matter. The fat pad showed extensive acute necrosis and inflammation. Lesions shown by each of the 2 mice examined are similar to those produced by Coxsackie group-B virus.

#### BABY B.

##### Original Isolation from Faeces

17 March 1954. A specimen of faeces collected on 11 March

was received. A 10% suspension was prepared in nutrient broth and treated with ether as described above.

19 March. The suspension was inoculated into 7 one-day-old mice.

22 March. Two of these baby mice appeared to be weak.

23 March. Another mouse had developed weakness. One was sacrificed and its organs preserved in Bouin's fixative solution for the preparation of histological sections: Histological section of the brain showed small foci of cells showing pyknosis of the nuclei, associated with a few inflammatory cells. The fat pad showed marked acute necrosis and inflammation. The heart muscle showed foci of eosinophil degeneration and inflammation. These lesions resembled those produced by and characteristic of Coxsackie-B virus infection.

##### Original Isolation from Contents of Caecum

19 March. A suspension prepared from the caecal contents taken *post mortem* was inoculated into a litter of 7 one-day-old mice.

22 March. Two of these baby mice were weak. One was kept for passage and a suspension prepared from its carcass was inoculated into another litter of 7 baby mice.

23 March. One mouse had wrist drop, 2 were weak and 3 appeared normal.

26 March. Three mice were dead, one paralysed and 2 had marked tremors.

##### Passage I

22 March. The suspension from the carcass of the weak mouse was inoculated into a litter of 7 one-day-old mice.

25 March. Five mice were dead; 1 was paralyzed and was sacrificed. Its carcass suspension was kept for further passage. The organs were prepared for histological sections: The brain showed no lesions; the fat pad showed necrosis and early acute inflammation resembling that produced by Coxsackie group-B virus.

*Brain.* Several attempts were made to isolate virus from a suspension of the brain. Some of these were invalidated by the persistence of post-mortem contaminating bacteria. One gave negative results.

##### Comment

Viruses resistant to the action of ether and pathogenic to baby mice were thus isolated from the faeces of Baby T on 2 occasions and from the faeces and caecal contents of Baby B. One attempt to isolate virus from the faeces of Baby W failed, as did several attempts to isolate virus from the brain of Baby B.

This failure to isolate virus from the brain was not unexpected as no lesions were seen in the histological sections and, when the baby died, he had been ill for one week, a time which would allow of the development of neutralizing antibodies in the blood.

The viruses isolated from Baby B and Baby T have been passaged several times in baby mice and regularly produce in them an acute necrosis and inflammation of the fat pad. In a proportion of these baby mice, focal lesions of the brain, and also focal necrosis and inflammation of the heart muscle and of segments of the voluntary muscles, have been detected.

As noted above in the individual instances, these lesions resemble those produced by Coxsackie group-B viruses.

#### IMMUNOLOGICAL STUDIES

##### Immunological Identification of the Viruses

The viruses isolated from Baby B and Baby T were typed against specific antisera prepared in monkeys against Dalldorf's classical strains of Coxsackie group-B viruses.

**Method.** In these tests each suspension of mouse carcass was diluted to give a titre of approximately 1,000 L.D./50 per mouse dose of 0.05 c.c. This virus suspension, in 0.5 c.c. amounts, was then mixed with an equal amount of neat serum. The mixture was incubated for 1 hour at 37°C and then the mixture was inoculated into 5 of a litter of 7 newborn mice. The remaining 2 mice were inoculated with virus suspension only, to serve as controls for the others.

**Results.** The results of the tests were as follows:

| Result of Test: Survivors/Total |                          |               |                        |        |                |
|---------------------------------|--------------------------|---------------|------------------------|--------|----------------|
| Test No.                        | Coxsackie Group Antisera | Virus         |                        |        | Interpretation |
|                                 |                          | Baby B Faeces | Baby B Caecal Contents | Baby T |                |
| 1                               | B1                       | 0/5           | 0/5                    | 0/5    | No protection  |
|                                 | B2                       | 0/5           | 0/5                    | 0/5    | No protection  |
|                                 | B3                       | 0/5           | 0/5                    | 0/5    | No protection  |
|                                 | B4                       | 5/5           | 5/5                    | 5/5    | Protection     |
| 2                               | B1                       | 0/5           | 0/5                    | 0/5    | No protection  |
|                                 | B2                       | 0/5           | 0/5                    | 0/5    | No protection  |
|                                 | B3                       | 0/5           | 0/5                    | 0/5    | No protection  |
|                                 | B4                       | 5/5           | 4/5                    | 5/5    | Protection     |

The control mice in each experiment developed weakness and paralysis.

**Comment.** It is apparent from these results that the viruses from Baby B and Baby T were fully neutralized by Coxsackie-B4 antiserum, but not by antisera of Coxsackie types B1, B2 or B3. It was concluded, therefore, that these viruses were Coxsackie group-B type-4 viruses.

Blood specimens were not received from the babies either during the febrile illness or in convalescence. It therefore was not possible to determine whether a rise in titre of their antibodies against Coxsackie group-B virus had occurred subsequent to their infection. The question thus arises as to the pathogenicity of this virus and of its relation to this outbreak of illness.

The same type of Coxsackie group-B virus was isolated from a number of cases of Bornholm disease, which has now been proved to be one manifestation of infection with the virus, and which was prevalent in Southern Rhodesia at this time. During the same period this virus was also isolated from the faeces and the cerebrospinal fluid of a number of cases of meningo-encephalitis. There is therefore little doubt of its pathogenicity, and its presence in the faeces of the babies is presumptive evidence of its aetiological relationship to their illness. It is realized that this was not definitely proved by its isolation from the blood, which was not attempted.

#### Immunity Tests on the Mothers' Blood Serum

Three months after receiving the specimens from the babies, blood specimens were received from their mothers. This serum was separated and tested on several occasions against the viruses isolated from Baby B and Baby T, and against Dalldorf's B4 strain.

**Method.** In this test the serum was mixed with a virus suspension containing approximately 1,000 I.D./50 doses of virus. The serum-virus mixture was shaken thoroughly and incubated at 37°C for 1 hour. The mixture was then inoculated subcutaneously into a litter of 5 baby mice. The 2 remaining mice of the litter were

then inoculated with the virus suspension only. The mice were observed for 14 days.

**Results.** The results of these serum protection tests were as follows:

| Result of Test: Survivors/Total |          |        |        |   |         |     |                |
|---------------------------------|----------|--------|--------|---|---------|-----|----------------|
| Serum (name)                    | Test No. | V B.B. | i B.T. | r | u D.B.4 | s   | Interpretation |
| Mrs. B.                         | 1        | 0/5    |        |   |         | 0/5 | Negative       |
|                                 | 2        | 0/5    |        |   |         |     | Negative       |
|                                 | 3        | 0/5    |        |   |         |     | Negative       |
| Mrs. T.                         | 1        |        | 0/5    |   |         | 0/5 | Negative       |
|                                 | 2        |        | 0/5    |   |         |     | Negative       |
| Mrs. W.                         |          |        | 4/5    |   |         | 4/5 | Positive       |

**Comment.** The results of these tests reveal that Mrs. B and Mrs. T had no antibodies against the virus isolated from their own babies, but that Mrs. W had antibodies against Baby-T virus and against Dalldorf's B4 strain.

It will be recalled that before her baby became ill Mrs. W had a short febrile illness. It appears probable that this illness was due to Coxsackie-B4 virus infection. Such an interpretation would account for her own illness, and for her baby's illness. Although no virus was isolated, the clinical picture of Baby W's illness was similar to that of the other 2 babies and there is little doubt that Baby W had the same infection. If his mother's infection had preceded by some time her admission to the maternity home, she would have been immune to this infection, and her baby would have shared this immunity.

The finding that both Mrs. B and Mrs. T had no immunity to their baby's viruses is of significance in that their babies would also have no inherited passive immunity. It is unlikely that Coxsackie group-B virus would cause a severe and in one case a fatal illness in babies whose mothers had immunity to this virus. In babies whose mothers have no immunity, it appears from these findings that this virus may on occasion cause a fatal infection as it does in newborn baby mice.

#### DISCUSSION

The features of this outbreak are essentially similar to those of an outbreak affecting newborn babies in a maternity home in Johannesburg in October 1952. Of 10 babies affected 6 died after an acute febrile illness ending in circulatory collapse.<sup>1</sup> Post-mortem examinations carried out on 3 of them revealed that the cause of death was acute heart failure resulting from a focal but extensive myocarditis.<sup>2</sup> In one case a focus of inflammation in the brain and involvement of the suprarenal were detected, suggesting that the myocarditis was part of a generalized infection.

Coxsackie group-B virus was isolated from the faeces of 2 of the 3 patients who recovered and who were examined for its presence.<sup>3</sup> Baby mice inoculated with suspension prepared from the brain and the heart of 2 of the fatal cases showed lesions of the fat pad and brain, resembling those caused by Coxsackie group-B virus. It was therefore concluded that the outbreak was caused by Coxsackie group-B virus. This virus was typed and found to be a type-3 virus. At the time of this outbreak Bornholm disease was prevalent in Johannes-

burg as it was, later, at the time of the outbreak in Rhodesia, a coincidence which was significant in view of the findings of the virus studies.

The clinical picture and the pathological findings in the two outbreaks were so similar that a similar aetiology was suspected. The findings incriminating Coxsackie group-B virus in the Rhodesian cases is therefore regarded as mutually strengthening the case that this virus was responsible for both outbreaks.

It is noteworthy that the virus isolated from the Rhodesian cases is of a different type from that isolated from the Johannesburg cases. However, the lesions produced in baby mice by these two types of virus are indistinguishable and it may be expected that they could give rise to a similar disease in baby humans. It is believed that these are the first occasions in which evidence incriminating Coxsackie group-B virus as a cause of myocarditis neonatorum has been forthcoming. This evidence, although not absolutely conclusive, is convincing. A further condition—myocarditis of the newborn—has thus been added to those known to result from infection with Coxsackie group-B viruses, which have already been identified as the cause of Bornholm disease and in this region as one of the commonest causes of meningo-encephalitis.

#### SUMMARY

In late February and early March of 1954, 3 babies developed an acute febrile illness soon after birth in a maternity home in Southern Rhodesia. One of these babies died on the 12th day after birth; the other 2 recovered after being ill about one week.

Histological sections of the organs taken post mortem from the baby who died revealed that the cause of death

was an acute focal but extensive myocarditis. Foci of inflammation were also found in the suprarenal and pleura. The other organs showed marked congestion, but no inflammation.

In virus studies, a Coxsackie group-B type-4 virus was isolated from the faeces of one of the patients who recovered, but not (on one attempt) of the other. The same type of Coxsackie-B virus was recovered from the faeces and from the caecal contents of the baby who died.

Immunity studies were not done on the babies' blood, but tests on specimens of blood taken 3 months after the outbreak from the mothers concerned revealed that 2 of them had no antibodies. The mother who had antibodies had a febrile illness while in the maternity home soon before her baby became ill. It seems probable that this illness was caused by the same infection as later affected the babies.

It is concluded that the cause of this outbreak was a Coxsackie group-B type-4 virus. Coxsackie group-B viruses thus far have been incriminated as the cause of pleurodynia or Bornholm disease, meningo-encephalitis and, as a result of the study of this episode and of a similar one in Johannesburg in 1952, of myocarditis in newborn babies, which may end fatally.

#### REFERENCES

1. Javett, S. N., Heymann, S. C. and Mordel, B. (1955): *Myocarditis in Newborn Babies. A Study of an Outbreak in a Maternity Home in Johannesburg. Part I—Clinical and Epidemiological Findings.* In press.
2. Pepler, W. J. and Lurie, H. I. (1955): *Myocarditis in Newborn Babies. A Study of an Outbreak in a Maternity Home in Johannesburg. Part II—Pathology.* In press.
3. Gear, J. H. S. and Measroch, V. (1955): *Myocarditis in Newborn Babies. A Study of an Outbreak in a Maternity Home in Johannesburg. Part III—Virus Studies.* In press.