

# South African Medical Journal

## Suid-Afrikaanse Tydskrif vir Geneeskunde

P.O. Box 643, Cape Town

Posbus 643, Kaapstad

Cape Town, 1 December 1956  
Weekly 2s. 6d.

Vol. 30 No. 48

Kaapstad, 1 Desember 1956  
Weekliks 2s. 6d.

### LOCALIZED TUBERCULOSIS OF THE DESCENDING COLON

L. STEIN, B. SC.HONS., M.B., B.CH. (Rand), F.R.C.S. (EDIN.)

and

J. V. TODES, M.B., B.CH. (RAND), D.M.R.D. (R.C.P. & S.)

*Baragwanath Hospital, Johannesburg*

Compared with the small intestine, the colon is rarely the site of tuberculosis and when infection occurs it is almost always near the ileo-caecal region.<sup>1</sup> McLaughlin<sup>2</sup> states that 85% of intestinal tuberculosis occurs in the ileo-caecal region and the ascending colon, probably because lymphoid patches are numerous there or because of the relative stagnation of contents in the lower ileum. Widespread ulceration may affect a large part of the large intestine as a terminal event in a patient suffering from active pulmonary tuberculosis.<sup>3</sup> In a series of 5,529 admissions of cases of pulmonary tuberculosis during the 25 years 1924-49, Mitchell and Bristol<sup>4</sup> found the intestine involved in 24.7% of advanced cases.

Apart from the rectum and anus, which will not be discussed, localized tuberculous disease of the large bowel distal to the caecum and ascending colon is uncommon. Boles and Cohen<sup>5</sup> in a series of 1,000 consecutive autopsies found 23% with healed or active tubercle, of which 28% (63 cases) showed intestinal tuberculosis. There were no cases of localized colonic tuberculosis beyond the ascending colon and there have been very few such cases reported. Three involving the hepatic flexure,<sup>6</sup> and 3 the transverse colon,<sup>7-9</sup> the last two of which were associated simultaneously with carcinoma, have been described. The double lesions of carcinoma and tuberculosis have been noted in the sigmoid colon,<sup>10-12</sup> and Miller<sup>13</sup> has described a case in which the patient died of phthisis and at post-mortem a mass was found in the descending colon which was mixed tubercle and carcinoma on section. No reports of localized tuberculosis of the descending colon, diag-

nosed during life, could be found in the literature. At Baragwanath Hospital during the 5½-year period, January 1951 to June 1956, 284 cases of intestinal and peritoneal tuberculosis were diagnosed, and of these only one case affected the colon distal to the ascending colon. This was of a tuberculous lesion localized to the descending colon and it was felt that it was rare enough to warrant this report.

#### CASE REPORT

J.B., a 50-year-old Bantu male was admitted to Baragwanath Hospital on 15 May 1956 complaining of pain in the right axilla and in the left side of the abdomen, both of 2 weeks' duration. The abdominal pain was colicky in nature and did not radiate. There was no vomiting and no abnormality in the stools or bowel action.

#### *Examination*

The patient looked rather ill, but was apyrexial. In the right axilla was a large tender mass which consisted of a matted fixed group of glands associated with what appeared to be a typical discharging tuberculous sinus. In the left groin and continuing to the left iliac fossa was a fairly tender ill-defined mass, 3 inches by 1 inch in size, which was firm and appeared to be fixed to the posterior abdominal wall. No enlargement of liver or spleen was felt.

#### *Investigations*

The stools were negative for amoeba and several urine examinations for tubercle appeared negative. Biopsy of the axillary gland showed a tuberculous adenitis. X-ray of the chest showed a slight pleural reaction at the left base, but the lungs were otherwise clear. Retrograde pyelogram was normal. Barium-enema examinations on 24 May and 1 June revealed a 3-inch regular smooth narrowing in the descending colon, which halted the flow of barium temporarily (Fig. 1). The mucosa in the narrowed segment was intact (Fig. 2). The remainder of the colon and the caecum and terminal ileum appeared normal.

It was felt that the stricture was most likely tuberculous in origin in view of the presence of the tuberculous axillary gland and the intact mucosa.

The patient was put on an anti-tuberculous regime of strepto-

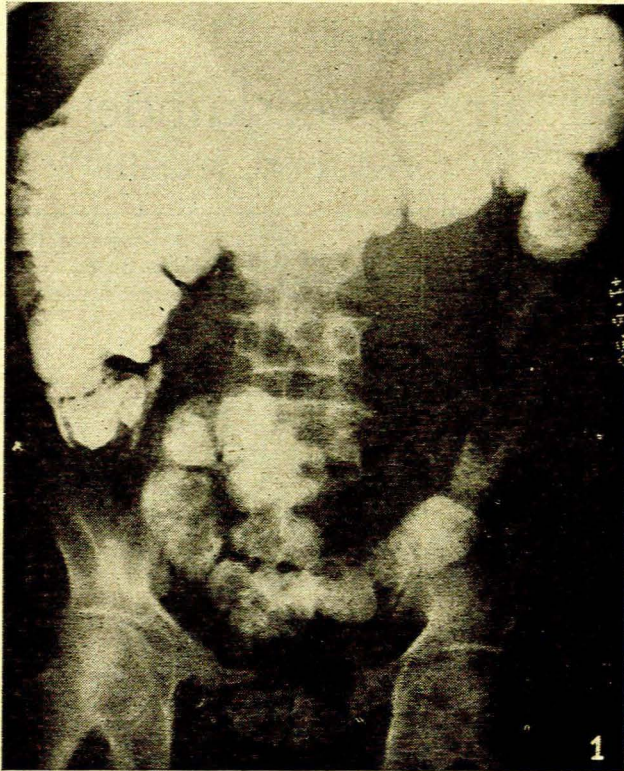


Fig. 1. Barium enema to show the narrowed area in the descending colon.

mycin, Rimifon and PAS daily for 6 weeks. At this stage he developed symptoms and signs of partial intestinal obstruction and the mass now felt stony hard, non-tender and fixed. A repeat barium-enema examination showed exactly the same appearances as the first. On 30 June laparotomy was performed in view of the patient's age, the possibility of the mass being carcinomatous, and the possibility of increasing obstruction.

#### Operation Findings

The mass was found to be due to a very thickened descending colon surrounded by numerous adhesions. The posterior peritoneum was also markedly thickened. The greater omentum was found to be shrivelled up and thickened to form an 'omental cake'. The caecum and remainder of the colon appeared normal. After the descending colon and splenic flexure were with some difficulty mobilized, they were resected and an end-to-end anastomosis of the terminal portion of the transverse colon to the sigmoid colon was performed. The resected portion on being opened was found to present the typical appearances of hyperplastic tuberculosis, viz. markedly thickened wall with extensive fibrous-tissue infiltration giving rise to a very narrow lumen.

*Histological Report* by Dr. I. W. Simson of the South African Institute for Medical Research:

'Section from the specimen of descending colon shows the presence of numerous tubercle follicles lying in the submucosa. The serosal surface is markedly thickened owing to fibrous and granulation tissue in which there are areas of coagulative necrosis surrounded by endothelioid cells and histiocytes. In addition, an occasional acid-fast bacillus was also observed. The histological features are those of tuberculosis.'

#### Progress

The patient made a good recovery. He was seen 3 months after the operation and was fit and well, having gained a little weight. There was no disturbance of bowel function. Anti-tuberculous treatment was continued for 6 weeks after the operation.

#### DISCUSSION

Carcinoma is the common lesion causing a stricture in the descending colon. Characteristically the stricture is irregular, fixed, with the loss of mucosa, and often eccentric. It is sharply defined and constant, which distinguishes it from colospasm.<sup>14</sup> In our patient the stricture was unchanged in appearance after 6 weeks and, the mucosa being intact, a non-malignant condition was suggested. However, a disturbed mucosal pattern does not exclude tubercle as Eckey's case showed altered mucosa and was erroneously diagnosed as neoplasm.<sup>15</sup>

The alteration in the consistency of the mass after treatment has been commented on by Bohm,<sup>16</sup> who stresses that a tuberculous hyperplastic mass, after anti-tuberculous treatment, may be indistinguishable from carcinoma of the colon. This therapy was also probably responsible for the absence of fistula formation after the operation. This complication was common before the advent of the modern anti-tuberculous drugs, and Kallqvist<sup>17</sup> maintains that the drugs have a prophylactic action against secondary intestinal tuberculosis. In spite of this, however, it is surprising that in our patient acid-fast bacilli were still found in the tuberculous mass and also that there was no change in the barium-

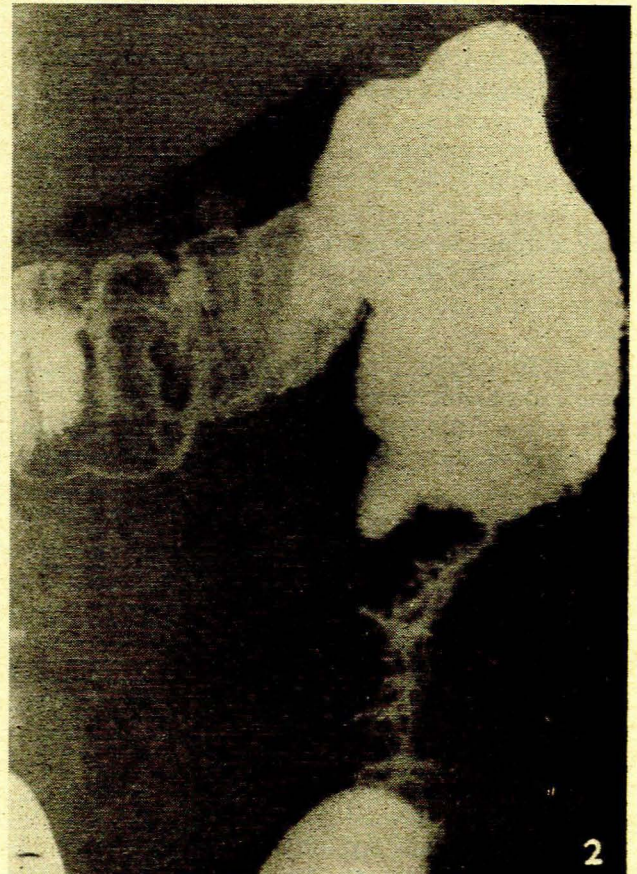


Fig. 2. View showing that the mucosa in the narrowed area is intact.

enema appearances, even after intensive treatment lasting 6 weeks.

## SUMMARY

A case of localized tuberculous lesion of the descending colon is described. This condition has been very rarely reported.

We should like to thank Dr. H. Clain for allowing us access to the radiological findings, and to the Superintendent of Baragwanath Hospital for permission to publish this case. We should also like to thank Dr. M. Schwartz for referring the case and Mr. Shewitz of the Department of Medicine for help with the photographs.

## REFERENCES

1. Illingworth, C. F. and Dick, P. M. (1943): *Text-book of Surgical Pathology*, 4th ed., p. 500. London: Churchill.
2. McLaughlin, A. I. G. (1933): *Lancet*, **1**, 1333.
3. Muir, R. (1941): *Text-book of Pathology* 5th ed., p. 564. London: Arnold.
4. Mitchell, R. S. and Bristol, L. J. (1954): *Amer. J. Med. Sci.*, **227**, 241.
5. Boles, R. S. and Gershon-Cohen, J. (1934): *J. Amer. Med. Assoc.*, **103**, 1841.
6. Goldfarb, S. J. and Sussman, M. L. (1931): *Amer. J. Roentgenol.*, **25**, 324.
7. Salvati, R. (1950): *Radiol. med.*, **36**, 932.
8. Randall, K. J. and Spalding, J. E. (1946): *Brit. J. Surg.*, **33**, 372.
9. Hickinbotham, P. (1950): *Ibid.*, **37**, 360.
10. Moak, H. (1902): *J. Med. Res.*, **8**, 128.
11. Guberman, M. O. (1903): *Med. Obozr. (Mosk.)*, **60**, 759.
12. Tauschwitz, K. (1910): *Inaug. Diss.*, Berlin. Quoted by Randall *et al.*<sup>8</sup>
13. Miller, J. K. (1936): *J. Amer. Med. Assoc.*, **107**, 1560.
14. Shanks, S. C. (1950): *Text-book of X-ray Diagnosis*, 2nd ed., vol. 3, p. 398. London: Lewis.
15. Eckey, P. (1953): *Strahlentherapie*, **91**, 476.
16. Böhm, F. (1954): *Röntgenstrahlen*, **81**, 15.
17. Kallqvist, I. (1951): *Amer. Rev. Tuberc.*, **6**, 430.