

CRETINISM : CASE REPORT AND DISCUSSION*

M. I. PAPILSKY, M.B., Ch.B., D.C.H.

Queenstown

As a general practitioner who sees a large number of children I have, during the last few years, come across many interesting cases. I have decided that it would be more interesting to select one of these patients and discuss the condition from which he is suffering than to talk on an abstract subject purely of academic interest.

CASE REPORT

The child was first seen at the age of 5½ months. He was the product of a healthy pregnancy and a normal confinement, weighing 6½ lb. at birth. The mother was a primipara aged 25 years, and there was no consanguinity between the parents.

All seemed to go well until the age of 4½ months, when the mother observed that the child was becoming obstinately constipated. He was breast-fed and the mother was not at first unduly alarmed by this symptom and did not seek advice. It is, as we know, not unusual or abnormal for a breast-fed child to defaecate

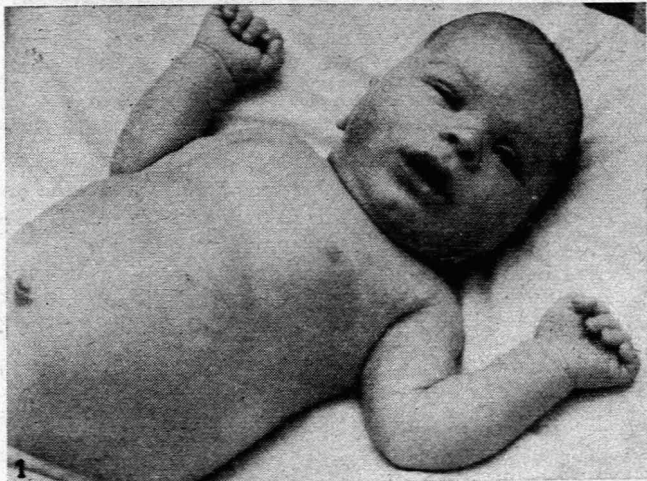


Fig. 1. Cretinous child aged 6 months, 5 April 1955 (before treatment).

only every second or third day. However, this child was worse than that, and when there was no response to the usual household remedies she brought him along to me. On inspection I saw that the child was a typical cretin (see Fig. 1). The clinical picture was characteristic and I hope you will pardon me if I describe the patient rather fully, for one does not see these cases frequently in general practice.

From the head downwards the following are the main features:

1. The hair is scanty, coarse and wiry.
2. The fontanelle is still wide open, whereas normally in a child of this age there ought to be some sign of closure.

* A paper read at a meeting of the Queenstown Division 26 April 1956.

3. The complexion is pale and sallow.
4. The eyelids are heavy and the palebral fissures narrowed.
5. The nose is squat and the lips thickened and negroid in appearance, with the tongue protruding from the mouth.

Other features present were large supraclavicular pads of fat, a protuberant abdomen and a small umbilical hernia. There was nothing remarkable about the heart, lung fields, E.N.T., etc. The length of the child was 22½ inches (the normal at 6 months is about 26 inches).

I was impressed with two other features in this case, viz.:

1. The extreme dryness of the skin, and
2. The hypotonicity of the musculature. One could twist the limbs into most peculiar positions with no discomfort to the child. (The protuberance or distension of the abdomen is due to the lack of tone in the abdominal musculature.)

On direct questioning the mother, strangely enough, said she had noticed nothing unusual about the baby and stressed what a good child it was. Incidentally, it behoves one always to be suspicious about any infant proclaimed to be very good, and to think of mental deficiency or serious illness. However, despite the alleged good behaviour of the child, it cried when I examined it and I was given the opportunity to hear the hoarse, croaking, bullfrog-like voice of the cretin.

One final observation at the initial examination was that the child was unable to support his head (which a normal child can do at 3 months) and had not yet smiled (which a normal child does at 6-8 weeks). So here was a child at 6 months, definitely retarded mentally and physically, and looking very dull.

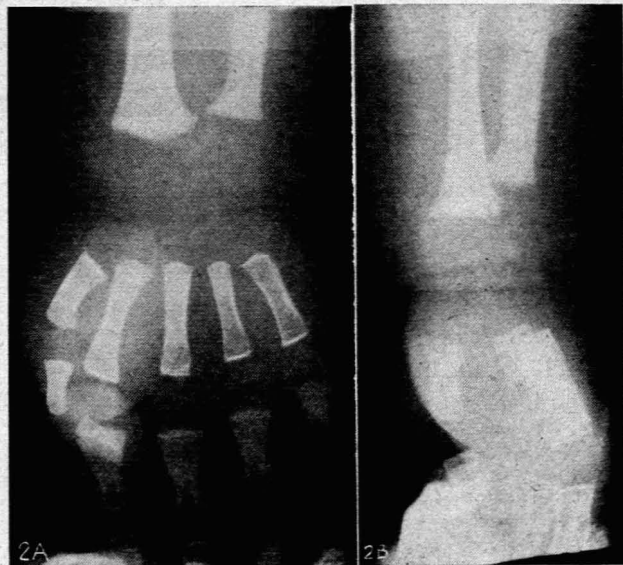


Fig. 2. A and B. Skiagrams of wrist of same cretinous child aged 6 months (before treatment), showing no ossification of carpal bones.

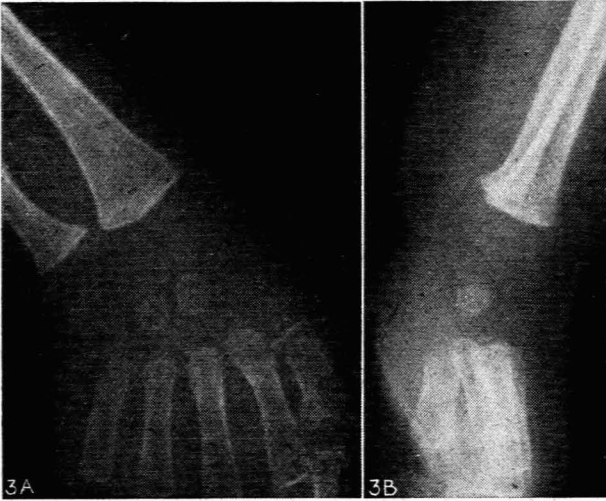


Fig. 3. A and B. Skiagrams of wrist of normal child aged 6 months, showing ossification of carpal bones.

Because of expense and distance from the laboratory, the chemical test carried out was the blood Cholesterol, which was 600 mg. %.

The X-ray of the wrist (Fig. 2) is interesting and when it is compared with the appearance in a normal child aged 6 months (Fig. 3) one can see how retarded the bone age is by the fact that the small bones of the wrist are entirely absent in the patient, whereas two are normally present at this age.

The child was put on thyroid immediately and the developmental pattern has since been completely normal, the child sitting without support at 8 months, standing at 1 year and walking well

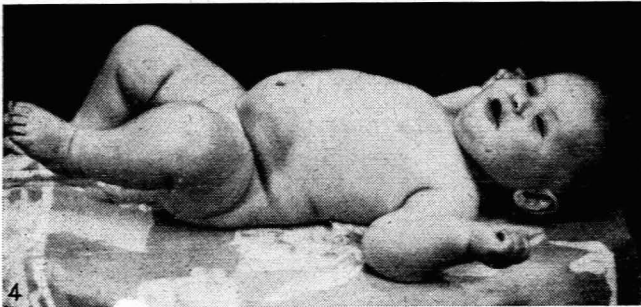


Fig. 4. Same child aged 13 months, 25 November 1955 (after treatment).

at 17 months, which are all well within normal limits. His appearance at 13 months (Fig. 4) is that of a normal child who is perhaps rather fat. The dryness of the skin disappeared after 2 months of treatment and his cry became normal.

DISCUSSION

I should now like to say something about the etiology, treatment, prognosis and differential diagnosis of cretinism.

Etiology

In the majority of cases the condition is sporadic and is due to partial or complete agenesis of the thyroid gland. I suppose one could call it a congenital deformity. Occasionally rudimentary thyroid tissue, which may possess some degree of activity may be found in the tongue or neck. There is, then, no thyroid gland present, and nothing to perform thyroid function, which is to synthesize thyroxine. It has been estimated that only 50 micrograms of thyroxine a day are necessary to maintain normal health. Without thyroxine the infant is unable to grow physically or

mentally and the picture of cretinism evolves. The condition does not become apparent in the first few months of life because the foetus inherits enough thyroid hormone to supply its needs for about 3-4 months. There may also be some hormone supplied by the secretion of a rudimentary gland, as mentioned above. It has been suggested that thyroxine can be transmitted post-natally in the breast milk.

Another cause of sporadic cretinism is deficiency of anterior pituitary thyrotropic hormone.

Sporadic cretinism is not hereditary and there is no fear that a subsequent child will be similarly affected, although there is one report in the literature of 3 siblings of Mexican descent born in 3 successive pregnancies and all afflicted. One can, however, reassure the parents that they need not fear another pregnancy.

Endemic cretinism is a different type of condition. It occurs in areas where goitres are common, owing to local deficiency of iodine, and may, naturally, affect more than one member of a family. This occurs in parts of Switzerland, Austria and Spain. In these cases the lack of thyroxine is due to iodine deficiency, and the treatment is to give iodine.

I should like to stress that what I have mentioned is by no means an exhaustive description of the possible etiological factors and does not embrace all the facets of thyroid endocrinology.

Treatment

Fortunately this is simple and merely consists of administering tablets of dry thyroid (B.P.). The preparation is cheap, and no other hormone can be relied upon to exert such profound benefit when given by mouth.

The initial dosage must be small and, in the present case, $\frac{1}{4}$ gr. daily was administered. Care must be taken in increasing the dosage and additions must be made gradually, usually by adding $\frac{1}{4}$ gr. every 14 days. The optimum dose for the individual case must obviously vary, but 1-2 gr. a day is aimed at.

An easy guide to dosage is the state of the bowels. I found that in this case when I pushed the dose up to $1\frac{1}{2}$ gr. the child developed diarrhoea and became irritable. If too little is given the patient remains constipated and does not develop. At present the patient is doing well on 1 gr. a day, but as he gets older I shall gradually increase the dose. Other signs of overdose are those of hyperthyroidism, which in a child would manifest itself as tremors, tachycardia and persistently bad behaviour.

Blood-cholesterol estimations at regular intervals may be of help in grading the amount of thyroid to be given. The blood cholesterol in this case was 160 mg. % in February 1956.

There are more elaborate tests, such as the estimation of protein-bound iodine and radio-active iodine studies, but these are expensive and impossible to do here. The basal metabolism rate is also difficult to determine in a child, for a large measure of cooperation on the part of the patient is essential in carrying out the test and one cannot expect this in a young baby.

It is of paramount importance to find the correct dose for the particular case; too much at the beginning of treatment may be fatal, and too much later on will interfere with the development of the child's personality and the most efficient use of the available mental capacity.

Prognosis

The longer the delay in diagnosis and the commencement of treatment, the worse the outlook. Congenital cretinism is a rare condition and there is some excuse for missing the diagnosis. Within 3-4 weeks after the commencement of therapy the metamorphosis begins and after a few months of treatment it is impossible to recognize the child as a cretin. There I should like to stress that in a child where growth has ceased, whether as the result of cretinism or of any other disease (e.g. pink disease or coeliac disease), when recovery takes place and growth proceeds rapidly it is essential to ensure that adequate vitamins are given, particularly vitamin D. Rickets will not occur in a marasmic child, but only during the recovery phase.

If the diagnosis is not made until the age of 2 $\frac{1}{2}$ -3 years, one may still get some improvement in the physical appearance, but the child will remain a mental deficient and a dwarf.

One cannot improve the intellect by pushing the dose of thyroid higher than is required to maintain normal metabolism. According to reports, some cretins have been able to win scholarships at school and some have grown up with severe mental retardation despite adequate and continuous treatment.

I hope that this particular patient may fall into the group of

cretins whose mental development under treatment is normal. Judging by the milestones to date there is no departure from the normal. Physical development, in a case like this, one can expect to be normal. Treatment must be continued throughout life.

Differential Diagnosis

During the last few years I have seen several cases of mongolism in infants who have been on treatment with thyroid in the erroneous belief that they were cretins. (There is no treatment for mongolism; glumatic acid had a vogue a few years ago, only to fail miserably.) The following are the main differential points:

1. The hair of the mongol is soft and of fine texture, that of the cretin wiry in nature.
2. The eyelids of the mongol are widely separated and the eyes slope upwards and outwards.
3. The complexion of the mongol is usually bright and pink, in contrast with the butter-coloured cretin.
4. 10% of mongols have associated congenital heart-disease.
5. Finally mongolism is recognizable at birth. In a difficult case blood-cholesterol levels will help, and also X-rays to determine the bone age which is retarded in the cretin and not in the mongol.