

PAROTID ENLARGEMENT IN MALNUTRITION

D. J. DU PLESSIS, M.Ch. (RAND), F.R.C.S. (ENG.)

Department of Surgery, University of Cape Town and Groote Schuur Hospital, Cape Town

Although the association between malnutrition and enlargement of the parotid salivary glands has been known for some considerable time,^{12, 13} malnutritional parotid enlargement is an entity which is not generally recognized; and for that reason one's personal experiences are recorded in this paper. The series presented is not a large one, being limited to cases seen incidentally in surgical practice; in a series of 131 patients with enlarged parotid salivary glands, in 17 the enlargement was due to malnutrition.

Of these 17 patients 16 were Africans and 1 a Coloured person. This racial incidence is probably attributable to the fact that the non-European races belong to the lowest income-group and are consequently more likely to suffer from malnutrition. Other races are not immune and the condition has been reported in Europeans.¹³

All the patients were males and although the condition has been described in females¹² this marked male preponderance has been noted before.^{10, 12} The significance of this sex difference is uncertain but may be due

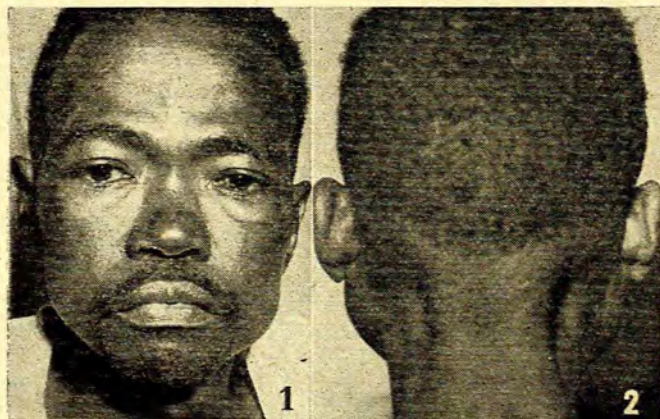
to an increased susceptibility of the male parotid gland to nutritional disturbances.¹⁰

The patients in this series were all adults with the one exception of a young boy of 10 (Dr. P. Suckling's patient) but this age incidence is not valid since I have no contact with sick children. In any case the condition is said to occur at all ages.¹²

In 2 patients only one side was affected (Fig. 1) and in the other 15 both glands were enlarged (Fig. 2), although in 6 of them the one side was more enlarged than the other. This coincides fairly closely with other reported series.^{12, 13} In this series none of the other salivary glands were involved but it has been reported that the submandibular and even the lacrimal glands may be similarly affected.^{10, 12}

HISTOLOGY

The cause of the parotid enlargement is an increase in size of the acini. A 55% increase in size of the acini has been reported previously.¹³ Fig. 3 compares the



Figs. 1 and 2.

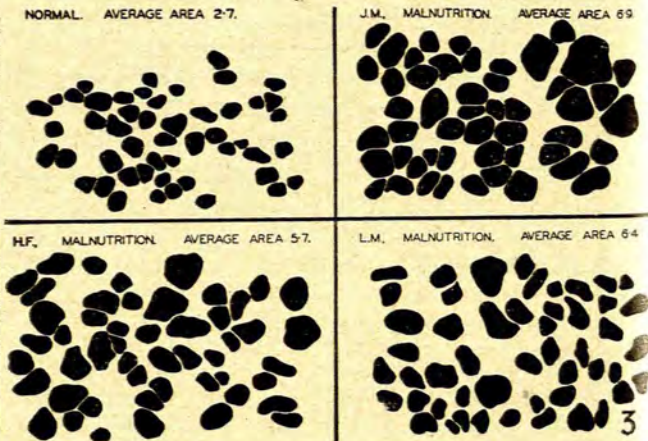
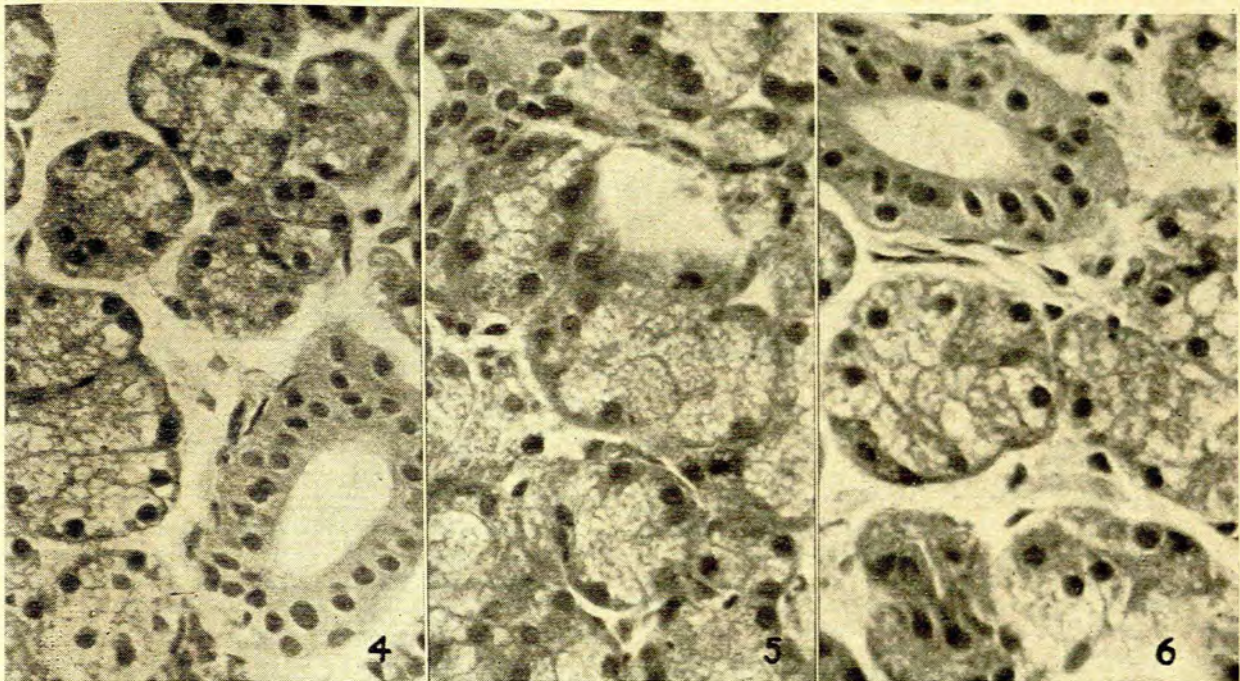


Fig. 3.

parotid acini in 3 cases of malnutrition and in a normal person; the outlines were obtained by means of a projection microscope and the surface areas were measured with a perimeter. It is possible that there may be an increase in the number of cells, but there is no evidence of cell multiplication and mitosis¹³ and hypertrophy¹⁰ which is responsible for the enlargement of the acini. The cells are distended with secretory granules which push the cell into contact with the basement membrane, displace the nuclei to the base of the cells and obliterate the little lumen usually seen in the centre of each acinus. This picture is clearly

reported—this has not been seen in the cases here reported, and the interpretation of these reports is difficult; possibly they represent a more advanced stage of the condition. It has been suggested that the parotid enlargement is due to fatty infiltration,¹ but this has not been seen in this series and in any case fat is a frequent finding in normal glands^{10, 13} and its presence should not be misinterpreted. An accumulation of fat in the parotids is probably the cause for the large parotids seen in very obese people.

In malnutritional enlargement the parotid glands are soft and painless and have a finely granular feel if palpated between the finger tips. The parotid duct,

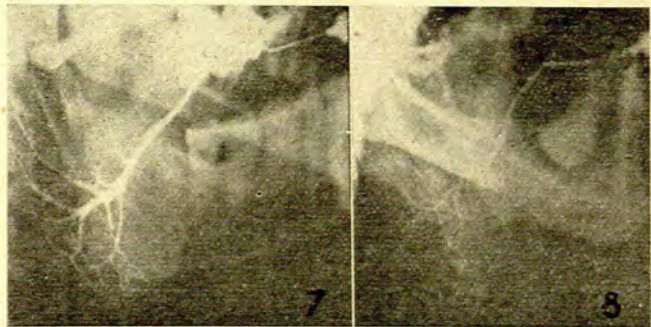


Figs. 4, 5 and 6.

demonstrated by Figs. 4, 5 and 6, from typical cases, but it must be kept in mind that the apparent accumulation of secretory granules with displacement of the nuclei is a normal appearance of the gland in a resting phase and so must not be considered characteristic of this condition. As a matter of fact it has already been reported that the large cells may be without any granules;¹⁰ possibly this occurred when the histological specimen was taken during or soon after secretion. The increase of the cells in size and obliteration of the lumen is not seen in normal glands, however.

The result of this acinar hypertrophy is that there appear to be relatively fewer ducts¹⁰ than normal, as they are pushed further apart by the enlarged acini. No other abnormality was detected histologically and McCance also could find no other abnormality in his cases.¹³ On occasions other abnormalities such as crowding of the acini by ductal hyperplasia¹² and acinar atrophy with fibrous replacement⁹ have been

duct orifice and saliva all appear normal macroscopically. The sialographic picture corresponds to the histological appearance, as the finer ductules are widely separated by the hypertrophied acini giving a characteristic 'leafless tree' appearance (Fig. 7) unlike the normal

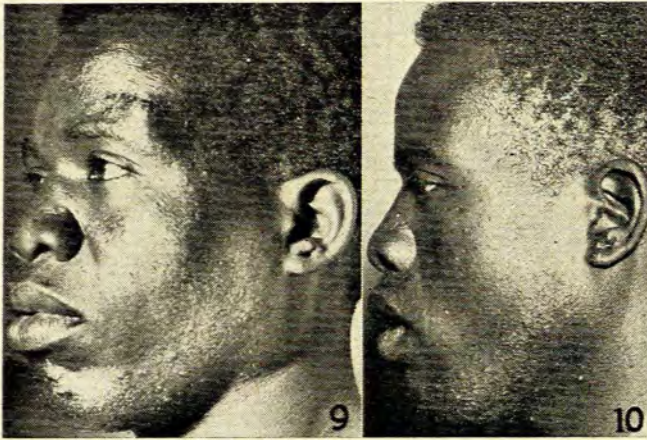


Figs. 7 and 8.

gland, which has the ductules much closer to each other (Fig. 8).

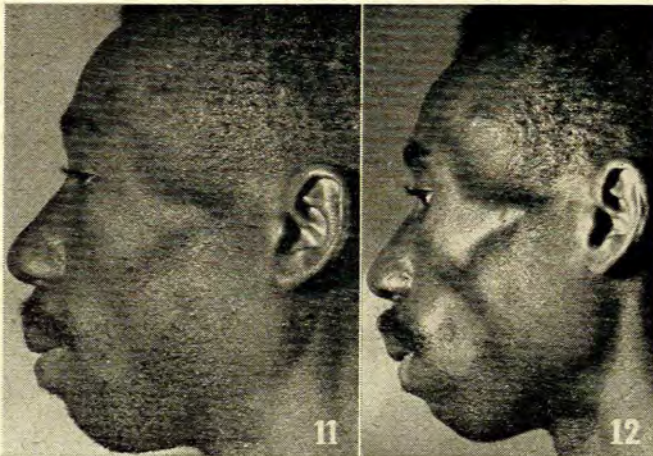
MALNUTRITION

Of the 17 patients, 10 had some obvious cause for malnutrition, such as carcinoma of the oesophagus (5 cases), carcinoma of the stomach (2), severe amoebiasis with liver abscesses, achalasia of the cardia and a psychogenic refusal to eat (1 case each). The parotid enlargement was found to be reversible after correction



Figs. 9 and 10.

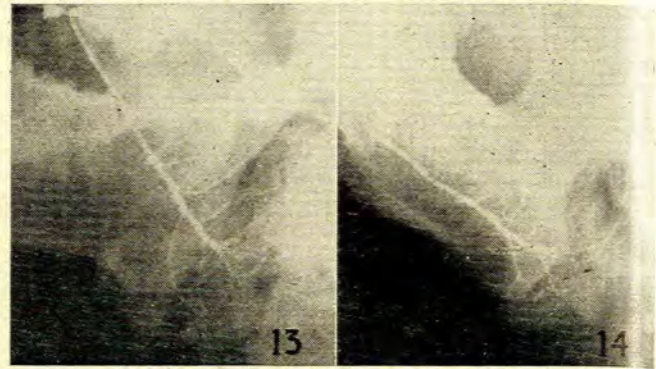
of the malnutrition. This is illustrated by the patient with the achalasia of the cardia (Fig. 9) who was virtually normal 6 months after dilatation of the cardia with a hydrostatic bag (Fig. 10). Another patient (under Professor J. H. Louw) was of particular interest. He had a carcinoma of the lower end of the oesophagus with parotid enlargement (Fig. 11). Resection of the



Figs. 11 and 12.

carcinoma was found to be impossible and so a gastrostomy only was performed and vigorous gastrostomy feeding instituted. Within 23 days there was a marked decrease in the size of the parotid glands (Fig. 12). The sialogram, too, was typical of malnutrition (Fig.

13) and it also reverted to normality after 23 days (Fig. 14). This case clearly demonstrates that it is a pure malnutrition effect and that the parotid enlargement is not a result of an exaggerated oesophago-salivary



Figs. 13 and 14.

reflex due to the presence of an obstructing lesion at the lower end of the oesophagus. It does not, however, exclude the possibility that the parotid swelling is due to hypertrophy following the prolonged stimulation of the gland induced by the oesophagitis of malnutrition.¹⁰

One can thus conclude that in malnutrition there is enlargement of the parotid glands due to hypertrophy of the cells constituting the acini, and that this may possibly be a 'work hypertrophy' following on prolonged stimulation of the gland by an exaggerated oesophago-salivary reflex originating in the oesophagitis of malnutrition. The condition is reversible if the malnutrition is corrected.

The other 7 patients reported here did not have any obvious cause for, nor other manifestations of, malnutrition and the parotid enlargement was a purely incidental finding. The lesion was in every way identical to that already described and one assumed that the parotid swelling was probably a result of a previous period of malnutrition (although such a history was not always obtained). This failure of the gland to revert to its normal size after recovery from malnutrition may be interpreted as the 'work hypertrophy' of the gland which has been described as coming on with the excessive chewing during recovery from malnutrition.⁵ It only occurs with a sudden increase of food after malnutrition,¹³ and particularly if there is a high proportion of bread in the diet.^{15, 16} This is probably also the explanation for the enlarged parotids sometimes seen in people who habitually overeat.

ASSOCIATED PATHOLOGY

Some attempt was made to assess the function of these enlarged glands by studying the salivary amylase and volume of secretion of a few cases. The salivary amylase varied within a wide range and no clear picture could be obtained, although it has been reported that about 40% of cases have a slightly raised serum amylase.¹² The volume of salivary secretion, obtained by means of a cannula inserted into the parotid duct, was lower than normal; but conclusions cannot justifiably be drawn from this finding because only a few cases were

investigated. However, of the few so examined, not one had a secretion of over 6 c.c. per hour under basal conditions 3 hours after the last meal, whereas the average in normal controls has been found to be 7.5 c.c. per hour. This finding is unexpected since an increased flow would be expected and sialorrhoea has previously been reported in this condition.^{10, 12} A possible explanation for this low salivary flow is that all the cases so investigated were patients with oesophageal obstruction, which possibly produced subclinical dehydration that was reflected in a low salivary secretion. One finding which tends to confirm that sialorrhoea does in fact occur was that on 2 occasions the volume of saliva decreased significantly after correction of the malnutrition and return of the gland to a normal size.

Other authors have reported a variety of functional disorders such as porphyrin-like fluorescence in the saliva,¹⁰ large amounts of thiocyanate in the saliva,¹⁰ increased response to pilocarpine,¹² and a high serum-content of pseudo-cholinesterase.¹³

One interesting observation which has been reported is that serous acini are much more susceptible to malnutrition than mucous acini,^{9, 10} which explains why the parotid glands, which consist almost entirely of serous acini, are more often affected than the mixed (serous and mucous) submandibular glands. If the latter are affected then the serous acini only are involved until a late stage, when the mucous acini also become affected.⁹

As can be expected, malnutritional parotid enlargement is often seen in association with other manifestations of malnutrition such as pellagra,¹⁰ cirrhosis of the liver,^{1, 10} and gynaecomastia⁷—the latter was encountered in 3 of the patients reported here. It is possible that the testicular or hepatic lesions seen with malnutrition produce a disturbance of hormonal balance which in turn is responsible for the parotid enlargement.¹⁰

It has been pointed out that 10% of the patients with malnutritional parotid enlargement also show diabetes,¹² but it must be kept in mind that parotid enlargement is not uncommon in diabetes.^{1, 3} A hyperglycaemic^{2, 3, 11} as well as a hypoglycaemic factor^{4, 14} has been found in the parotid; certain workers consider the parotid enlargement in diabetes to be a compensatory mechanism to produce a blood-sugar lowering factor in hypo-insulinism^{6, 7} and attempts have even been made to encourage the absorption of this factor by ligation of the parotid duct to lower the blood-sugar.¹⁷ It is, however, uncertain whether significant amounts of either factor are secreted by the parotid,^{1, 8} and in this series diabetes was not encountered.

The treatment is obviously to correct the malnutrition, keeping in mind that excessive eating of bread especially may in turn produce parotid enlargement. Deep X-ray therapy also produces a significant effect on the glandular enlargement,¹² but it is not usually required.

SUMMARY

Parotid enlargement occurs during malnutrition. It is due to hypertrophy of the cells of the gland and the condition is reversible with a return to adequate nutrition. This condition is particularly common in males and is possibly due to a work hypertrophy following excessive stimulation of the gland by malnutrition changes in the oesophagus.

A similar condition occurs in people who are recovering from malnutrition, particularly if the feeding is rapid and a large amount of bread is consumed. This may be a work hypertrophy due to the excessive stimulation by the chewing of the bread in the diet.

I wish to thank the Superintendent of the Groote Schuur Hospital for permission to report these cases; the clinicians who have referred many of these cases to me; the hospital X-ray Department for their co-operation; the Pathology Department of the University of Cape Town for their assistance, and Dr. Kihn for the needle biopsies of some of the cases.

The expenses of this report have been defrayed by a grant from the Dr. C. L. Herman Research Fund.

REFERENCES

1. Annotation (1954): *Lancet*, **2**, 1008.
2. Birnkrant, W. B. (1941): *J. Lab. Clin. Med.*, **26**, 1009.
3. Birnkrant, W. B. and Shapiro, R. (1942): *Ibid.*, **27**, 510.
4. Cahane, M. and Cahane, F. (1941): *Rev. franç. Endocr.*, **8**, 398 (after Birnkrant *et al.*³).
5. Davies, J. N. P. (1948): *Lancet*, **1**, 317.
6. Dobreff, M. (1936): *Dtsch. med. Wschr.*, **62**, 67.
7. Ferretti, G. (1936): *G. Clin. med.*, **17**, 1305.
8. Gault, S. D. (1954): *J. Lab. Clin. Med.*, **43**, 119.
9. Gillman, J., Gilbert, C. and Gillman, T. (1947): *S. Afr. J. Med. Sci.*, **12**, 99.
10. Gillman, J. and Gillman, T. (1951): *Perspectives in Human Malnutrition*. New York: Grune and Stratton.
11. Hiki, Y., Akazaki, K., Bann, T., Miyazaki, Y. and Takizawa, N. (1932): *Trans. Soc. path. jap.*, **22**, 273 (after Birnkrant *et al.*³).
12. Kenawy, M. R. (1937): *Trans. Roy. Soc. Trop. Med. Hyg.*, **31**, 339.
13. McCance, R. A., Dean, R. F. A. and Barrett, A. M. (1951): *Spec. Rep. Ser. Med. Res. Coun. (Lond.)*. No. 275, p. 135. London: H. M. Stat. Office.
14. Takacs, L. (1933): *Orv. Hetil.*, **77**, 659 (after Birnkrant *et al.*³).
15. Widdowson, E. M. and Thrussell, L. A. (1951): *Spec. Rep. Ser. Med. Res. Coun. (Lond.)* No. 275, p. 296. London: H. M. Stat. Office.
16. Widdowson, E. M. (1951): *Ibid.*, p. 313.
17. Zimmerman, L. M. (1932): *Arch. Intern. Med.*, **49**, 409.