

# INTERLOCKED TWINS: A CASE REPORT AND BRIEF REVIEW OF THE LITERATURE

ROBIN GORDON, M.B., B.CH. (RAND)

*Gynaecological House Surgeon, Victoria Infirmary, Glasgow\**

The occurrence of locked twins is a rare event. The incidence is variously given as 1 in 1,000 twin deliveries or 1 in 90,000 of all deliveries.<sup>1</sup> The following case occurred in the Maternity Department of the King Edward VIII Hospital, Durban, on 3 December 1955.

## CASE REPORT

A 19-year-old Bantu girl, M.P., gravida 2, para 1, reached the labour ward at 2 p.m. on 3 December. She had had no antenatal care and, although dirty and untidy, looked quite healthy. Her first pregnancy, in 1953, had resulted in the normal birth of a male infant (weight unknown), who died in infancy. Blood pressure was 110/70 mm. Hg, and no peripheral oedema was present. She appeared to be advanced in the second stage of labour—a labour which had begun 13 hours earlier—and the membranes had ruptured. Her abdomen was mountainous, and plural pregnancy was suspected. It was, however, impossible to verify the diagnosis on account of the strong uterine contractions and consequent difficulty in identifying foetal parts or heart sounds. Within minutes of the unsatisfactory abdominal examination, buttocks were seen to appear at the vulva, and the patient was hastily positioned for a breech delivery. An unassisted breech delivery was then partially accomplished with no difficulty, including delivery of the arms. The incompletely delivered breech was allowed to hang for fully 2 minutes to maintain flexion and en-

courage descent (Burns-Marshall technique<sup>2</sup>), while a right medio-lateral episiotomy was performed under 2% local procaine anaesthesia. A hand was then passed into the vagina with the object of reaching the mouth in order to complete delivery of the head

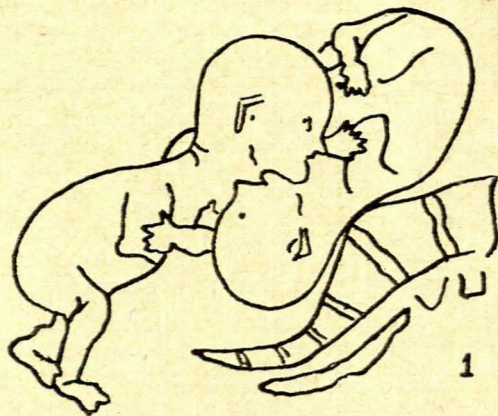


Fig. 1. Shows the positions of the 1st twin, a breech, and the 2nd twin, a vertex. Note, in addition, the prolapsed arm of the 2nd twin. (After Kimball and Rand<sup>5</sup>, *American Journal of Obstetrics and Gynecology*.)

\* Previously Obstetrical Registrar, King Edward VIII Hospital, Durban.

by the Mauriceau-Smellie-Veit method.<sup>3</sup> This internal hand discovered a second head engaged in the pelvis just below ischial spine level and in the hollow of the sacrum. The neck of the undelivered breech was elongated and pushed up anteriorly against the symphysis pubis. The head of the undelivered breech was still above the pelvic brim and situated towards the right iliac fossa.

Under general anaesthesia, the diagnosis of locked twins was confirmed. Not only was the head of the second twin engaged in the pelvis together with the neck of the first, but furthermore the right arm of the second twin was prolapsed. (The presentation was indeed compound, the situation complex!). The cervix was fully effaced. The mid-cavity and pelvic outlet were adequate in size. There was already marked moulding of the cranium of the second twin.

An attempt was made to disimpact the second twin's head, but the locking was too firm, nor could the prolapsed arm be replaced. By this time, the partially delivered foetus was dead and, as no foetal heart sounds of the second twin were heard after careful and systematic listening, it was assumed that it too had died. Both foetal skulls were then perforated in turn; first that of the second twin, which was easily reached after upward traction of the breech of the first twin. With the head in the pelvis perforated and collapsed, leg traction on the first twin in a downward direction brought more of its elongated neck into view, and one was then able to perforate this head posteriorly through the occipital bone without danger of trauma to the maternal soft tissues. Finally, simple traction on the prolapsed arm of the second twin also brought about its delivery.

The third stage of labour was uncomplicated. There were two placentae. Examination of the twins after delivery showed them to be mature, well-developed and comparatively heavy. The first was a female weighing 5 lb. 6 oz., the second a male weighing 5 lb. These weights did not include that of the brain tissue lost after perforation and delivery, which might be conservatively estimated at 10 oz. in each case.

The patient left hospital on the 10th post-partum day.

#### COMMENT AND DISCUSSION

Twins, during labour, may truly interlock or alternatively only collide in the pelvis, and there are 4 main ways in which this locking or collision may be brought about.

1. Two presenting vertices enter the pelvis side by side and progress is arrested by the second foetal head being driven down between the thorax and head of the first. Cunningham<sup>4</sup> describes such a case. He refers to his case as one of 'jammed twins', and points out that it is less formidable than the next type to be described.

2. The first twin presents by the breech, and the second by the vertex. Here, the aftercoming head of the first twin is arrested at the pelvic inlet by its chin becoming locked with the chin of the second twin. This is true chin-to-chin interlocking of twins, and the case reported in this article is of this type. Kimball and Rand<sup>5</sup> state that this situation of chin-to-chin locking makes up only a very small proportion of the total locked twins reported, so that its occurrence must indeed be extremely rare. Leonhard's table of the disposition *in utero* of the foetuses in twin labours—a table based on an analysis of 1840 twin labours—shows that the combination of a breech followed by a vertex occurs only in 14.3% of all twins.<sup>6</sup> All authors seem agreed that decapitation of the first twin is necessary to undo the locking before delivery of the second twin is possible. It may therefore be fairly asked why this line of treatment was not carried out in the case reported. Greig,<sup>7</sup> in 1946, when faced with this problem had managed to push the vertex of the second twin from ischial-spine level up out of the pelvis, and by so doing, disentangled

the locked foetuses. A living 4 lb. 10 oz. breech was then born, followed by a 5 lb. 3 oz. vertex birth. In our own case, however, the babies were heavier and manipulations further handicapped by prolapse of an arm alongside the vertex of the second twin. The decision to perforate and so collapse the second twin's head as the initial step in the treatment, was made because it was felt that decapitation of the first twin would be risky as well as extremely difficult, since its elongated neck lay elevated hard up against the under surface of the subpubic arch, and one feared injuring the urethra or neighbouring maternal soft parts. After perforation of the second head and later perforation of the first twin's head almost an hour had elapsed, yet the mother's condition remained good.

3. This group presupposes two breeches attempting to engage simultaneously. The breeches may both be fully flexed, or prolapse of up to 4 legs may occur.

4. In the final group, the first twin, whether a vertex or a breech, catches on some part of the anatomy of the second twin, which is lying transversely in the uterus.

#### Aetiology

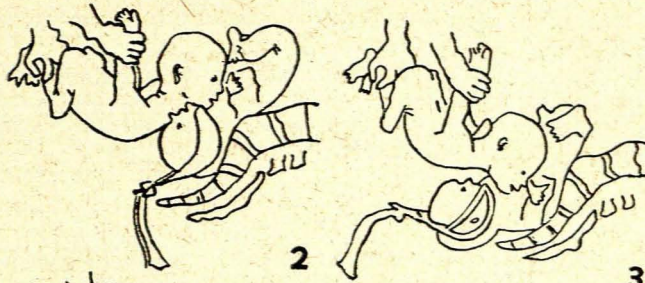
There appear to be several predisposing factors in the aetiology of locked twins. The actual combination of circumstances initiating the mechanism would appear to be fortuitous.<sup>8</sup> The predisposing factors are small foetuses, an unduly roomy pelvis, oligohydramnios, mono-amniotic twins, and extension of the leading head. Deficiency of liquor amnii, according to Cunningham,<sup>4</sup> is the theory which receives most support. Miles Phillips states that the loss of liquor from both sacs causes locking.<sup>9</sup> Wright<sup>10</sup> dealt with 3 cases of locked twins and has stated that a normal amount of liquor in each foetal sac will probably prevent locking, but that a liquor deficiency in the second foetal sac favours the accident. Lawrence,<sup>11</sup> reviewing 28 cases of locked twins since 1907, found that 23 were in primigravidae and regarded this as a strong predisposing factor. No opinion can be given about any aetiological factor in the case reported, for the liquor had drained away before admission.

#### Foetal Loss

A high foetal mortality can be expected as a result of this complication. Lawrence<sup>11</sup> showed in his review in 1949 that the leading twin is stillborn in nearly 60% of cases. Lattuada<sup>12</sup> describes a case of locked twins in which the first presented as a breech and the second as a vertex. The vertex became impacted against the chest of the first and, after delivery, a crush deformity of the anterior thoracic cage was noted in the first twin.

#### Treatment

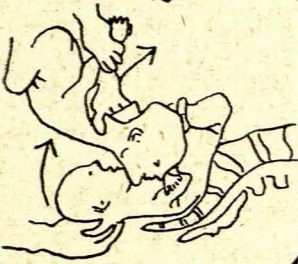
After timely diagnosis of locked twins, and in order to secure live infants, Caesarean section will offer the greatest chance of success. The treatment, however, may be prejudiced by late diagnosis, by intra-uterine death or by infection, in which case, some form of destructive operation will be preferable (MacLennan<sup>13</sup>). A unique method of simultaneous delivery of chin-to-chin locked twins was described by Kimball and Rand<sup>5</sup> in 1950. While an assistant holds up the undelivered breech by



2

Fig. 2. Shows the assistant's hands, holding the extremities of the undelivered breech up while the Piper forceps were applied below to the vertex of the 2nd twin.

Fig. 3. Shows the positions of the two heads at the completion of the delivery of the vertex of the 2nd twin.



4

Fig. 4. Shows the manoeuvre for producing simultaneous<sup>5</sup> delivery; the arrows show the direction of the manual traction to be used. (After Kimball and Rand,<sup>5</sup> *American Journal of Obstetrics and Gynecology*.)

the extremities, Piper forceps are applied below to the vertex of the 2nd twin. After completion of the delivery of the vertex of the 2nd twin, simultaneous delivery of both twins is effected by manual traction. These manoeuvres are illustrated in Figs. 2, 3 and 4.

#### SUMMARY

1. A case of chin-to-chin locked twins is described, which occurred at the King Edward VIII Hospital, Durban.

2. Interlocking or collision of twins is a rare obstetrical complication, occurring in 1 in 1,000 twin labours. It cannot be predicted before the onset of labour.

3. Four groups of different types of locking mechanisms are described, with brief references to illustrative cases.

4. The treatment, ideally, is Caesarean section in order to obtain live infants, but often a destructive operation is performed. A method of simultaneous delivery of chin-to-chin locked twins, using Piper forceps, is illustrated.

I should like to thank Dr. S. Disler, Medical Superintendent of King Edward VIII Hospital, Durban, for permission to publish the case reported. I also thank Dr. D. Geldenhyts, who assisted me with the deliveries, and Dr. A. Cilliers, the anaesthetist. In the preparation of this article, and for helpful advice, I am indebted to Dr. Hector MacLennan, Consultant Gynaecologist, The Victoria Infirmary, Glasgow, Scotland.

#### REFERENCES

- Holland, E. L. (1955): *British Obstetric Practice*, p. 644 London: Heinemann.
- Burns, J. W. (1934): *J. Obstet. Gynaec. Brit. Emp.*, **41**, 923.
- Holland, E. L. (1955): *Op. cit.*,<sup>3</sup> p. 617.
- Cunningham, W. D. (1947): *Med. J. Austral.*, **1**, 494.
- Kimball, A. P. and Rand, P. R. (1950): *Amer. J. Obstet. Gynec.*, **59**, 1167.
- Baird, D. (1950): *Combined Textbook of Obstetrics and Gynaecology*, p. 690. Edinburgh: Livingstone.
- Greig, D. S. (1946): *Brit. Med. J.*, **1**, 13.
- Macintyre, I. D. and Barr, G. M. (1951): *Ibid.*, **1**, 1123.
- Nicolson, E. L. (1942): *J. Obstet. Gynaec. Brit. Emp.*, **49**, 162.
- Wright, S. W. (1942): *Lancet*, **2**, 212.
- Lawrence, R. F. (1949): *J. Obstet. Gynaec. Brit. Emp.*, **56**, 58.
- Lattuada, H. P. (1951): *Amer. J. Surg.*, **81**, 448.
- MacLennan, H. R.: Personal communication.