

UPTAKE OF IODINE-131 BY AN 18-WEEK HUMAN FOETUS

D. J. GOLDSTEIN, B.Sc.HONS., M.B., B.Ch.

*Radiotherapy Department, Non-European Hospital, Johannesburg**

It is now widely recognized that the therapeutic and diagnostic use of radiation carries with it certain hazards both to the individual and to the species. These dangers are greater when exposure of infants or foetuses is involved, and have been experimentally demonstrated by work on animals. For example, Speert *et al.* (1951) administered ^{131}I to pregnant mice, and found that not only was the growth of the offspring retarded, but that fibrosis and adenoma formation occurred in the thyroid, followed later, in a large percentage of cases, by goitre formation and chromophobe adenomas of the pituitary.

The uptake of ^{131}I by human foetuses in the early stages of pregnancy has been studied by Chapman *et al.* (1948), Marinoni (1951) and Hodges *et al.* (1955), and has been shown to occur as early as at $14\frac{1}{2}$ weeks of gestation. While these workers measured the uptake of ^{131}I by the foetal thyroid,

* Now of the Department of Anatomy, University of the Witwatersrand, Johannesburg.

the mass of thyroid tissue was not recorded, and therefore the specific uptake of ^{131}I per gram of thyroid tissue cannot be calculated.

Instances of the administration of therapeutic doses of ^{131}I to thyrotoxic pregnant women without termination of pregnancy are recorded by Chapman *et al.* (2 cases) and Hodges *et al.* (1 case), and in all three cases the offspring were reported to be apparently normal 1 or 2 years after birth. The ^{131}I was administered at 8, 19 and 24 weeks of pregnancy, and the impression is gained from these cases that the therapeutic use of ^{131}I at these stages of pregnancy carries little danger to the foetus.

At the Non-European Hospital, Johannesburg, the opportunity arose recently of studying the uptake of ^{131}I by an 18-week human foetus. The results obtained indicated that the administration of ^{131}I to a pregnant woman involves greater danger to the foetus than appears from earlier work, and the case is accordingly here reported in some detail.

CASE REPORT AND METHODS

Mrs. R.S., a 27-year-old African woman, was admitted to Baragwanath Hospital, Johannesburg, in November 1956 complaining of a painless swelling of the neck for 1 year, and a painful swelling over the sternum for 2 months. She had 2 children, aged 2 and 7 years, and her last menstrual period was reported to have been at the end of October. This menstrual history, however, was probably inaccurate.

On examination, a mass about 6 cm. in diameter was found in the left lobe of the thyroid, and a large, firm, tender mass was present over the upper half of the sternum. No signs of thyroid dysfunction were present. A biopsy of the sternal mass revealed a secondary carcinoma, probably of thyroid origin, and a total thyroidectomy was performed at Baragwanath Hospital on 26 November. The mass in the thyroid was found to be a carcinoma, and the patient was transferred to the non-European Hospital, Johannesburg, for radiotherapy.

On 18 December a tracer dose of 0.56 mC ^{131}I was administered orally, and a scintigram on 20 December revealed marked uptake by the secondary deposit over the sternum and no functioning thyroid tissue in the neck.

A *Xenopus* pregnancy test in December was positive, and it was decided to terminate the pregnancy before the administration of a therapeutic dose of ^{131}I . On 31 December the patient's cervix was dilated to size 14 Hegar under general anaesthesia and the foetal membranes were ruptured. However, the foetus did not abort.

On 3 January 1957 71.5 mC ^{131}I was administered orally, and the volume of the secondary deposit over the sternum was estimated with the aid of lateral roentgenograms and a plaster cast of the protuberant mass. The next day (4 January) the activity of ^{131}I in the mass was measured approximately, with the aid of a 'Tracerlab' Ionization-type Survey Meter (previously calibrated against a known quantity of ^{131}I) held at a known distance from the mass.

On 9 January the pregnancy was terminated by abdominal hysterotomy and an apparently normal 18-week male foetus delivered (crown-rump length 16 cm., weight 276 g.). The whole foetus was fixed in 10% formalin, and on 11 January the thyroid was carefully dissected out. The thyroid was weighed, and the radio-activity of the foetus, foetal thyroid, and placenta measured separately with an 'Ecko' Scintillation Counter.

Paraffin sections of the foetal thyroid were prepared, and autoradiographs made with 'Kodak' Autoradiographic Stripping Plate AR. 10.

RESULTS

The radio-activity of the maternal secondary carcinoma, the foetus, the foetal thyroid, and the placenta, is given in Table I.

TABLE I

	Weight	Activity	Specific Activity
Maternal secondary carcinoma	About 150 g.	About 40 mC	About 165 $\mu\text{C/g.}$
Foetus276 g.	87 μC	0.315 $\mu\text{C/g.}$
Placenta222 g.	58 μC	0.270 $\mu\text{C/g.}$
Foetal thyroid	100 mg.	38 μC	380 $\mu\text{C/g.}$

1. The foetus and placenta were weighed to the nearest gram, and the foetal thyroid to the nearest 5 mgm.

2. The activity of the maternal secondary deposit was measured on 4 January, i.e. 24 hours after administration of the ^{131}I . The activity of the foetus, placenta and foetal thyroid was measured on 11 January, i.e. 8 days after administration. No allowance is made in the table for radio-active decay.

Histologically, the foetal thyroid contained a few follicles enclosing deeply stained colloid. These more mature follicles were mainly situated peripherally in the organ, and most of the follicles present were immature and contained little or no colloid (Fig. 1). An occasional pyknotic nucleus was present, but no changes definitely attributable to radiation

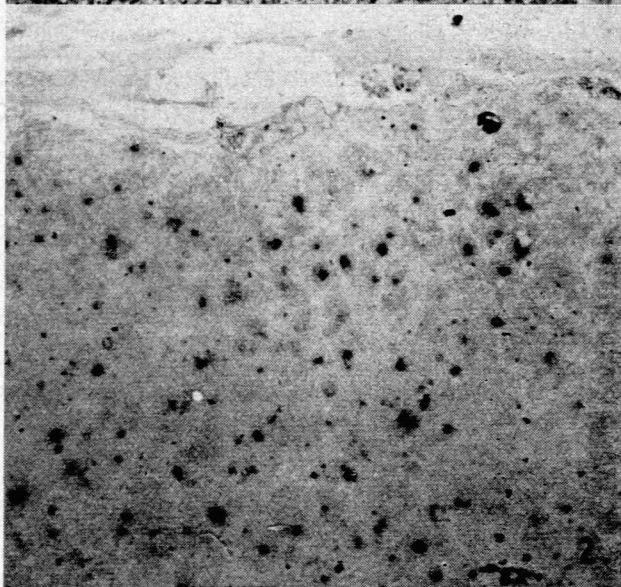
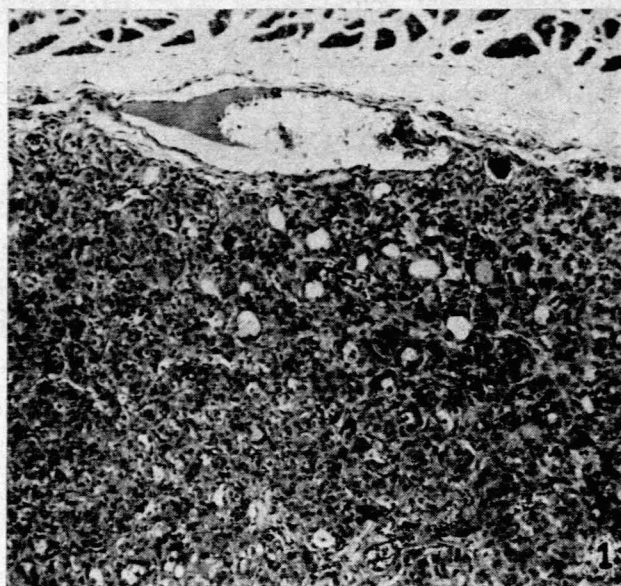


Fig. 1. Low-power photomicrograph of 18-week foetal thyroid, stained with H. & E. Note the presence of colloid in the more mature follicles, and the absence of colloid in many of the follicles.

Fig. 2. Photomicrograph of an autoradiograph of a similar section from the same thyroid. Note the marked uptake of ^{131}I by many follicles still in an immature condition.

damage were noted. The autoradiograph (Fig. 2) showed marked uptake of the ^{131}I by many follicles, including some that apparently contained little or no colloid. Where a follicle contained appreciable quantities of colloid, most of the activity was present in the colloid.

COMMENT

Histology and Autoradiograph

In view of the earlier unsuccessful attempt at termination of the pregnancy, the normal histological appearance of the

thyroid is important, since it has been shown (Trunell *et al.*, 1953) that necrotic tissues take up more radio-iodine than any normal tissues except thyroid. The absence of signs of radiation damage is consistent with the work of Freedberg *et al.* (1952b), who found no histological changes in normal human thyroids 7 days after the administration of 17-20 mC of ^{131}I , a time at which there was likely to be already marked functional impairment of the gland.

Chapman *et al.* (1948) associated the onset of function of the foetal thyroid with the appearance of definite follicles containing colloid. In the present autoradiographs the radio-iodine is present not only in colloid-containing follicles, but also in immature follicles containing little or no colloid. This is consistent with the findings of Koneff *et al.* (1949), who reported organically bound iodine in the thyroids of foetal calves before the appearance of histologically detectable intracellular colloid or follicle formation.

Quantitative uptake of ^{131}I by the foetal thyroid

The uptake of the ^{131}I by the foetal thyroid, as compared with the rest of the foetus, is similar to that found by Speert *et al.* (1951) in foetal mice.

The dose of radiation in rads received by an organ containing ^{131}I is given by the expression

$$D=14.45 At, \text{ where } A \text{ is the initial concentration of the isotope in } \mu\text{C/g.}, \text{ and } t \text{ is the effective half-life, in days (de Valencé 1957).}$$

The effective half-life is some fraction of the physical half-life, and is a function of the loss of iodine from the tissue, in addition to the radio-active decay. It will be noted that in the present case the initial concentration of isotope in the foetal thyroid is unknown, and the only measurement available is the concentration 8 days after administration. The initial concentration 'A' bears the following relationship to the concentration 'a' 8 days later:

$$a=Ae^{-8K}, \text{ where } e \text{ is the base of the natural logarithms, and } K \text{ is the decay constant given by the expression } Kt=0.693.$$

Although the effective half-life is unknown, and the exact dose received by the thyroid is therefore also unknown, it can be calculated that the *minimum* dose received by the foetal thyroid is of the order of 80,000 rads. This dose corresponds to an effective half-life of 5.54 days; for any other value of the effective half-life the calculated dose would be larger. Of the assumptions implicit in this result the only one which is likely to increase the calculated result is the assumption that all the radiation emitted by the isotope in the foetal thyroid will act on thyroid tissue; in the case of a small mass of thyroid, a certain proportion of the radiation will in fact escape into the surrounding tissues.

A dose of 80,000 rads is far in excess of that which produces gross pathological changes in an adult thyroid (Freedberg *et al.*, 1952a and 1952b), and it is therefore extremely likely that the foetus, if allowed to live, would have suffered from thyroid dysfunction and perhaps other pathological changes as well (Speert *et al.*, 1951). It should be noted that the initial concentration of ^{131}I in the foetal thyroid was more than 4 times that in the maternal secondary carcinoma.

In comparing the above results with those of Chapman *et al.* (1948) and Hodges *et al.* (1955), several points should be considered, although their relative significance is hard to

assess. Firstly, in the previous cases the weight of the foetal thyroid was not recorded, and the dose of radiation is therefore impossible to calculate. Secondly, the dose of ^{131}I administered here for carcinoma of the thyroid was several times greater than that given to their patients for thyrotoxicosis. Thirdly, the percentage uptake of ^{131}I by local African patients has been found to be somewhat higher than that reported from some other parts of the world (Cohen, 1957), possibly reflecting a difference in the iodine content of the diets. Finally, as discussed by Hodges *et al.* (1955), the uptake of ^{131}I by the foetus in their series of cases may have been affected by the fact that the mothers were thyrotoxic.

APPENDIX

CALCULATION OF THE MINIMUM DOSE OF RADIATION RECEIVED BY THE FOETAL THYROID

$D=14.45 At$, where D is the dose in rads, A is the initial concentration of ^{131}I in $\mu\text{C/g.}$, and t is the effective half-life, in days

$$a=Ae^{-8K} \dots \dots \dots (1)$$

where a is the concentration of ^{131}I after 8 days, and K is given by the expression

$$Kt=0.693 \dots \dots \dots (3)$$

From equation (1), substituting values of A from equation (2) and of t from equation (3), one obtains the equation

$$\begin{aligned} D &= 14.45 At \\ &= 14.45 A \cdot 0.693 / K \\ &= 10K^{-1}ae^{8K} \end{aligned}$$

$$\frac{dD}{dK} = 10 aK^{-1}e^{8K}(8-K^{-1})$$

$$= 0 \text{ for a maximum or a minimum,}$$

whence $K=1/8$ for a minimum, and $t=5.54$ days.

Substituting this value of t in equation (1) one obtains a value of D =about 83,000 rads.

SUMMARY AND CONCLUSIONS

71.5 mC of ^{131}I was administered to an African woman for carcinoma of the thyroid with secondaries. An 18-week foetus was delivered by abdominal hysterotomy 6 days later, and the foetal thyroid was found to contain enough radio-iodine to ensure a dose of radiation of at least 80,000 rads. By autoradiography ^{131}I was found even in immature follicles containing little or no colloid.

It is concluded that the administration of therapeutic doses of ^{131}I to women in this stage of pregnancy is unjustifiable, unless one is prepared to terminate the pregnancy.

This work was conducted under the supervision of Dr. P. Keen, Superintendent of the non-European Hospital, Johannesburg, and of Dr. L. C. Cohen, Senior Radiotherapist at the Johannesburg General Hospital. I should like to thank them for permission to publish this case. A supply of autoradiographic material was obtained through the courtesy of the Department of Botany, University of the Witwatersrand.

REFERENCES

- Chapman, E. M., Corner, G. W., Robinson, D. and Evans, R. D. (1948): *J. Clin. Endocr.*, 8, 717.
 Cohen, L. C. (1957): Personal communication.
 Freedberg, A. S., Kurland, G. S., Chamovitz, D. L. and Ureles, A. L. (1952a): *J. Clin. Endocr.*, 12, 86.
 Freedberg, A. S., Kurland, G. S. and Blumgart, H. L. (1952b): *Ibid.*, 12, 1315.
 Hodges, R. E., Evans, T. C., Bradbury, T. and Keettel, W. C. (1955): *Ibid.*, 15, 661.
 Koneff, A. A., Nichols, C. W., Wolff, J. and Chaikoff, I. L. (1949): *Endocrinology*, 45, 242.
 Marinoni, U. (1951): *Folia endocr.*, 4, 637.
 Speert, H., Quimby, E. H. and Werner, S. C. (1957): *Surg. Gynec. Obstet.* 93, 230.
 Trunell, J. B. and Brayer, F. T. (1953): *J. Clin. Endocr.*, 13, 88.
 de Valencé, L. P. (1957): Personal communication.