

Awareness of Tuberculosis

T. F. B. COLLINS

SUMMARY

Delay in diagnosis of pulmonary tuberculosis resulted in the death of 2 patients from the disease, a fatal outcome for a further patient whose cause of death was not determined, and led to extensive lung destruction in 2 others. A plea is made for early investigation of patients presenting with symptoms suggestive of pulmonary tuberculosis.

S. Afr. Med. J., 48, 2579 (1974).

In a recent publication¹ the attention of medical practitioners in the UK was drawn to the necessity for a continuing awareness of tuberculosis as a cause of long-standing respiratory symptoms. The authors described a family outbreak of tuberculosis in which 5 young children were infected by the father who had chronic bilateral cavitory pulmonary tuberculosis, diagnosed 4 months previously as bronchitis. Tuberculous meningitis presented simultaneously in 2 of the children, with a fatal outcome in 1 of them. The danger of treating adults for persistent bronchitis without investigation was emphasised.

Pulmonary tuberculosis is a disease of considerably higher prevalence in the Republic of South Africa than is the case in Britain, and it should not be necessary to

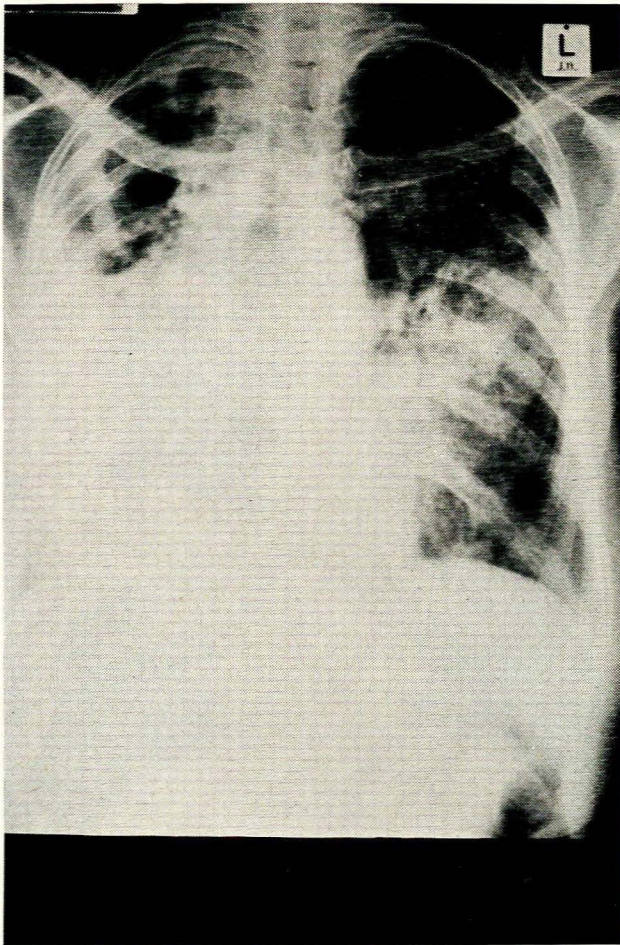


Fig. 1. Case 1, an adult female with gross bilateral cavitory pulmonary tuberculosis.

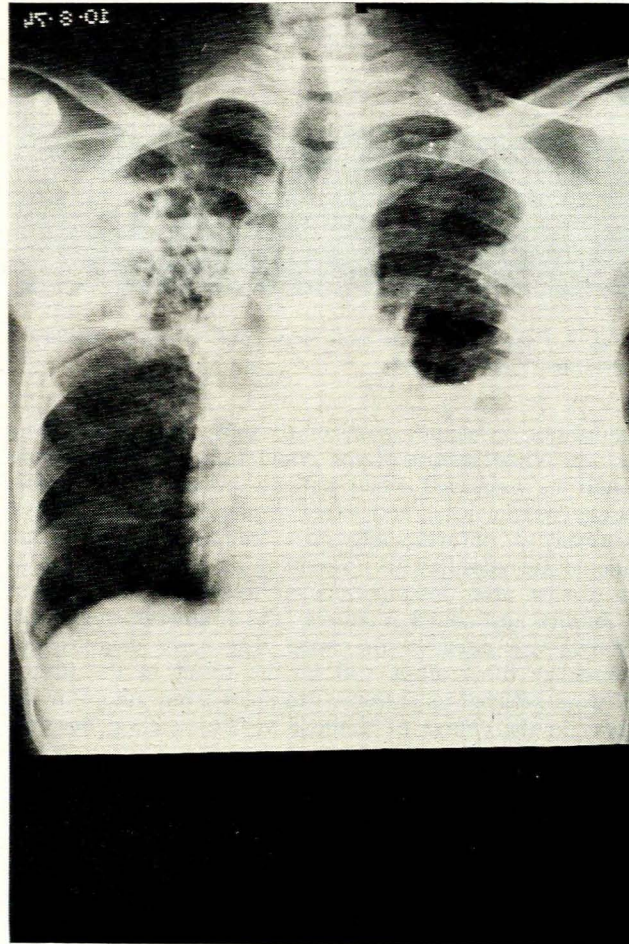


Fig. 2. Case 2, an adult male with extensive bilateral cavitory pulmonary tuberculosis.

Department of Health, Pretoria
T. F. B. COLLINS, M.B. B.CH., D.P.H.

Date received: 2 October 1974.

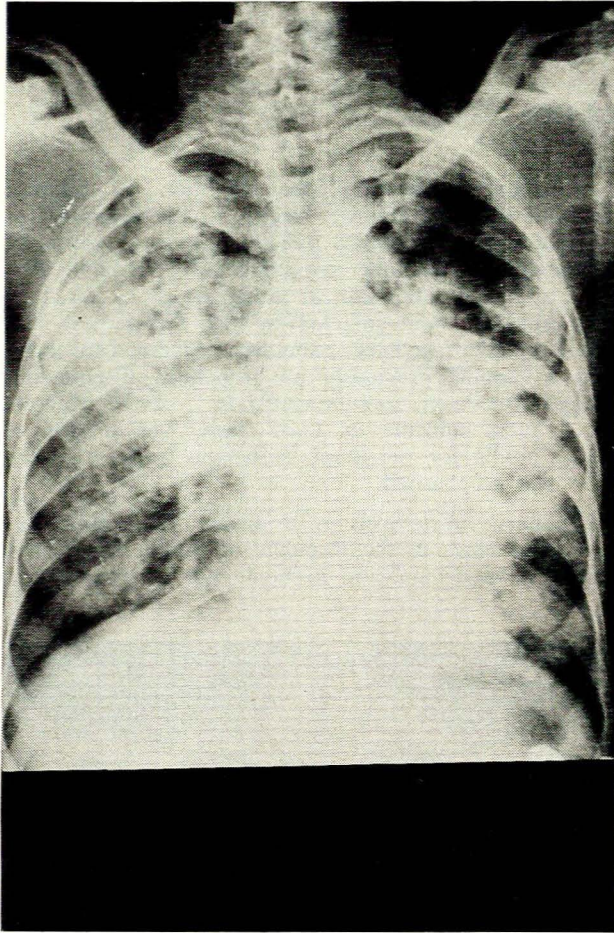


Fig. 3. Case 3, an adult male with gross bilateral cavitary pulmonary tuberculosis.

remind our colleagues, particularly those practising among the non-White sectors of the population, that tuberculosis should be suspected when patients present with chronic cough, weight loss, and other evidence of the disease. However, it unfortunately does frequently happen that patients are admitted to hospital in an advanced stage of the disease after long periods of treatment with various antibiotics and cough mixtures. The following tragic case histories are cited in the hope that early diagnosis of pulmonary tuberculosis will be the result in the future. All were selected as extreme examples from among many others in the course of a single visit to a chest hospital.

CASE REPORTS

Case 1

An adult female was admitted to hospital in an emaciated condition with gross bilateral cavitary pulmonary tuberculosis (Fig. 1). For 3 months before admission she had been treated on numerous occasions by a

general practitioner with injections and various mixtures, and had also received short courses of tablets. Her prognosis is poor, for although modern specific chemotherapy can be expected to arrest and heal the tuberculous disease, she will be left with a destroyed, fibrotic right lung, which is likely to be the site of recurrent or chronic sepsis.

Case 2

An adult male had been ill for 2 years with chronic cough, pain in the chest, and weight loss. During that time he had been treated on numerous occasions for influenza, bronchitis and pneumonia, but had never been referred for a chest X-ray examination. The cost of his treatment had exhausted his savings, and finally he attended the outpatient department of a general hospital, where extensive bilateral cavitary pulmonary tuberculosis with right-sided effusion was diagnosed (Fig. 2). He was transferred to a chest hospital and died the following day.

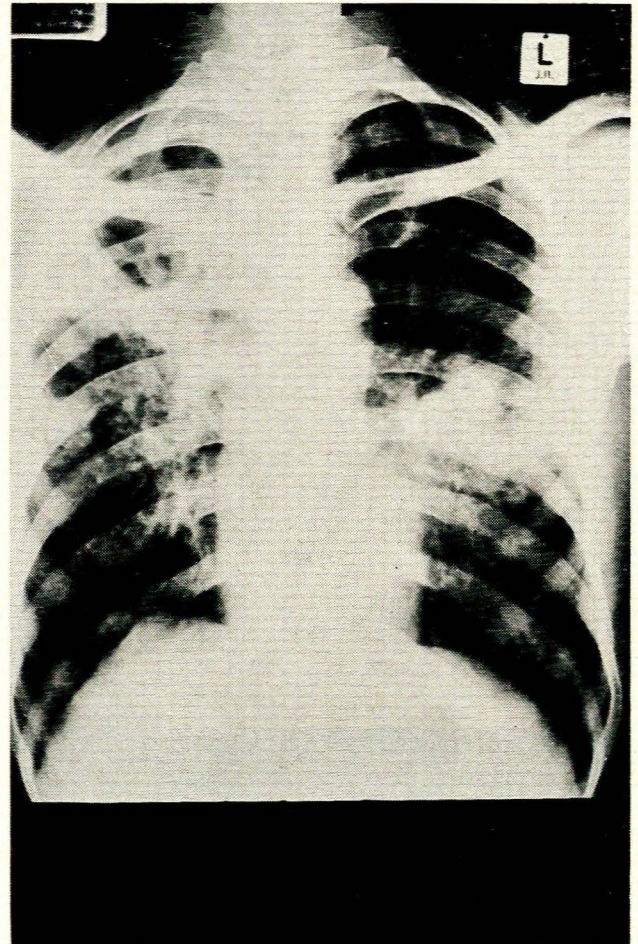


Fig. 4. Case 4, an adult male with a large thick-walled cavity in the right upper lobe and bilateral tuberculous infiltration.

Case 3

An adult male was treated for 'a long time' by general practitioners for persistent chest symptoms, and was ultimately admitted to hospital after a haemoptysis, with gross bilateral cavitary pulmonary tuberculosis (Fig. 3). He died 5 weeks later, after a second massive haemoptysis.

Case 4

This patient, an adult male, was relatively fortunate, for after 4 months of treatment for non-specific chest infection, he was referred for a chest X-ray examination. By this time, however, he had a large thick-walled cavity in the right upper lobe and bilateral tuberculous infiltration (Fig. 4). Much of the lung destruction might have been avoided had he been sent for examination sooner.

Case 5

An adult female was admitted to a chest hospital in poor condition, weighing only 22,5 kg, with a moderately advanced pulmonary tuberculous lesion and a painful swelling of the jaw, which made feeding extremely difficult. Her employer, a farmer, stated that she had been ill for 3 years, and he had personally taken her to a general practitioner on numerous occasions. She had paid R2,50 per visit, and had ultimately sold some of her

furniture to meet her continuing medical expenses. When she could no longer afford private medical attention, she went to a provincial hospital, where a chest X-ray examination was done for the first time. She was admitted to a small chest hospital and subsequently transferred to a larger institution for investigation and management of the jaw condition, but died soon afterwards. The cause of death was not determined.

DISCUSSION

It must be emphasised that the patients described here are not exceptional cases, as any medical officer at a chest clinic or hospital will testify. An earnest plea is therefore made that any patient presenting with symptoms suggestive of pulmonary tuberculosis be referred without delay for a chest X-ray examination. Such examinations are performed free of charge at local authority clinics, chest hospitals and by arrangement at most general hospitals. If there is uncertainty concerning the nearest available service, the local authority health department, district surgeon, or regional director of State Health Services should be consulted. Any difficulties which cannot be otherwise resolved should be referred to the Secretary for Health, Private Bag X88, Pretoria, 0001.

REFERENCE

1. Corner, B. D. and Anderson, J. D. (1974): *Tubercle*, **55**, 99.