

# The Electro-encephalogram and Suicide in a 12-year-old Boy

B. D. MURDOCH

## SUMMARY

Two electro-encephalograms were coincidentally recorded from a boy who hanged himself at the age of 12 years. The response to hyperventilation was mildly abnormal during the second recording, showing bilateral frontal sharp waves, focal on the right, and suggesting a defect in maturation.

This result is discussed in relation to studies implicating the frontal cortical areas in affective and social behaviour.

*S. Afr. Med. J.*, 48, 2403 (1974).

National Institute for Personnel Research, CSIR, Johannesburg  
B. D. MURDOCH

Date received: 14 August 1974.

Suicide in children younger than 16 years of age is rare.<sup>1</sup> A coincidence resulted in the availability of two electro-encephalograms (EEGs) which were recorded for research purposes from a child aged 10 years who later committed suicide. The findings are reported here because no such evidence has been found in the literature concerning brain function in cases of suicide.

## CASE REPORT

A boy aged 10 years 2 months was selected as a member of a normal control group for a research project. His clinical history was negative except for a minor head injury two years earlier. This was an occipital scalp wound requiring stitches, but not associated with unconsciousness. He had a full-scale IQ of 122 as measured by the Junior

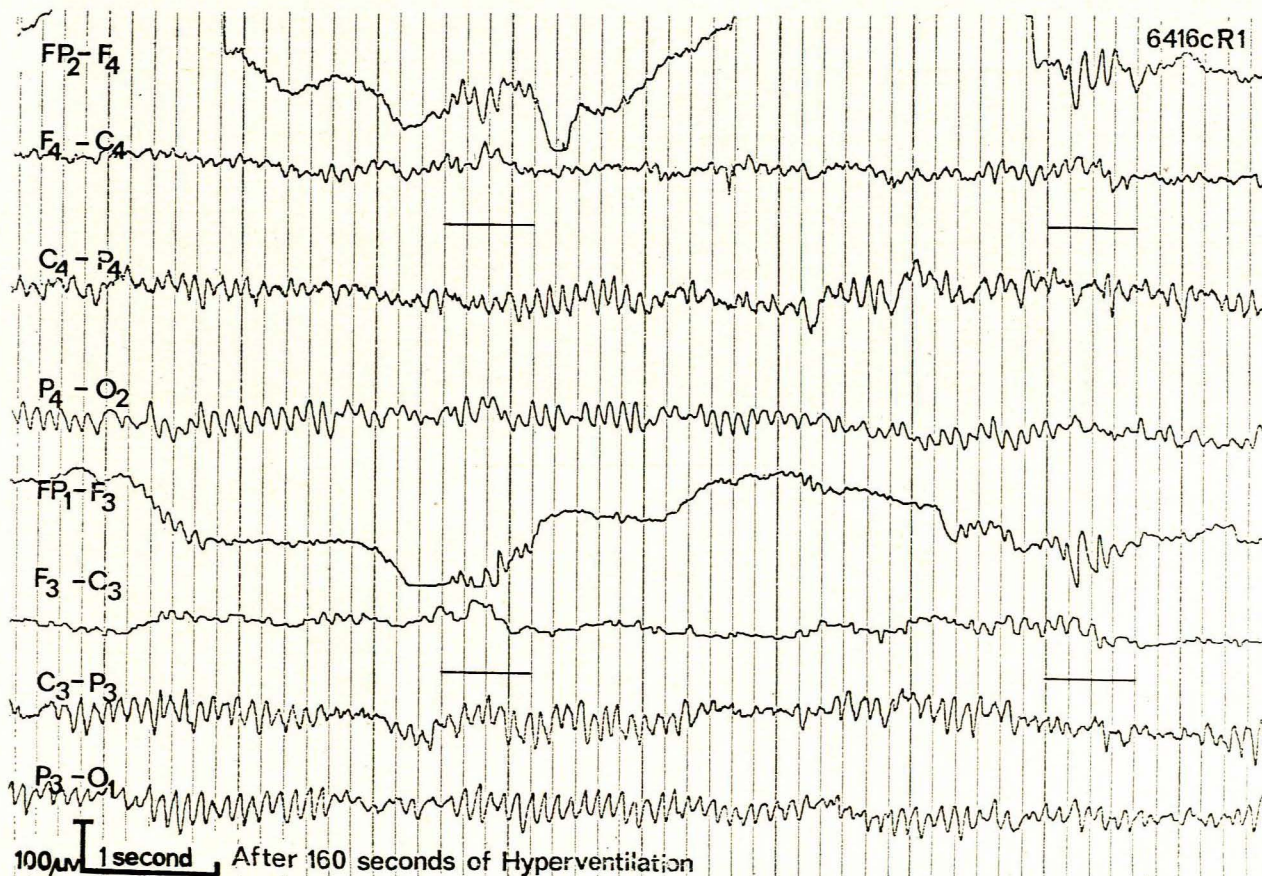


Figure 1

Recording channel identification according to International 10-20 system<sup>2</sup>.

Fig. 1. Bilateral frontal sharp waves (underlined) in the second EEG of the subject after 160 seconds of hyperventilation.



version of the SA Group Test. An EEG was recorded at this time and again 7 months later.

At the age of 12 years 1 month he was sent home from school for a classroom misdemeanour and punished by being forbidden to take part in a sport of which he was very fond. Later on the same day he was found dead, having hanged himself.

The two EEGs were recorded on a portable Galileo E8b electro-encephalograph, using 5 electrode-montages according to the 10-20 system.<sup>2</sup> Routine photic stimulation and hyperventilation procedures were performed on both occasions.

## RESULTS

On both occasions, visual inspection of the resting EEG revealed a well-defined alpha rhythm of between 10 and 11 Hz in the posterior areas, with occasional slow wave activity in the central and occipital regions. The EEG was considered to show no abnormal signs for the subject's age.

The EEG displayed no change in response to photic stimulation on either occasion or to hyperventilation during the first recording. However, on the second occasion, a high voltage sharp wave burst, appearing bilaterally in the frontal areas but focally on the right, was seen during hyperventilation (Fig. 1). This response was considered mildly abnormal.

## DISCUSSION

The EEG dysfunction evoked by hyperventilation during the second recording session raises the possibility of a cerebral instability of the right frontal area, possibly related, in the absence of specific clinical indications, to a cortical maturation defect. The appearance of sharp wave activity bilaterally further suggests the involvement of

centrencephalic structures. Kiloh *et al.*<sup>3</sup> consider that although use of the term 'defect in maturation' carries with it the implication of the operation of genetic determinants, it may be the expression of birth injury or subsequent cerebral trauma, of cerebral disease, or may be associated with epilepsy. Cortical immaturity or maturation defects have been seen particularly in association with disturbances of behaviour in both children and adults.<sup>4</sup>

However, the present dysfunction would appear to be atypical in this regard, in that the temporal regions are usually involved in maturation defects associated with behaviour disorders,<sup>3</sup> and not the frontal area as in this instance.

The relationship between frontal lobe damage (which is, of course, not necessarily implied by electro-encephalographic evidence of dysfunction) and behavioural and emotional disturbances have been well documented in both humans and animals. While it would therefore seem unnecessary to consider such studies in detail, it is perhaps relevant to the present case that Lishman<sup>5</sup> found that right frontal damage was associated with affective disorders such as depression, anxiety and irritability, while Franzen and Myers<sup>6</sup> found that bilateral ablations of the prefrontal or anterior temporal cortex in rhesus monkeys produced a marked reduction in social behaviour.

Finally, a point worthy of comment is the appearance of dysfunction only in response to hyperventilation during the second EEG, after recordings which were normal during rest and hyperventilation on the first occasion. This raises the possibility of a progressive dysfunction. Resolution of this question would only have been aided by further recordings.

## REFERENCES

1. Jasper, H. H. (1958): *Electroenceph. Clin. Neurophysiol.*, **10**, 371.
2. Durkheim, E. (1952): *Suicide: A Study in Sociology*. London: Routledge & Kegan Paul.
3. Kiloh, L. G., McComas, A. J. and Osselton, J. W. (1972): *Clinical Electroencephalography*. London: Butterworths.
4. Ellingson, R. J. (1954 - 5): *Amer. J. Psychiat.*, **111**, 263.
5. Lishman, W. A. (1968): *Brit. J. Psychiat.*, **114**, 373.
6. Franzen, E. A. and Myers, R. E. (1973): *Neuropsychologia*, **11**, 141.