

The Significance of Prelabour Type II Deceleration of Fetal Heart Rate in Relation to Braxton-Hicks Contractions

REPORT ON FOUR PATIENTS

P. F. FAIRBROTHER, H. A. VAN COEVERDEN DE GROOT, E. J. COETZEE,
J. P. SHARDLOW

SUMMARY

During prelabour cardiotocography on 450 high risk antenatal patients, painless uterine contractions (Braxton-Hicks) were recorded in 4 patients, who also showed a type II deceleration pattern. Two fetuses died and 2 were saved. In the 2 who died there was a delay of more than 12 hours between first observation and delivery, while in the 2 who were saved, immediate Caesarean section was performed. It is suggested that the sign of late deceleration in relation to Braxton-Hicks contractions is a preterminal manifestation of acute-on-chronic fetal distress, and the appropriate management should be immediate Caesarean section, whatever the gestation.

Antenatal cardiotocography might therefore have a place in the assessment of the 'very small for gestational age' fetus and an irritable uterus. This approach could ensure survival but not necessarily quality.

S. Afr. Med. J., 48, 2391 (1974).

It is entirely right that the emphasis in obstetrics has moved from detecting hypoxia in labour after it has occurred and possibly damaged the fetus, to predicting the likelihood that it will occur during labour.

During an extensive programme of prelabour testing by cardiotocography, 4 patients emerged with unexpected and dramatic results. It is not the purpose of this article to assess the value of this as yet uncompleted programme, but simply to report on these 4 patients.

PATIENTS AND METHODS

Patients whose fetuses were, by established criteria, thought to be at high risk of dying *in utero*, of developing acute

Department of Obstetrics and Gynaecology, University of Cape Town

P. F. FAIRBROTHER, B.A., B.M. B.Ch., M.R.C.O.G., Consultant and Senior Lecturer

H. A. VAN COEVERDEN DE GROOT, M.B. Ch.B., M.R.C.O.G., Senior Consultant and Senior Lecturer

E. J. COETZEE, M.B. Ch.B., M.R.C.O.G., Consultant and Lecturer

J. P. SHARDLOW, M.B. B.S., M.R.C.O.G., Research Fellow

Date received: 16 July 1974.

fetal distress in labour or of being small for gestational age, were selected for antenatal external cardiotocography.

The external cardiotocograph was applied and the instantaneous fetal heart rate recorded together with simultaneous anterior abdominal wall displacement which, in time course, if not in exact amplitude, reflected uterine contractions.

RESULTS

Out of 450 patients, 4 showed the cardiotocographic features illustrated in Fig. 1.

Patient 1

A 24-year-old primigravid patient had an apparently uncomplicated pregnancy until 30 weeks + 5 days,

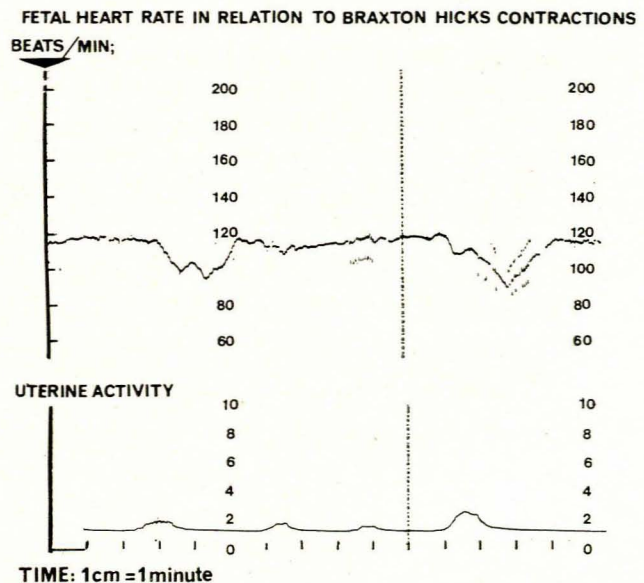


Fig. 1. Symptomless uterine contractions were recorded on the lower tracing by an external tocograph. The simultaneous fetal heart rate was recorded on the upper tracing. The figure shows late prolonged decelerations of heart rate in relation to contractions.

when she showed signs of pre-eclampsia, with a blood pressure of 150/100 mmHg and proteinuria. The fetus was thought to be growth-retarded even at this stage.

After 13 days of rest in hospital the above tracing was obtained. During this time, increasing hypertension was controlled with bethanidine, clonidine and hydralazine. Proteinuria increased to 7,22 g/24 hours and total 24-hour oestrogen excretion fell from 9,2 mg to 4,8 mg, with a concurrent reduction in creatinine clearance from 70 to 45 ml/minute.

The next day fetal movement ceased and no fetal heart was heard. The patient went into spontaneous labour the day afterwards and delivered a dead male fetus weighing 1250 g at 33 weeks. The liquor was heavily meconium-stained. This baby weighed 120 g below the 10th percentile for its age.¹ Subsequent maternal investigations failed to reveal any abnormality.

Patient 2

A 23-year-old primigravida had an uncomplicated pregnancy to 30 weeks, when proteinuria without hypertension was noted. The fetus appeared to grow slowly after this time, while proteinuria persisted in the range 2-3 g/day, and the creatinine clearance was maintained in the range 60-90 ml/minute.

At 34 weeks the uterus was irritable, the liquor volume diminished, and a tracing very similar to Fig. 1 was obtained. This pattern was repeated when a tracing was taken the following day, and although an immediate Caesarean section was performed, the baby was dead. The liquor, incidentally, was clear. The baby weighed 1200 g at 34 weeks. The mother, on subsequent investigation, was found to have chronic renal disease.

Patient 3

A para 4 (weight of previous babies 2,8-3,6 kg), had a normal pregnancy up to 28 weeks, when intra-uterine growth retardation was suspected. The biparietal diameter was measured just over one week later at 76,9 mm. She was admitted to hospital because of a slight antepartum haemorrhage at 31 weeks. A second biparietal diameter was 74,3 mm at 31 weeks and 6 days. At 32 weeks a fetal heart pattern similar to that in Fig. 1 was recorded.

The patient had an immediate Caesarean section and a 940-g female baby was delivered. The liquor was meconium-stained. The baby was assessed at 32,2 weeks,² and did extremely well, showing no evidence of respiratory distress. No cause for its small size (300 g below the 10th percentile), other than intra-uterine malnutrition, was found.

Patient 4

A 20-year-old primigravida was admitted to hospital at 30 weeks' gestation for investigation because of clinical suspicion of intra-uterine growth retardation. The uterus was palpable at the umbilicus, and it appeared to be

irritable and devoid of liquor. This situation remained unchanged for two weeks when the total oestrogen levels were in the range 7,8-8,7 mg/24 hours, and an amniocentesis demonstrated low surfactant activity. At 34 weeks, however, antenatal monitoring showed a tracing as seen in Fig. 1 and an immediate Caesarean section was performed. The liquor, at section, was clear and gave a maximum score on the Cape Town Surfactant Bubbles Index.³

The baby was assessed at 34 weeks on the Dubowitz scale, which corresponded with dates. Its size of 1250 g was 260 g below the 10th percentile and again no cause other than malnutrition was found for its small size. The baby grew well postnatally and suffered no complication.

DISCUSSION

The 4 pregnancies had several features in common: all the fetuses were severely malnourished *in utero*, the uterus in each was small-for-dates, irritable and contained a reduced amount of liquor amnii; furthermore, painless, mild contractions produced a type II fetal heart deceleration pattern. This type of fetal heart rate change is well accepted as being cardiogenic, being associated with lack of cardiac energy supplies.

In a well-nourished fetus, in labour, it represents a late stage of hypoxia because it indicates cardiac glycogen depletion as a result of anaerobic metabolism. In a malnourished fetus, on the other hand, the cardiac glycogen concentration is so low initially that type II decelerations can be expected after only mild hypoxia, in which case they indicate a state of late malnutrition but early hypoxia. Naturally all stages between the two must exist. While the case can in no sense be regarded as proved, on *a priori* grounds this type of heart pattern is preterminal and the *a posteriori* observation that 2 of the 4 fetuses died when delivery was delayed for 12 hours helps to confirm this.

We would suggest, without holding any brief for antenatal cardiotocography, that should a type II deceleration pattern be discovered in a fetus suspected of being malnourished, then the fetus should be delivered forthwith by the most expeditious method, probably Caesarean section, at whatever gestation.

In our experience, malnourished babies are immune to hyaline membrane disease, as was perhaps reflected by the high surfactant score in patient 4. It might, furthermore, be good clinical practice to monitor patients with the cardiotocograph if they have an irritable uterus together with suspected intra-uterine malnutrition. We would not, however, be content to manage suspected intra-uterine malnutrition solely in this way because, while it might ensure survival, the same cannot be said of quality. It has been amply demonstrated in animals that malnutrition without the additional insult of hypoxia at the time of a brain cell growth spurt produces permanent damage.⁴ The human brain has a growth spurt which begins at 30 weeks and only reaches a maximum at 3 months of postnatal life.⁵ It has, furthermore, been demonstrated that intra-uterine malnutrition permanently reduces head circumference.⁶ We feel that intra-uterine

malnutrition has already damaged the fetal brain long before the combined effect of malnutrition and hypoxia produces preterminal cardiogenic type II decelerations.

For us, therefore, antenatal cardiotocography as described remains a very late safety precaution, to be used to best advantage in the circumstances described, while most attention should be directed towards the investigation of intra-uterine malnutrition in its earlier stages.

We wish to thank Professor D. A. Davey and Sister B. Martin, Research Midwife, who performed most of the cardiotocographic measurements.

REFERENCES

1. Lubchenko, L. O., Searls, D. T. and Brazie, J. V. (1972): *J. Paediat.*, **81**, 814.
 2. Dubowitz, L. M. S., Dubowitz, V. and Goldberg, C. (1970): *Paediatrics*, **77**, 1.
 3. Edwards, J. and Baillie, P. (1973): *S. Afr. Med. J.*, **47**, 2070.
 4. Winick, M. and Noble, A. (1965): *Developmental Biology*, vol. 12, p. 451. New York: Academic Press.
 5. Dobbing, J. (1970): *Amer. J. Dis. Child.*, **120**, 411.
 6. Davies, P. and Davis, J. P. (1970): *Lancet*, **2**, 1216.
-