

HYDROCALYCOSIS AND CALYCEAL DIVERTICULUM

LEON MORRIS, M.B., D.M.R.D.

Johannesburg

Hydrocalycosis and calyceal diverticulum are related but not identical conditions. They both represent dilatations of the renal collecting system, but differ in their pathological and radiological features. Their etiology has not been conclusively established, nor their specific relationship to the formation of renal calculi. Their importance lies in diagnosis, particularly radiologically, for on this will depend the management of the cases and the avoidance of unnecessary surgical procedures.

Historical

Hydrocalycosis and calyceal diverticulum have long been recognized. Prather (1941) in an historical survey stated that a similar condition was described in 1841, albeit under a different name. Since that time the terminology has differed from author to author but the lesions described show essentially similar features. Watkins (1939) and Winsbury-White (1939) were the first to use the term hydrocalycosis, and Prather's description is the first reference to calyceal diverticulum.

Pathology

According to Newman, Lowman and Waters (1952), Moore (1950), Mathieson (1953), Ferguson and Ward-McQuaid (1955), and Prather, the essential features of hydrocalycosis and calyceal diverticulum are that they are dilatations of the renal collecting system lined by transitional epithelium, although Holm (1948) states that the lining membrane may be altered by infection or calculus formation.

Dorsey (1949) and Prather differentiate macroscopically between calyceal diverticulum and hydrocalycosis. The former consists of a dilatation distal to a minor calyx communicating with the minor calyx by a fine channel (Fig. 1B),

the latter is a dilatation of the calyx itself (Fig. 1C). Moore further subdivides hydrocalycosis on the basis of the anatomical site (Fig. 1C and D). This author does not recognize calyceal diverticulum as described by Dorsey (Fig. 1B), and considers hydrocalycosis and calyceal diverticulum (i.e. dilatation of the minor calyx, Fig. 1D), to be synonymous. In addition Dorsey differentiates pathologically between these two conditions and other localized cystic dilatations, such as congenital solitary cysts and cysts following obliterative pyelonephritis.

Etiology

The etiology of both these conditions has not been determined. Two main theories of their causation are postulated:

(a) *Achalasia.* Moore, Prather, and Watkins consider them to be due to achalasia or spasm of the musculature in the region of the calyceal neck. The anatomy of these muscles has been described by Henle (1866) and the hydro-mechanics of the renal calyces has been discussed by Narath (1940). On the basis of these descriptions it would appear that the situation of the lesions will depend on the anatomical site of the muscles affected. For example, achalasia of the muscles of the calyceal neck will produce hydrocalycosis, while affection of the muscles of the renal pyramids will produce a calyceal diverticulum.

(b) *Mechanical Obstruction.* Ferguson, Ward-McQuaid and Dorsey postulate that this is due to fibrosis, which may be secondary to infection or calculus formation, and Hyams and Kenyon (1941) consider that a localized obliterative pyelonephritis may produce it. In dilatation associated with calculus formation, MacAlpine (1949) states that an

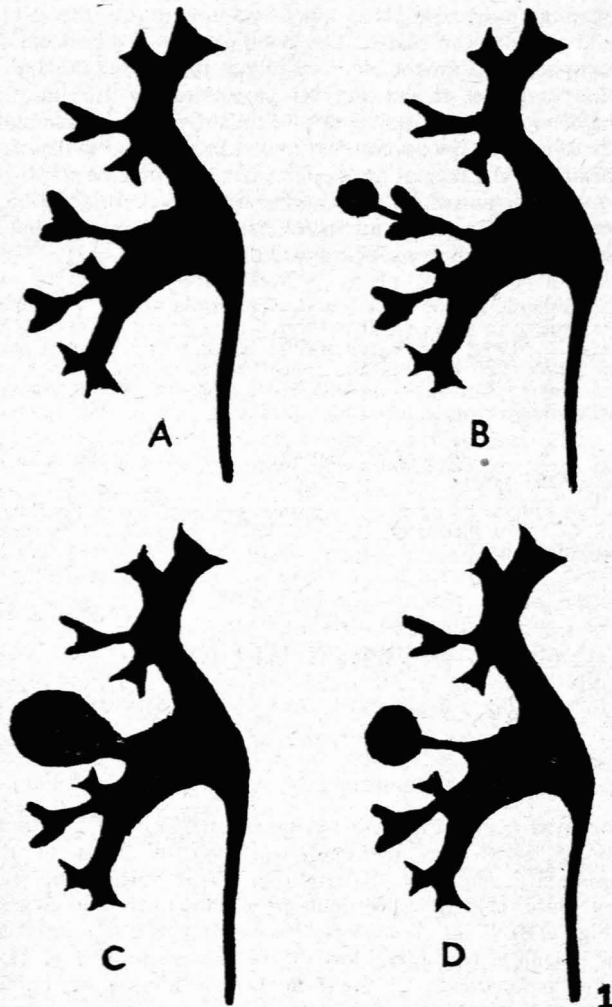


Fig. 1. (A) Normal. (B) Calyceal diverticulum. (C) Hydrocalycosis (forniceal type). (D) Hydrocalycosis (minor calyceal type).

obstructive element is not essential and that the cavity appears to arise as a dilatation around a stone or stones lying in the renal parenchyma.

In addition, the true relationship of the lesions to calculus formation is obscure, and it may not be possible to decide whether the calculus is the primary cause of the obstruction or is secondary to stasis in the dilated 'cyst'. According to Ferguson and Ward-McQuaid, if the stone is solitary the former is more likely, whereas multiple stones are usually the result of stasis.

It may be noted that Weyrauch and Fleming (1950) have described a case of hydrocalycosis which they consider to be of congenital origin.

Clinical Findings

The clinical findings are variable and no characteristic syndrome can be described. The most frequent symptoms are the following:

(a) Aching pain in the kidney region. Of the cases recorded in the literature this would appear to be the commonest symptom.

(b) Haematuria, with or without clot colic.

(c) Symptoms associated with infection and pyuria.

(d) Symptoms of calculus colic.

The conditions may be entirely asymptomatic.

CASE REPORTS

1. *Minor Calyx Hydrocalycosis.* A male aged 55 years, with a history of several attacks of left renal colic for 6 years, during the last 4 of which repeated X-ray examinations showed a dense calculus at the lower end of the left ureter without evidence of back pressure or dilatation of the calyceal system. Six weeks before the last pyelographic examination he passed a calculus

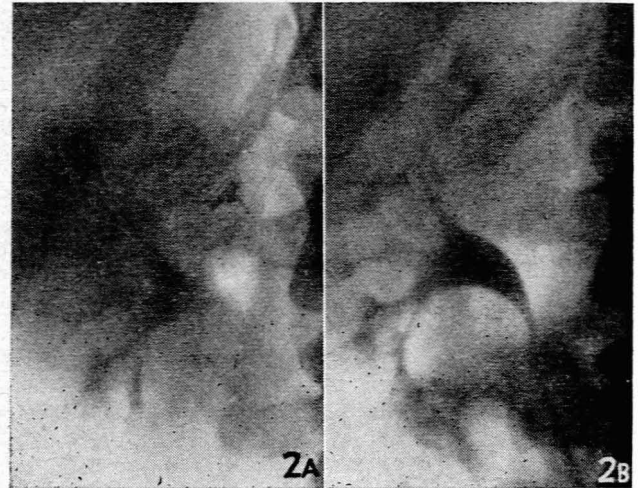


Fig. 2 (a). Case 1. IVP demonstrating minor calyceal hydrocalycosis in the upper pole of the right kidney. Retouched. Fig. 2 (b). Case 1. IVP 4 years later. No appreciable change in the appearances.

painlessly and the films revealed that the stone was no longer visible. All films taken throughout the 4-year period showed a smooth, localized cavity containing contrast medium in the upper pole of the right kidney. This showed no change in size over 4 years. One of the upper minor calyces was not seen and the cavity containing contrast medium represented a dilated calyx (Figs. 2a and 2b).

2. *Calyceal Diverticulum.* A male aged 43 presented with a history of colicky pain in the left loin 5 days previously. This had lasted one day and was relieved by an injection. The urine was cloudy during the attack but there was no frank haematuria or dysuria. On the day before he was seen he felt a slight pain in the right loin similar to a pain experienced there 6 years previously. On that occasion the attack ended with the passage of a urinary calculus. Intravenous pyelography (Fig. 3) revealed a small cavity containing contrast medium distal to the calyces in the upper pole of the right kidney. A small channel could be seen communicating with one of the minor calyces. The calyces themselves showed no abnormality.

3. *Calyceal Diverticulum.* A female aged 44, first seen giving a history of an attack of severe pain in the left loin 2 months before. The attack lasted a few days and was relieved by aspirin. It coincided with an attenuated menstrual period. There was no dysuria and the urine was clear. Intravenous pyelography at that time was said to have shown a non-functioning left kidney and retrograde ureteric catheterization was performed. A repeat of the intravenous pyelogram 5 days later was said to have shown a normally functioning left kidney. Since that time the patient had been asymptomatic. Intravenous pyelography revealed a small cavity containing contrast medium distal to the calyceal system in the upper pole of the left kidney and communicating with a minor calyx by a fine channel. There was no other abnormality.

4. *Hydrocalycosis (forniceal type).* A middle-aged male suffered

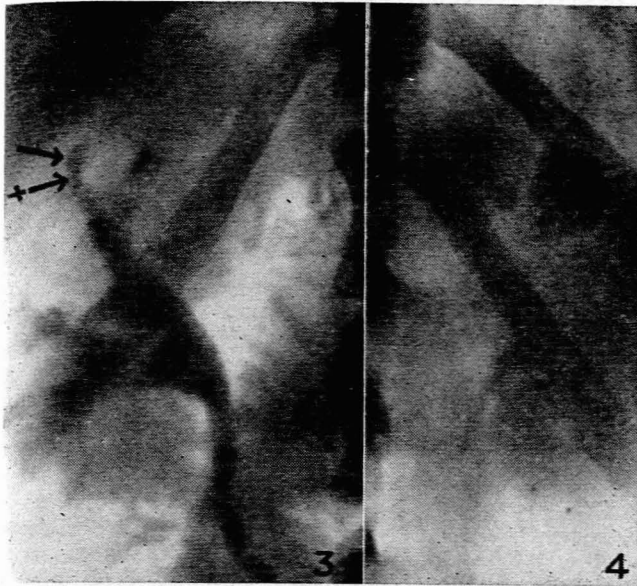


Fig. 3. Case 2. IVP. A small calyceal diverticulum(→) is shown, distal to a relatively normal minor calyx, with which it is connected by a fine channel (+ →).

Fig. 4. Case 4. Tomographic section of the left kidney during IVP, demonstrating a large hydrocalycosis of the fornical type.

from recurrent urinary infections, which usually responded rapidly to antibiotics. There was no haematuria and no history of urinary calculus. Intravenous pyelography (Fig. 4) showed a large cavity containing contrast medium in the upper pole of the left kidney. This represented a minor calyx greatly dilated, distal to its junction with the major calyx. The patient was followed up over a number of years without alteration in the radiographic appearances and without clinical deterioration. Of late the attacks of infection have become less frequent.

DISCUSSION

The essential radiological feature in hydrocalycosis and calyceal diverticulum is a smooth, regular, round or oval cavity in the renal parenchyma which fills with contrast medium on intravenous or retrograde pyelography. The contrast medium tends to remain in the cavity for some time after it has drained from the rest of the collecting system. In calyceal diverticulum the cavity is distal to the minor calyx and communicates with it by a fine channel, whereas in hydrocalycosis the cavity represents a dilated calyx. This conforms with Dorsey's pathological description rather than with Moore's and is borne out by the appearances in the cases described. Features shown in cases 2 and 3 are not described by Moore (Fig. 3). The lesion is localized and the remainder of the collecting system of the kidney shows no abnormality; the kidney functions normally on intravenous contrast injection and the unaffected calyces show no distortion. In calyceal diverticulum the cavity tends to be rather small (cases 2 and 3) but in hydrocalycosis it may reach a considerable size (case 4). The lesions are not rapidly progressive and may be followed up for long periods, years in some cases, without apparent change.

None of the cases presented showed calculi directly related to the cavities in the renal parenchyma. However, cases 1 and 2 were associated with a history of calculus, although

in case 1 the calculus was on the side opposite to the lesion and in case 2 the passage of the calculus predated the discovery of the lesion by 6 years. In case 3 no calculus was demonstrated but the history of calculus is strongly suggested. It would appear likely, therefore, that some definite relationship exists between hydrocalycosis, calyceal diverticulum and renal calculi.

As long as the existence of these conditions is recognized and their possibility borne in mind, their radiological features are usually sufficiently characteristic to permit of an accurate diagnosis. However, as has been noted, their clinical features are variable and uncharacteristic, a finding borne out by the fact that only one case in the present series showed the symptom most commonly recorded in the literature (i.e. aching pain in the loin). For this reason the main responsibility in their diagnosis will rest with the radiological findings.

The differential diagnosis, therefore, particularly from a radiological standpoint, would appear to be important:

(a) *Tuberculous Lesions.* Tuberculous cortical abscesses in the earliest stages may present a picture similar to that of hydrocalycosis. However, untreated tuberculous lesions increase progressively in size and the degree of cortical involvement is considerably greater within a short period of time than in hydrocalycosis. In the later stages calcification may develop within the cortex. In addition, bacteriological studies of the urine may reveal the nature of the condition.

(b) *Cystic Lesions* include solitary congenital cysts and parapelvic cysts. Generally neither of these communicate with the renal collecting system and will not fill with contrast medium either on retrograde or intravenous pyelography. However, should a cyst rupture into a calyx or into the renal pelvis it may be indistinguishable radiologically from hydrocalycosis and the final diagnosis would depend on histological examination of the lining membrane. The cysts are lined by cuboidal epithelium in contradistinction to the transitional epithelium of the uninfected hydrocalycosis. Further, the cysts tend to produce considerably more distortion of the calyceal system.

(c) *Cystic areas* secondary to obstruction produced by an *obliterating pyelonephritis* will usually not fill with contrast medium, because they are cut off from the renal collecting system by the fibrous reaction. Should they fill they may be differentiated by a well-marked irregularity of outline, and a deformity of the associated minor calyces.

(d) *Tumours of the kidney parenchyma* produce calyceal distortion and, if large enough, deformity of the kidney outline itself. Even if they undergo cystic degeneration, it is uncommon for the cystic areas to fill with contrast medium on pyelographic examination.

(e) *Pyelo-Interstitial Reflux.* The contrast medium in the renal parenchyma has a rather hazy ill-defined margin in contradistinction to the clear-cut, well defined margin seen in hydrocalycosis or calyceal diverticulum. Also the contrast medium clears from the kidney substance relatively quickly.

(f) *Renal Papillary Necrosis.* The radiological picture may be similar to calyceal diverticulum but the patients are critically ill and the condition is commonly associated with diabetes mellitus or an obstructive uropathy, and always with pyelonephritis (Christoffersen and Anderson—1956).

Once the diagnosis has been made, in the absence of incapacitating symptoms, expectant treatment is the choice.

Recurrent infection may require intensive medical treatment for adequate control (case 4). However, if infection is persistent surgery becomes necessary, the majority of workers preferring conservative local resection rather than radical surgery.

Ferguson and Ward-McQuaid consider follow-up radiological examinations unnecessary where no complicating symptoms are present. Although cases 1 and 4 support this contention it is probably desirable to have one or perhaps two re-examinations at 3-monthly intervals to exclude the possibility of a tuberculous lesion with certainty.

SUMMARY

1. A brief historical review of dilatations of the renal collecting system is presented.
2. The pathological changes are discussed with special reference to the differentiation of hydrocalycosis and calyceal diverticulum. Theories of causation are presented.
3. The variability of the clinical features is stressed and the importance of radiological diagnosis is emphasized.
4. Four cases are presented, 2 of hydrocalycosis and 2 of calyceal diverticulum, with radiological illustrations.
5. The differential diagnosis of these conditions and their relationship to renal calculus is discussed.

6. Management is briefly outlined.

I wish to thank Dr. Eric Samuel for his helpful advice and encouragement in the preparation of this paper. I am indebted to Mr. R. Campbell-Begg and Mr. I. Maisels for permission to publish the reports of cases 1 and 2.

REFERENCES

- Christoffersen, J. C. and Anderson, K. (1956): *Acta radiol.*, **45**, 27.
 Dorsey, J. W. (1949): *J. Urol.*, **62**, 742.
 Ferguson, G. and Ward-McQuaid, J. N. (1955): *Brit. J. Surg.*, **42**, 595.
 Henle, J. (1866): *Handbuch der Systematischen Anatomie des Menschen*, (ii) 294.
 Braunschweig. (Quoted by Watkins, *loc. cit.*)
 Holm, H. (1948): *Acta radiol.*, **29**, 87.
 Hyams, J. A., and Kenyon, H. P. (1941): *J. Urol.*, **46**, 380.
 MacAlpine, J. B. (1949): *Cystography and Urography*, 3rd ed. Bristol: Wright.
 Mathieson, A. J. M. (1953): *Brit. J. Urol.*, **25**, 147.
 Moore, T. (1950): *Ibid.*, **22**, 304.
 Narath, P. A. (1940): *J. Urol.*, **43**, 145.
 Newman, H. R., Lowman, R. M., and Waters, L. L. (1952): *Surg. Gynec. Obstet.*, **90**, 77.
 Prather, G. C. (1941): *J. Urol.*, **45**, 55.
 Watkins, K. H. (1939): *Brit. J. Urol.*, **11**, 207.
 Weyrauch, A. M. and Fleming, A. (1950): *J. Urol.*, **63**, 582.
 Winsbury-White, H. P. (1939): *Brit. J. Urol.*, **11**, 245.