

MIDGET DERMATOME AND STRIP SKIN GRAFTING

DAVID S. DAVIES, *O.B.E.*, D.M. (OXON), F.R.C.S. (EDIN.)

and

DAVID DAVIES, F.R.C.S.

Department of Plastic Surgery, Groote Schuur Hospital, Cape Town

The proposal for yet another dermatome calls for a few words of justification.

The need for this dermatome originated in the wish to speed up the skin coverage of extensive burns, particularly in children. Nowadays, the surgeon is faced with burns of such extent as formerly would never have lived to need grafting, but, the patient having been brought through to this stage, skin covering should now be carried out quickly and completely. The aim must be complete coverage by the end of the 4th week. Delay in skin grafting is due chiefly to the difficulty of getting sufficient skin in these very sick patients, and the result is that grafting is only completed after the seeds of future contractures have been sown and the soil has become unkindly to grafts. Particularly is this so where the surgeon does not possess special guarded skin-graft knives or is inexperienced in freehand skin cutting. Even with guarded knives the difficulties of taking skin in large quantities tend to make the surgeon shirk the operation.

At one time we sought a solution in the use of homografts such as parental skin, but though helpful, this was far from

ideal, and we have always been working towards our ideal of complete coverage with overlapping strips of the patient's own skin.

Our object in cutting the skin into strips is not to economise skin but to ensure take. On infected granulating areas, strips survive more surely than larger areas of skin would. On freshly excised areas, no matter how careful the haemostasis, haematoma formation is frequent, and if such an area is covered by one large single graft, the graft may be lifted up into a tent by clot, with resulting failure to take. The danger is minimized where the skin is put on in strips. Strips allow blood and secretions to escape at the seams, leaving the grafts in place. It is very important to get granulating areas completely covered at the first grafting; a second grafting to cover areas left between grafts does not give nearly as good a result as the first. Many of the new patches fail to take, and the skin from near-by strips seems unable to grow uphill on to the rising granulation tissue.

This means that a lot of skin is needed if complete coverage is to be carried out at the first operation, and not too much

time should be spent at operation in taking it; some quick mechanical form of cutter is necessary.

We have watched great artists operating with many forms of hand cutting knives, guarded and unguarded, but have always thought, even while admiring them, that there surely must be some better and quicker way. With this in mind we experimented with all forms of dermatomes and concluded that the electrodermatome came nearest to the ideal.

There were, however, still certain objections. Firstly, the initial cost of the machine was high and, although the blades were called 'throw-away blades', when you consider that each one may cost 10s. 0d. to 12s. 6d. it becomes expensive, because we have never succeeded in satisfactorily using such a blade twice—or even once if it has been sterilized and put away without being used. Further, there is no means of restoring the edge by stropping. A second disadvantage of the usual dermatome blade, is its length which makes many areas inaccessible to operation with such a blade. In bad burns one rarely finds an area which will allow a graft to be taken the full available width of the blade. This is especially so in children, the convexity of whose limbs allows of grafts often only an inch wide.

In the face of these difficulties why attempt to take wide grafts? They should be cut into strips or stamps anyway, so that it would be time-saving to take them about an inch wide straight away. A dermatome with a cutting head this width at once opens up many new fields from which to take grafts; the pectoral regions, the abdomen, the strips over the erector spinae, the upper and lower arms and legs all become available, and the ideal of taking sufficient skin to cover the defect entirely, becomes practicable.

We have in fact found that with the narrow dermatome we can take skin from practically anywhere on the body and with very little practice it is possible to wander from abdomen or back, up over the ribs or across the abdomen at will. It is obvious what this means in a case of burns of say 40% of the body surface, where the legs, from which the grafts are usually taken, are burned and no longer available as donor areas.

Most of the urgent extensive grafts are for covering big burned areas with infected granulating surfaces, and for these

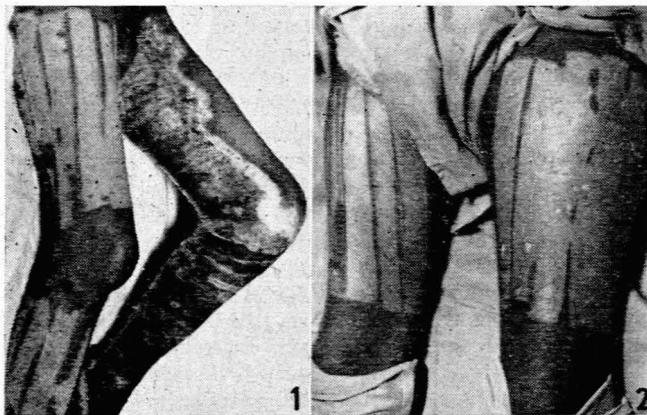

Fig. 1. Case A.B. Left leg showing area strip-grafted 7 days before, first dressing with grafts healed; donor area on right leg also healed.

Fig. 2. Case X.Y. Donor areas 2 weeks after grafting ready for second crop.

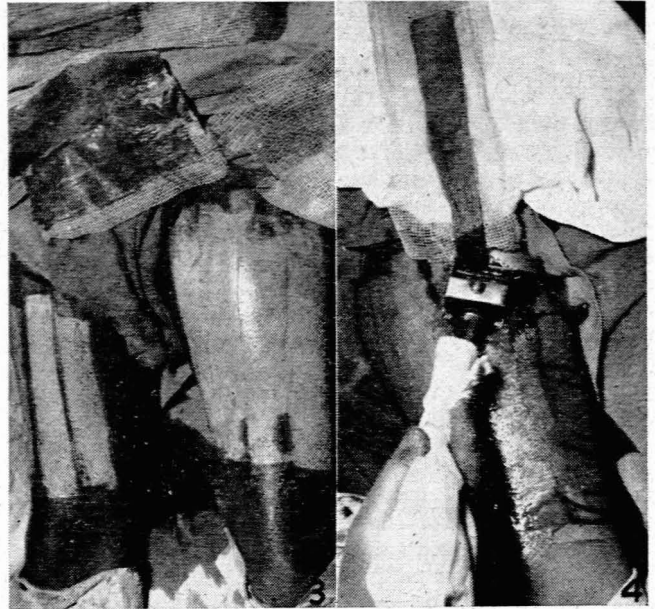


Fig. 3. Case X.Y. Second crop taken: strips shown on tulle gras.

Fig. 4. Case X.Y. Dermatome at end of cutting a strip.

areas skin strips are ideal. For almost all skin grafting we need enough skin for complete coverage, but in narrow strips of appropriate thickness, taken in such a way that the donor area heals so quickly that they may give new grafts if necessary within 3 weeks.

For these requirements the midget dermatome is ideal. It can do no damage, it can be adjusted for varying thickness, it is simple, speedy and economical. The blade we use is a

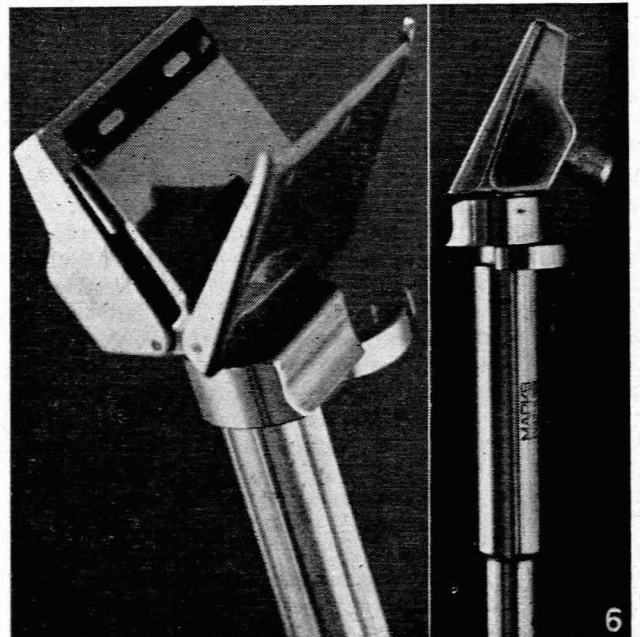


Fig. 5. Dermatome—open, showing razor blade in position.

Fig. 6. Dermatome—shut, ready for use.

commercial safety-razor blade of the injector type, costing a few pence each. One blade is sufficient for any but the very largest grafts. The simplicity of the machine is such that skin grafting can be done by every surgeon or general practitioner. With such a machine it is possible to cover completely very extensive burns in one operation, and to have the whole area healed by the end of the fourth or fifth week.

Burned cases, instead of being referred late to plastic units at the larger hospital could be dealt with by the general surgeons or general practitioners at their local hospitals, thus avoiding long hospitalization and the tragedy of old burn scars and contractures which will need further plastic treatment later.

The dermatome* illustrated (Figs. 4, 5 and 6) is built to fit like a dental hand piece on to the cable of a dental machine. The drive moves a small blade in a side-to-side cutting action. We have constructed the machine to take the 'Pal' injector-type safety-razor blade. The blade can be changed in seconds by turning back the safety lever, pulling back the collar, and

* Available from the Marks Engineering Works, 118 Buitengracht Street, Cape Town (patent applied for).

pressing up the base plate. These movements are reversed to hold the blade in place. The hood ends in a guard bar in front, which keeps the blade cutting at the desired thickness. The thickness of cut may be regulated by turning the milled nut to the appropriate setting. One blade costing a few pence will cut several feet of a skin strip and will suffice for all but the biggest grafts. The machine may be sterilized by boiling, autoclaving or immersion in T.C.F. solution,* but we have found boiling in A.C.10 solution† best, in that it ensures lubrication as well as sterilization.

We should like to offer our deepest thanks to Mr. Holmgren for helping us to prove that the idea was feasible, and to Mr. Cecil S. Marks, Mr. Kenneth Wheeler and Mr. H. R. Cooke for many brilliant ideas and much precise work. Thanks are also due to Mr. B. Todt, of Groote Schuur Hospital, for the illustrations.

* A 2% solution of each of thymol, cresol and formalin in methylated spirits.

† A proprietary preparation of mixed oil supplied by the Raven Oil Co., 170 Piccadilly, London, W 1, and supplied by most dental suppliers.