

CROUZON'S DISEASE: HEREDITARY CRANIO-FACIAL DYSOSTOSIS

A CASE REPORT

LOUIS MEYERSON, M.B., B.CH. (RAND), D.O., R.C.P. AND S. (ENG.)

Johannesburg

Crouzon¹ in 1912 first described a form of cranio-facial dysostosis to which he gave the name '*dysostose cranio-faciale hereditaire*' emphasizing the hereditary factor. Atkinson² reviewed the literature and found 86 cases between 1912 and 1937 in which he believed the characteristics of the disease were unmistakable. However, only 58 of these fulfilled one of Crouzon's original criteria, that of heredity.

strabismus is mentioned in all but 5 cases. The fundi show evidence of optic neuritis and choked disc is not uncommon. Blindness in one or both eyes is by no means rare. Nystagmus is mentioned in 6 cases.

Heredity. This was especially emphasized by Crouzon, but in 28 cases of Atkinson's series there is no mention of its presence or of the existence of the disease in any other member of the family.

CASE REPORT

A Bantu girl aged 15 years presented herself at St. John's Ophthalmic Hospital, Johannesburg, on 29 January 1957. Her eyes had started to protrude at about 3 years of age, she had occasional pain behind the eyes, and her vision had deteriorated during the past 5 years. She could dislocate her eyes but this performance caused her pain. Her general health was good except for deafness in the right ear.

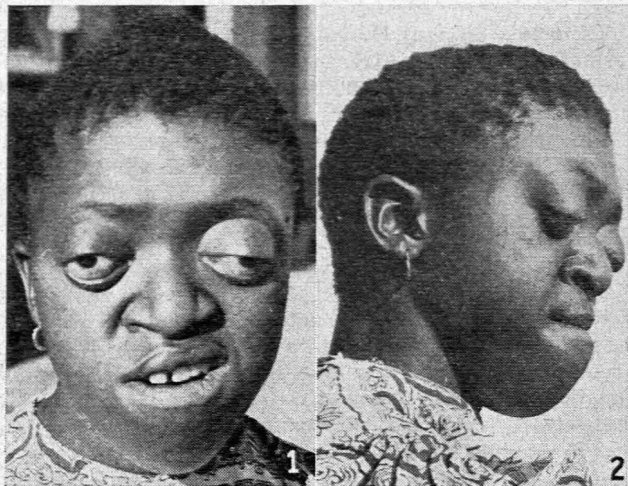


Fig. 1. Anterior view of patient showing tower skull, proptosis and divergence. There is no facial paralysis.

Fig. 2. Lateral view of patient showing proptosis, beaked nose, flattening over maxillary region, and marked prognathism.

The distinctive characteristics in the series reviewed by Atkinson are 4 in number, as follows:

Cranial deformities. These consist in a swelling of the frontal region, with an antero-posterior ridge overhanging the frontal prominence and often passing to the root of the nose. The transverse diameter of the head is large, causing it to be brachycephalic. There is early synostosis of the frontal sutures, and a basilar kyphosis.

Facial malformations. The upper jaw is aplasic, the mandible shows prognathism and the nose is like a parrot's beak. The facial angle is increased.

Eye changes. Exophthalmos is always present, and

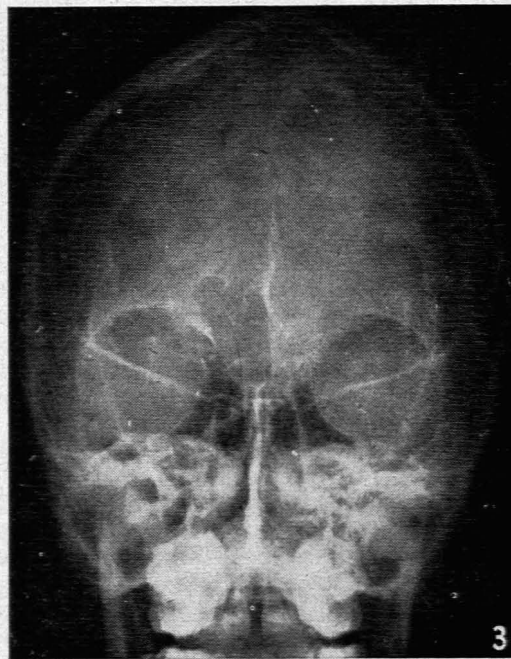


Fig. 3. Antero-posterior radiograph of skull. Sutures appear closed. Numerous convolucional markings.

She has 3 brothers and a sister who are normal. There are no other members of her family who have a similar deformity.

Examination

The patient was of normal stature for her age and apparently normal intelligence. There was marked bilateral proptosis with divergence of both eyes. The nose was beaked, with a flattening of the face over the maxillary region and a marked prognathism.

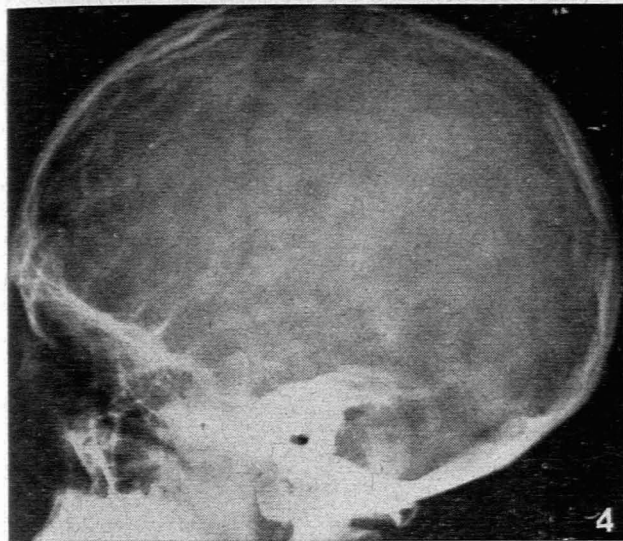


Fig. 4. Lateral radiograph of skull. Numerous convoluted markings. Floor of middle and anterior fossae shortened.

The palate was highly arched and the upper central incisors widely spaced.

The ocular movements were limited in all directions and convergence was absent. A pendular lateral nystagmus was present. The pupils were ectopic and the left gave a sluggish response to direct light. Fundal examination revealed that both optic discs were pale and the margins blurred, there was no evidence of

papilloedema. The unaided visual acuity was 6/18 right, and 6/36 left.

Skeletal and general examination revealed no other abnormalities. Wassermann reaction negative.

In the X-ray of the skull the sutures appeared closed. Deep and numerous convoluted markings were present. The floor of the middle and anterior fossae was shortened. There was not much alteration to the sella turcica. These are the features of a cranio-stenosis of the oxycephalic variety.

COMMENT

No satisfactory explanation has been given to account for the malformation. Crouzon considered the condition to be hereditary and familial disease of a teratological kind and suggested that craniectomy might be a remedy for the deformity.

A cerebral decompression, with perhaps an orbital decompression by removal of the roof of the orbit, may be indicated if visual symptoms develop rapidly in the first years of life, but the deformity rapidly stabilizes and many patients have attained old age.³

In this case no treatment was indicated.

SUMMARY

A case is reported of Crouzon's disease in the Bantu, without evidence of heredity.

I should like to thank the Superintendent of St. John's Ophthalmic Hospital for his permission to publish this case, and also the X-ray Department of Baragwanath Hospital and the photographic section of the Witwatersrand University Medical Department.

REFERENCES

1. Crouzon (1912): Bull. Soc. méd. Hôp. Paris, 33, 545.
2. Atkinson (1937): Med. Press, 195, 118.
3. Duke-Elder, S. (1952): *Text-Book of Ophthalmology*, vol. V. 4,740. London: Henry Kimpton.