
Progress in Paediatric Gastro-enterology

S. CYWES, M.MED. (SURG.), *Associate Professor of Surgery, Department of Paediatric Surgery, University of Cape Town and Principal Paediatric Surgeon, Red Cross War Memorial Children's Hospital, Cape Town*

SUMMARY

Some of the greatest advances in paediatric surgery have been in the field of paediatric gastro-enterology. Progress in some of these conditions is discussed.

S. Afr. Med. J., **45**, 1134 (1971).

During the last few years progress in various aspects of paediatric surgery has been phenomenal, due mainly to the acceptance of paediatric surgery as a separate specialty, and because more and more surgeons are confining themselves to the surgical problems of infants and children. This has led to a better understanding of the aetiology,

embryological development and pathophysiological processes of many anomalies and diseases, as well as advances in the pre-, intra- and postoperative management of these patients. Perhaps some of the greatest advances have been in paediatric gastro-enterology, as a tremendous amount of research has been carried out in this field.

EXOMPHALOS AND GASTROSCHISIS

We have learnt to differentiate between these two distinct entities (see Fig. 1). In gastroschisis the defect is alongside the umbilicus, usually to the right, and there

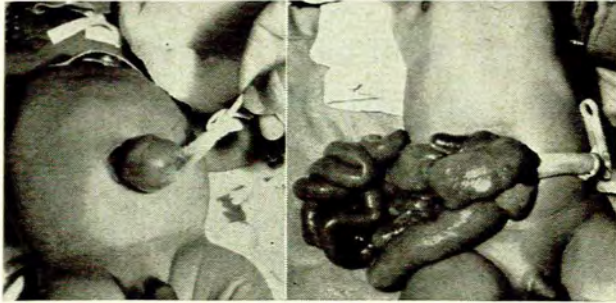


Fig. 1. Left: Exomphalos. Right: Gastroschisis. Note defect lateral and to the right of umbilicus.

is no covering sac as is found in an exomphalos. The mortality rate in gastroschisis and in ruptured exomphalos has been significantly reduced by the use of Silastic sheeting reinforced with dacron, which is used to cover the defect and the protruded intestine (Figs. 2(a) and 2(b) and 3).

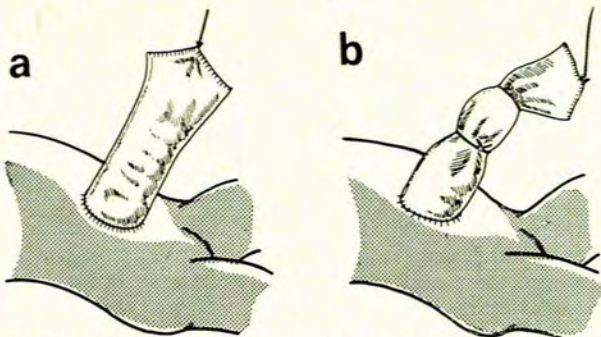


Fig. 2(a). Reinforced Silastic sheet sutured to abdominal wall. Fig. 2(b). Silastic sac reduced by silk ties.

With daily reduction the intestine can be returned to the abdominal cavity within 7-10 days when a formal repair can be effected.¹ The unruptured exomphalos is treated mainly by conservative means unless the sac is ruptured or the defect is small (under 2 cm) in diameter, producing obstructive symptoms.

The recognition and prompt treatment of hypoglycaemia in these cases have been lifesaving in many instances. A special syndrome of babies born with an exomphalos and a large tongue with episodes of hypoglycaemia has also been recognized of late (Fig. 4).

OESOPHAGEAL ATRESIA

The introduction of the Replogle tube has improved the pre-operative management of these babies. We can now afford to treat an associated pneumonia for 24 hours or

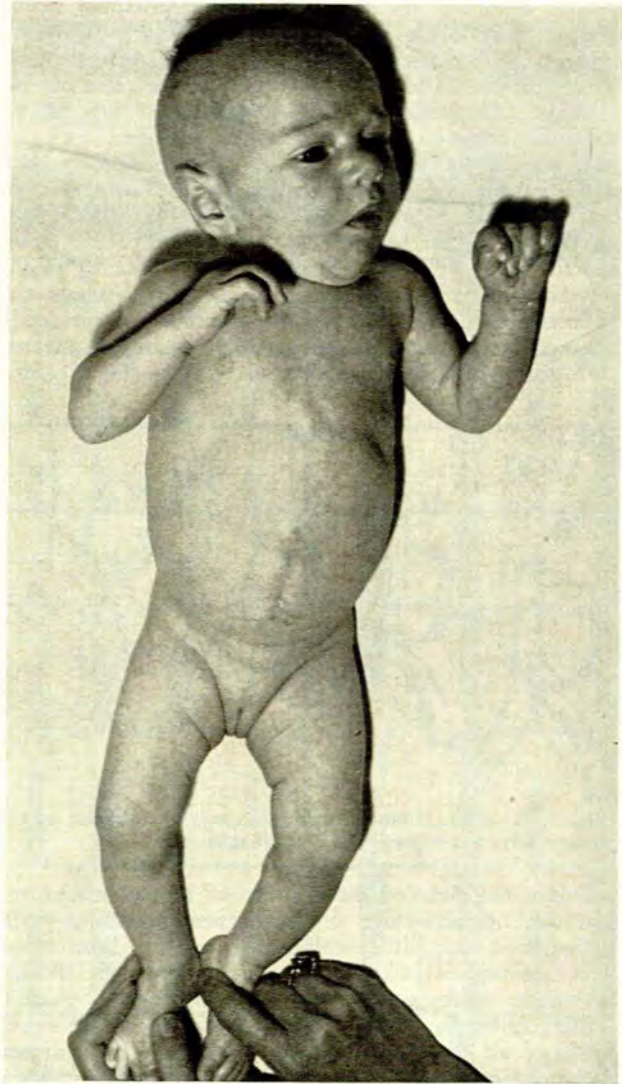


Fig. 3. Four-week-old infant 3 weeks after removal of Silastic sac and complete repair of abdominal wall defect.

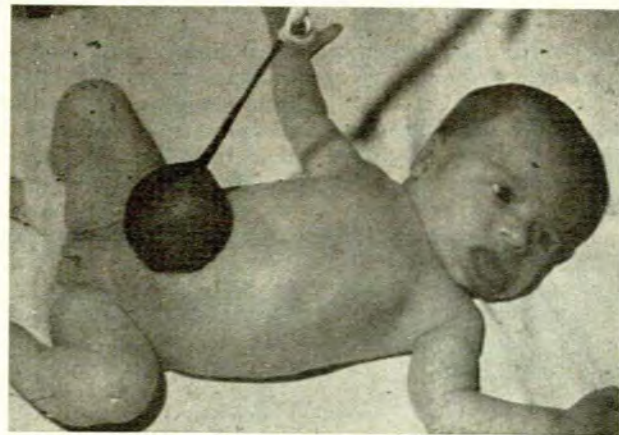


Fig. 4. Baby with exomphalos and large tongue.

so with adequate decompression of the proximal pouch before performing definitive repair. The surgery of this lesion in all its aspects has changed over the past few years, which has resulted in a marked decrease in the mortality and morbidity of these babies, as well as improved the function of the repaired oesophagus.

An extrapleural approach has made this operation safe as far as the postoperative progress and postoperative anastomotic leaks are concerned. The actual repair has been modified and we are now performing a procedure used for years on the Continent but only recently popularized by Beardmore from Montreal.² In essence the fistula is ligated in continuity, the proximal oesophagus is anchored to the distal oesophagus and the repair effected end-to-side with a few 3-0 black silk sutures (Fig. 5). This

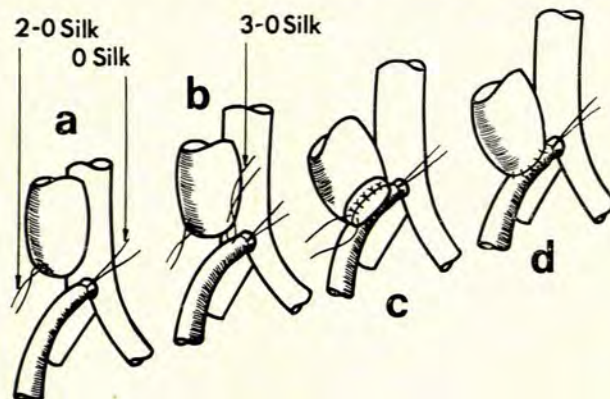


Fig. 5. (a - d). Ligation of tracheo-oesophageal fistula and end-to-side anastomosis of oesophagus.

procedure has reduced the number of staged procedures as it can be performed on premature infants as well. Furthermore, very little mobilization of the distal oesophagus is required with no interference with the slender vagal fibres or the tiny vessels supplying the oesophagus, resulting in hardly any inco-ordination of the oesophageal peristalsis on follow-up, as was previously encountered following a conventional end-to-end anastomosis. Similarly the well known oesophageal atresia cough is no longer heard.

Lastly, the management of patients presenting with an oesophageal atresia with no oesophagotracheal fistula has also improved. Invariably in these cases there is a long gap between the two blind ends, making a primary repair impossible. Previously the proximal pouch was exteriorized in the neck and a feeding gastrostomy was performed. At a later stage reconstruction was carried out using a segment of colon. Today we only perform the gastrostomy for feeding and leave the Replogle tube in the upper pouch. During the ensuing few months the proximal pouch (and distal oesophagus if necessary) are elongated with a mercury bougie. This is continued until the two ends of oesophagus overlap when an end-to-end repair can be effected (Fig. 6).

DUODENAL ATRESIA AND STENOSIS

The management of duodenal atresia is now well established. The use of a transanastomotic Silastic feeding tube

through a gastrostomy tube has been universally adopted and has hastened the postoperative course considerably.

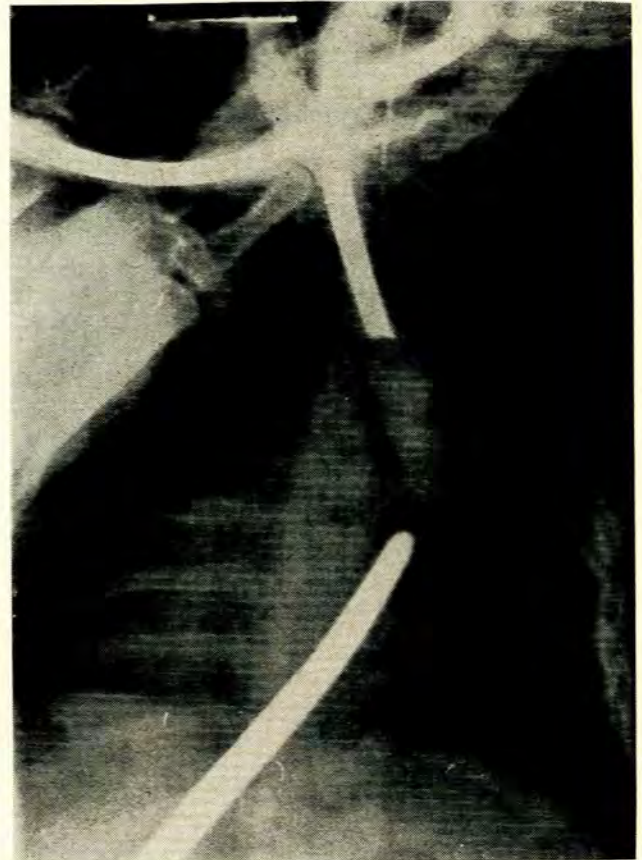


Fig. 6. Elongation of upper oesophageal pouch with a mercury bougie. Metal dilator in distal oesophagus introduced via gastrostomy.

SMALL BOWEL OBSTRUCTIONS

The aetiology and management of babies with small bowel atresias and stenoses is now standard and adopted by most.³ However, the method of research which culminated in the elucidation of the aetiology of this condition has opened the way for several other research projects. Foetal experimental surgery is performed in many laboratories in attempts to produce other anomalies, e.g. biliary atresias, Hirschsprung's disease and anorectal malformations.^{4,5}

Progress has been made in the management of babies following massive bowel resection whether as a result of multiple atresias or a volvulus. In the medical management of these babies intravenous hyperalimentation has proved itself as a most valuable aid.⁶ Concentrated feeds with high calorie content can be given by this method for weeks or months, thereby maintaining a positive nitrogen balance and actual gain in weight. This method of treatment has enabled us to persist with medical treatment without having to resort to the various surgical procedures in an attempt to delay transit time, e.g. reversal of short segments of bowel.⁷ The value of parenteral hyperalimentation was beautifully shown in one of our cases. A newborn baby weighing 1.8 kg had had a massive resection of small

bowel for multiple atretic segments, leaving him with 17 cm of small bowel. The postoperative course was uncomplicated, but soon he developed intestinal hurry and massive loss of fluids. Mouth to anus transit time was 3-4 minutes. With hyperalimentation and intravenous supplementation we were able to manage him for 9 months with a steady gain in weight, before he was able to maintain himself on oral diet alone. He is now 18 months and weighs 7.7 kg. The mouth to anus time is now 5-6 hours. Although he still has some malabsorption he does not require supplementation for excessive fluid loss.

Thus, with energetic medical management and intravenous hyperalimentation we were able to tide this baby over until the compensatory mechanisms in the remaining small bowel and large bowel could correct the massive fluid loss.

The recognition, prevention and treatment of magnesium deficiency in infants in whom the physiology of the gastrointestinal tract has been altered after surgical procedures such as resection, short circuits and fistulae are major advances. The period of risk is between 1 and 3 months of age, before the onset of mixed feeding, as the magnesium content of cow's and breast milk is relatively lower than in meat and vegetables.⁸

The over-all management of babies with mucoviscidosis presenting with meconium ileus in the neonatal period has improved to such an extent that more and more are now surviving. Resection of the obstructed bowel with a Bishop-Koop type of ileostomy and washouts of the distal bowel with gastrografin or acetylcysteine have materially improved results. Long-term antibiotic administration, regular humidification with saline, Bisolvlin and pancreatic supplementation have enabled these children to grow up relatively free from complications.

HIRSCHSPRUNG'S DISEASE

Since Hirschsprung's first description of this disease we have come a long way in the understanding and management of the condition. The clinical features, pathology and various types of definitive procedures are well known today, but the greatest progress has been in the work done to elucidate the aetiology and pathophysiology of congenital megacolon. Following some embryological studies of Okamoto and Ueda,⁹ the aetiology of aganglionosis is believed to be a developmental anomaly in which the transcaudal migration of neuroblasts into the alimentary tract has ceased at various stages before the twelfth week of gestation. The rectosigmoid, the most distal part for the neuroblasts to travel to, is the most common site of involvement, but the earlier the cessation of migration, the longer the segment of aganglionosis.

Further interesting work has been done by Ehrenpreis and his group¹⁰ in the pathophysiology of this condition. By histochemical fluorescent studies they showed that the mediation not only of parasympathetic, but also sympathetic influences to the aganglionic bowel is interrupted (Fig. 7). This functional denervation promotes spastic contraction, which is the main characteristic of the distal aganglionic segment of bowel in Hirschsprung's disease.

Recently Lawson and Nixon¹¹ and Tobon *et al.*¹² have shown that manometric studies of the anal canal and

rectum can be used in the diagnosis of Hirschsprung's disease. In normal subjects distension of the rectum produces relaxation of the internal sphincter and contraction of the external sphincter, whereas in patients with Hirschsprung's disease there is contraction of the internal sphincter.

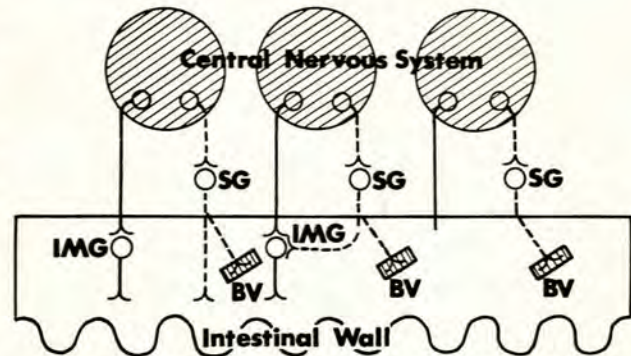


Fig. 7. Autonomic innervation of intestine. Left: The classical concept of two separate systems. Centre: Modified concept according to recent histochemical findings. Right: Aganglionic segment of bowel in Hirschsprung's disease. Absence of intramural ganglion cells and synaptic networks. Innervation of blood vessels unaffected. IMG = intramural ganglion. SG = sympathetic ganglion. BV = blood vessel. (Ehrenpreis).¹⁰

ANORECTAL MALFORMATIONS

In this field progress has been made in all aspects. Firstly, unanimity on a classification of anorectal malformations was obtained in March 1970 in Melbourne by an international panel of paediatric surgeons.¹³ Secondly, pre-operative radiological investigation of these babies has been shown to be of great value in making a complete diagnosis and in siting the lesion, which has enabled us to perform the correct procedure.¹⁴ Thirdly, the now accepted method of treatment, viz. by a definitive sacro-abdomino-perineal pull-through operation, the long-term results and continence have undoubtedly been improved, as has been shown in our series of cases.¹⁵

Lastly, we are now able to assess continence not only on strict clinical criteria, but also more objectively by means of rectograms,¹⁶ performed by our radiological department. To complete this assessment another objective aid should be added, viz. manometric studies, which we hope to complete this year.

I have discussed the progress in some conditions in paediatric gastro-enterology. There is still a great deal to be learnt. Further improvement in management and long-term results in gastro-intestinal pathology in infants and children can only be obtained by a better understanding of normal development, and physiological as well as the pathophysiological processes.

REFERENCES

1. Allen, R. G. and Wrenn, E. jnr (1969): *J. Pediat. Surg.*, **4**, 3.
2. Ty, T. C., Brunet, C. and Beardmore, H. E. (1967): *Ibid.*, **2**, 118.
3. Louw, J. H. (1966): *Ibid.*, **1**, 8.
4. Pickett, L. K. and Briggs, H. C. (1969): *Ibid.*, **4**, 95.
5. Rosenkrantz, J. G., Lynch, F. P. and Frost, W. W. (1970): *Ibid.*, **5**, 232.
6. Dudrick, S. J., Wilmore, D. W., Vars, H. M. and Rhoads, J. E. (1968): *Surgery*, **64**, 134.
7. Cywes, S. (1968): *J. Pediat. Surg.*, **3**, 740.

8. Atwell, J. D. (1966): *Ibid.*, **1**, 427.
9. Okamoto, E. and Ueda, T. (1967): *Ibid.*, **2**, 437.
10. Ehrenpreis, Th., Norberg, K-A and Wirsén, C. (1968): *Ibid.*, **3**, 43.
11. Lawson, J. O. N. and Nixon, H. H. (1967): *Ibid.*, **2**, 544.
12. Tobon, F., Reid, N. C. R. W., Talbert, J. L. and Schuster, M. M. (1968): *New Engl. J. Med.*, **278**, 188.
13. Santulli, T. V., Kiesewetter, W. B. and Bill, A. H. (1970): *J. Pediat. Surg.*, **5**, 281.
14. Cremin, B. J. (1971): *Clin. Radiol.*, **12**, 239.
15. Louw, J. H., Cywes, S. and Cremin, B. J. (1971): *S. Afr. J. Surg.*, **9**, 21.
16. Cywes, S., Louw, J. H., and Cremin, B. J. (1971): *Ibid.*, **9**, 31.