

Therapy of Vesico-Ureteral Reflux in Children*

R. HOHENFELLNER, *Urologische Universitätsklinik, Mainz, Germany*

SUMMARY

The operation after Lich-Gregoir is a technically simple and successful method for the treatment of primary vesico-ureteral reflux. The operation is performed extravesically without opening of the bladder and without splinting the ureter. The stay in the hospital is short.

S. Afr. Med. J., **45**, 1063 (1971).

There is no doubt about the correlation between primary vesico-ureteral reflux and recurring urinary infection. The radiographic and cystoscopic findings—cranial and lateral displaced golf-hole orifices—are evident.

'Maturation' of the ureteral orifice—mainly during the first 2 years of life and sometimes later, can lead to spontaneous recovery. Accordingly, there are fewer adults with chronic urinary infection and recurring vesico-ureteral reflux than children. The precise percentage, however, is

not known: while reflux studies in children are undertaken as routine examinations, these investigations are rather infrequent among adults.

Also unknown is the percentage of adults with chronic pyelonephritis due to primary vesico-ureteral reflux in childhood which cannot later be detected.

Therefore there are hardly any doubts about the indication for timeous anti-reflux surgery in children with primary vesico-ureteral reflux and recurring persistent urinary infection, as long as there is a simple surgical technique.

METHOD

In 103 children, in whom antibiotic therapy had failed and urinary infection and vesico-ureteral reflux persisted, the Lich-Gregoir operation was performed. Cases with mega-ureter, terminal stenosis, neurogenic bladder or infravesical obstruction are not included in this group.

*Paper presented at the 8th Congress of the Urological Association of South Africa (M.A.S.A.), held in Cape Town on 1-5 February 1971.




Fig. 1

Fig. 2

Fig. 3

Figs. 1-3: Steps in the Lich-Gregoir operation (see text).

The technique of operation is not difficult. The ureter is freed after para-inguinal incision (Fig. 1). The bladder is filled with 80 ml of fluid, the muscularis is vertically split over a length of 3 cm. After this the bluish mucosa balloons out (Fig. 2). The ureter is put into the new bed and the detrusor is closed with interrupted chromic catgut sutures (Fig. 3). A paravesical Redon suction drainage tube remains for 48 hours and a bladder catheter for 4-5 days. The average stay in the clinic is 1 week.

Between 1964 and 1970, 103 children with 115 refluxing ureters were selected. In 86 cases there existed a low-pressure and in 29 cases a high-pressure reflux or a reflux that appeared at voiding. These children had previously been treated unsuccessfully with antibiotics over a long period and were sent to us for surgery. Antibiotic treatment was repeated for 3-6 months, but only 7 showed spontaneous recovery. A total of 96 children underwent operation, 80 girls and 16 boys, 14 with bilateral and 4 with ureter duplex.

In cases with ureter duplex and vesico-ureteral reflux into both parts, but usually into the lower part of the kidney, the same procedure was followed. The ureters were not separated, but were put together into the new bed.

Fig. 4 shows (left to right) the pre-operative IVP, the low-pressure reflux into the lower part of the kidney, and

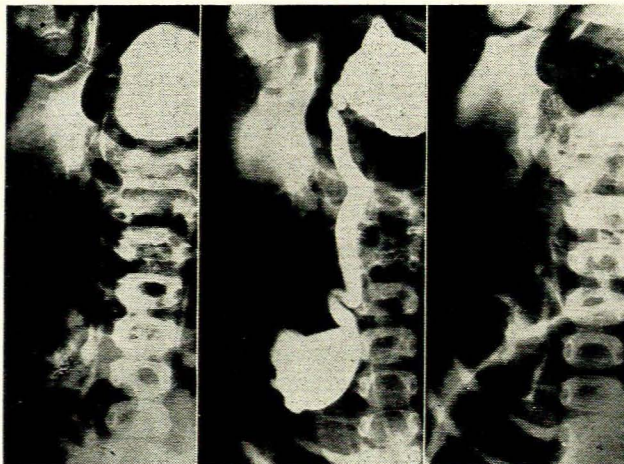


Fig. 4 Left: Pre-operative IVP. Centre: Low-pressure reflux into the lower part of the kidney. Right: The IVP after operation.

the IVP after operation. Fig. 5 shows the reflux control of the same patient 1 year after surgery.

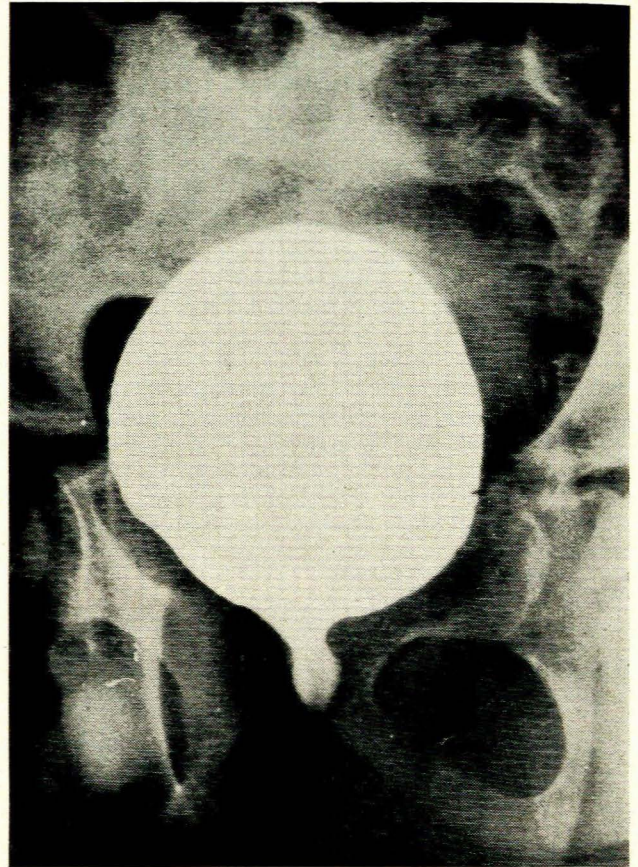


Fig. 5. The reflux control of the patient shown in Fig. 4, one year after operation.

COMPLICATIONS

In 110 operations, 5 patients (4.5%) developed complications. In 2 cases (1.8%) a paravesical haematoma occurred, which was emptied through a small incision without any further complications. Since then we have been using suction drainage and this complication no longer arises. In 2 cases (1.8%) the reflux persisted. One child (0.9%) subsequently developed ureter stenosis and therefore a secondary Politano-Leadbetter operation was performed.

RESULTS

Ninety-six patients underwent the operation. Normal urograms, absence of reflux and no infection were found in 87.5% after 3 months, in another 7.2% after 6 months, and in 3.1% after a secondary operation, a total of 97.8%.

BIBLIOGRAPHY

- Ambrose, S. S. (1969): *J. Urol.*, **102**, 302.
 Baker, R., Maxted, W., Maylath, J. and Shuman, I. (1966): *Ibid.*, **95**, 27.
 Gregoir, W. and von Regemorter, G. (1964): *Urol. int. (Basel)*, **18**, 122.
 Lich, R. jr, Howerton, L. W. jr, Goode, L. S. and Davis, L. A. (1964): *J. Urol.*, **92**, 436.
 Tanagho, E. A. and Hutch, J. A. (1965): *Ibid.*, **93**, 158.