

Karyotype 46,XX in a Black Male

N. F. LYONS

SUMMARY

A clinical and cytogenetic report is made of a Black male child with the karyotype 46,XX. Although 46,XX males have already been reported, this is the first time this anomaly has presented in a Black.

S. Afr. Med. J., 48, 1847 (1974).

In the late 1950s it was accepted that the normal male phenotype is associated with a 46,XY karyotype. Chapel'e *et al.*¹ reported a male with a 46,XX karyotype and since then a number of cases have been recorded.²⁻⁷ This report presents a case of a Black male child with the karyotype 46,XX.

CASE REPORT

The patient, a 13-month-old Black male of the Lomwe tribe from Malawi, was referred for investigation of congenital malformation of the genital organs. A hypospadiac penis was present with the urethral opening at the base of the phallus. Partly undescended testes were palpable in the inguinal canal and could be brought down into the scrotum by gentle traction (Fig. 1).

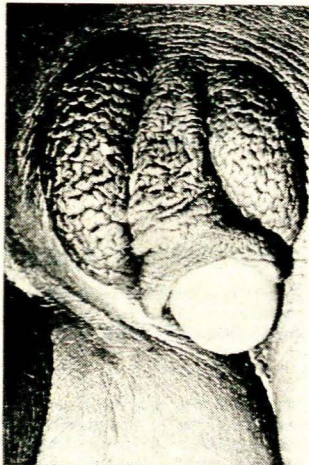


Fig. 1. Detail of external genitalia of the patient.

No uterus or ovaries were seen at laparotomy. A small biopsy specimen was taken from each gonad and showed normal immature testicular tissue in each case (Fig. 2). The child appeared alert and unretarded.

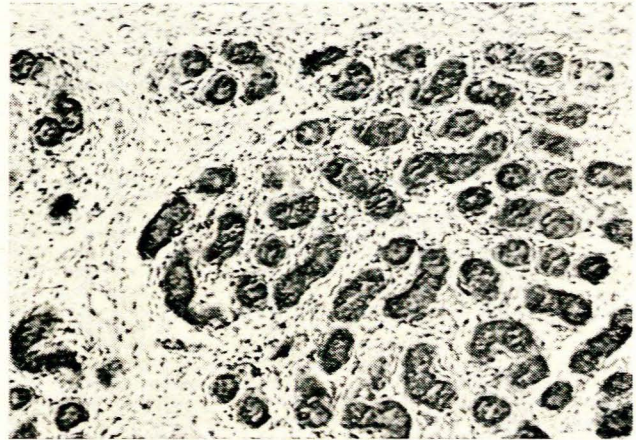


Fig. 2. Histological appearance of the testicular biopsy.

Cytogenetic Studies

Chromosome analysis was performed on phytohaemagglutinin-stimulated lymphocyte cultures obtained from peripheral blood. Suitable metaphase spreads were stained with buffered Giemsa, and for fluorescent studies by the method of Caspersson *et al.*⁸ A total of 50 cells were karyotyped from the first culture, and the same number from a repeat culture. A modal number of 46,XX chromosomes was found in each case.

Buccal smears were stained for Barr bodies by the method of Klinger and Ludwig,⁹ and for Y-body fluorescence by the method of Kim *et al.*¹⁰ Single Barr bodies were seen in 35% of cells examined, but Y-body fluorescence was not present. The patient was removed by his father before tissue for skin fibroblast cultures was obtained.

DISCUSSION

A number of cases have been reported suggesting that the Y chromosome is unnecessary for the development of testicular tissue. In the majority of reports of 46,XX males some clinical features of Klinefelter's syndrome were noted.

The hypospadiac penis reported here appears to favour a diagnosis of true hermaphroditism, and was not found in other recorded cases of 46,XX males. In these cases a normal, although small, penis was usually present.

Department of Pathology, University of Rhodesia, Salisbury, Rhodesia

N. F. LYONS

Date received: 17 April 1974.

Shah *et al.*¹¹ recorded a male pseudohermaphrodite, karyotype 46,XX, with ambiguous external genitalia, an enlarged phallus and a vagina with a separate opening from that of the urethra. No uterus or ovarian tissue was noted. The present case lacked the rudimentary vagina which is commonly found in pseudohermaphrodites. In addition, the absence of ovarian tissue discounts true hermaphroditism.

The possibility that the male determining loci may be on the short arm of the Y chromosome,^{12,13} leaves room for speculation that a translocation of a deleted and hence non-fluorescent Y chromosome could account for this phenomenon. Kasdan *et al.*⁶ showed evidence of an autosomal inheritance of a male-determining gene in a family with several male members having a 46,XX karyotype.

I wish to thank Dr E. Forbes for referring the patient.

REFERENCES

1. Chapelle, A., De La Hortling, H., Niemi, M. and Wennstrom, J. (1964): *Acta med. scand.*, suppl. 412, pp. 25 - 38.
2. Andersson, L., Bergman, S., Reitalu, J. and Ansehn, S. (1972): *Hereditas (Lund)*, **70**, 311.
3. Powers, H. O., Neu, R. L. and Smulyan, H. (1970): *J. Clin. Endocr.*, **31**, 576.
4. Nicolis, G. L., Hsu, L. Y. and Sabetghadam, R. (1972): *Amer. J. Med.*, **52**, 482.
5. Sutherland, G. R., Wiener, S. and Bartholomew, A. A. (1972): *Ann. Génét.*, **15**, 187.
6. Kasdan, R., Nankin, H. R., Troen, P., Wald, N., Pan, S. and Yanaihara, T. (1973): *New Engl. J. Med.*, **288**, 539.
7. Boczkowski, K., Janczewski, Z. and Philip, J. (1969): *Hereditas (Lund)*, **62**, 285.
8. Caspersson, T., Lomakka, G. and Zech, L. (1971): *Ibid.*, **67**, 89.
9. Klinger, H. P. and Ludwig, K. S. (1957): *Stain Technol.*, **32**, 235.
10. Kim, My. A., Bier, L., Majewski, F. and Pfeiffer, R. A. (1971): *Humangenetik*, **12**, 257.
11. Shah, P. N., Naik, S. N., Mahajan, D. K., Dave, M. J. and Paymaster, J. C. (1961): *Brit. Med. J.*, **2**, 474.
12. Ferguson-Smith, M. A. (1970): *Bull. Eur. Soc. Hum. Genet.*, **4**, 39.
13. Jacobs, P. A. and Ross, A. (1966): *Nature (Lond.)*, **210**, 352.